

## REVIEW ARTICLE

# Oral manifestations of eating disorders: a critical review

L Lo Russo<sup>1</sup>, G Campisi<sup>1</sup>, O Di Fede<sup>1</sup>, C Di Liberto<sup>1</sup>, V Panzarella<sup>1</sup>, L Lo Muzio<sup>2</sup>

<sup>1</sup>Oral Medicine Section, Department of Oral Sciences, Faculty of Medicine, School of Dentistry, University of Palermo, Palermo, Italy; <sup>2</sup>Department of Surgical Sciences, Faculty of Medicine, School of Dentistry, University of Foggia, Foggia, Italy

**BACKGROUND:** Eating disorders (ED) are a group of psychopathological disorders affecting patient relationship with food and her/his own body, which manifests through distorted or chaotic eating behavior; they include anorexia nervosa, bulimia nervosa and ED not otherwise specified and may be burdened with life-threatening complications. As oral manifestations of ED can occur in many phases of disease progression, they play a significant role in assessment, characterization and prognosis of ED.

**METHODS:** Mucosal, dental, and salivary abnormalities associated with ED have been reviewed. Relations between oral manifestations and pathogenesis, management and prognosis of ED have been critically analysed.

**RESULTS:** Oral manifestations of ED include a number of signs and symptoms involving oral mucosa, teeth, periodontium, salivary glands and perioral tissues; differences exist between patients with anorexia and bulimia. Oral manifestations of ED are caused by a number of factors including nutritional deficiencies and consequent metabolic impairment, poor personal hygiene, drugs, modified nutritional habits and underlying psychological disturbances.

**CONCLUSION:** Oral manifestations of ED can cause impairment of oral function, oral discomfort and pain, and an overall deterioration of aesthetics and quality of life. Their treatment can contribute to overall patient management and prognosis.

*Oral Diseases* (2008) 14, 479–484

**Keywords:** eating disorders; oral manifestations; anorexia; bulimia; management

## Introduction

In the second half of the 20th century, incidence of eating disorders (ED) progressively increased (Emans,

2000). This group of diseases, according to the 'Diagnostic and Statistic Manual for mental disorders, IV edition' (American Psychiatric Association), includes anorexia nervosa (AN; Yager and Andersen, 2005), bulimia nervosa (Mehler, 2003), and ED not otherwise specified; thus, in this paper the acronym ED will be used to indicate the whole group. Because of our limited understanding of their pathogenesis, prevention and management of these disorders still remain a challenge (Becker *et al*, 1999; Kaye *et al*, 2000a). Current knowledge suggests that the characterizing food-related problem is an outlet to express psychic suffering and disturbances of various types and entity; however, complications associated with the distorted eating behavior can actually lead to metabolic, morphological and functional alterations of multiple organs and systems, exhibiting varying degrees of morbidity and sometimes resulting in life-threatening outcomes. Several oral manifestations of ED have been reported and they include a number of signs and symptoms involving oral mucosa, teeth, periodontium, salivary glands and perioral tissues, often appearing very early in disease onset and enabling early detection. Furthermore, oral manifestations can interfere with pathogenetic factors of ED, thus influencing disease behavior and management.

The aim of this study was to review the potential oral manifestations of ED and highlight their role in disease assessment and comprehensive management.

## Definition and pathogenesis of eating disorders

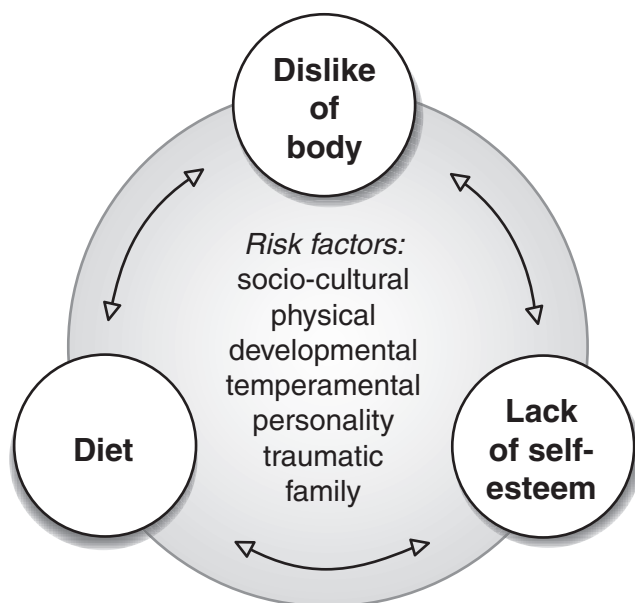
Eating disorders are a group of psychopathological disorders affecting patient relationship with food and her/his own body, which manifests through distorted or chaotic eating behavior. Patients suffering from ED have different behavioral profiles in relation to food and diet. In particular, anorexic patients feel the obsessive need to decrease their body weight, so they tend to achieve weight control mainly by food abstention, which can be sometimes associated with intensive physical activity. On the other hand, the bulimic patient strongly fears putting on weight, but initially has occasional episodes of binge eating, which represents a form of

Correspondence: Dr Lucio Lo Russo, Via Serro D'Annunzio, 55, 83050 Vallesaccarda (AV), Italy. Tel: +39 347 8412304, Fax: +39 0827 976026, E-mail: [lorusso.lucio@tiscali.it](mailto:lorusso.lucio@tiscali.it)

Received 21 June 2007; revised 27 July 2007, 26 August 2007; accepted 07 September 2007

expression of anxiety, depression and/or loneliness; the perceived loss of control over food intake strengthens this fear, so patient eliminates the food that has just been eaten by self-induced vomiting (Becker *et al*, 1999; Kaye *et al*, 2000b) or by means of drugs such as laxatives. The former behavior is described as a 'restricting type' (Rt), while the latter as a 'purging type' (Pt); they are neither completely antithetic, nor mutually exclusive (Ngai *et al*, 2000), and they can lead, even if through different mechanisms, to severe or life-threatening damage.

The feeling of dissatisfaction with one's body, a key point in disease pathogenesis, may present several risk factors (Kaye *et al*, 2000a; Bulik *et al*, 2006; Kugu *et al*, 2006; Lo Muzio *et al*, 2007) including environmental (e.g. socio-cultural pressure towards slimness), genetic (Kaye *et al*, 2000b; Matsushita *et al*, 2004), physical (Gorwood *et al*, 1998; e.g. a genetic tendency to overweight) or developmental factors (e.g. puberty, first sexual relations; Favaro *et al*, 2006), and might be triggered/aggravated by other variables such as temperamental and personality traits (e.g. dependency on others' approval; Matsunaga *et al*, 2000), traumatic factors (e.g. physical and sexual abuse, serious negligence suffered during childhood; Carter *et al*, 2006), and family situations (e.g. enmeshment). Altogether, these factors can lead to difficulties in self-regulation, poor self-esteem and insecure attachment. In this scenario, diet becomes the instrument through which the attempt to control and manipulate one's body image may repair the weakness and the conflict in one's self-esteem. Thus, a paradigm in which a double relation links diet, mental image of the body, and self-esteem may explain the onset of the complex disorders affecting eating (Figure 1) and provide a useful tool in therapeutic approach.



**Figure 1** Etiopathogenetic paradigm of eating disorders

## Oral manifestations of eating disorders

Oral manifestations occurring in ED are mainly caused by nutritional deficiencies and consequent metabolic impairment, but may also be related to lack of importance given to personal hygiene/care, underlying psychological disturbances, modified nutritional habits (tendency to eat particular foods) or assumption of certain drugs. Such a wide group of clinical conditions are detailed in Table 1; they include signs (Mueller, 2001; Gurenlian, 2002; Little, 2002) and symptoms (Spigset, 1991) involving the whole mouth (i.e. oral mucosa, teeth, periodontium), salivary glands (Anders *et al*, 1975; Coleman *et al*, 1998), as well as perioral tissues (xerosis, lanugo; Mayerhausen *et al*, 1990; Strumia *et al*, 2001), and sometimes exhibit different features in relation to patients' behavioral models above discussed.

### Mucosal lesions

Reduction in intake of vitamins and other nutrients, as well as general metabolic alterations and iron deficiency anemia, may sensibly affect oral mucosa biology ending up with generalized mucosal atrophy. In particular, a deficiency of vitamins in the B group, especially B1, B6 and B12, has been classically associated with a decrease in epithelial cell turnover. Generally, this is particularly evident on the tongue; here, in association with erythema, it produces the clinical picture of atrophic glossitis. Mucosal atrophy may also cause diffuse oral burning sensation, which can be more intense on the tongue (glossodynia).

Erythematous mucosal lesions, especially on the soft palate in purging type behavior, may be related to the direct offending action of acid during vomiting (epithelial erosion), and sometimes to repetitive frictional trauma caused by the object used to induce vomiting (Mueller, 2001).

### Periodontal manifestations

Eating disorders have a peak of incidence in children and young adults, when the occurrence of advanced periodontal disease is uncommon. Nevertheless, patients affected by ED may have poor oral hygiene, which may lead to gingival inflammation and potentially predisposition to periodontitis. Adequate oral care habits are impeded by binge eating and purging episodes and, in addition, they are more unlikely to be observed in patients prone to depression; Rt patients usually pay greater attention to their body, including the mouth and oral care.

Nutritional deficiencies (Prousky, 2003), especially in vitamin C (Christopher *et al*, 2002), may also affect marginal periodontium predisposing to gingivitis. In particular, deficiency of vitamin C, known as scurvy, causes defective collagen synthesis, which can be associated with generalized gingival swelling, spontaneous gingival bleeding, ulcerations, tooth mobility and increased severity of periodontal infection (Touyz, 1997). Such manifestations may be associated with various degrees of oral discomfort including pain.

**Table 1** Oral manifestations of eating disorders

<i>Oral manifestations</i>	<i>Main causes</i>	<i>Restricting type (Rt)</i>	<i>Purging type (Pt)</i>
Mucosal lesions	Mucosal atrophy	Vitamins deficiency	+
	Glossitis (erythema and atrophy)	Multiple nutritional deficiencies	+
	Erythematous lesions (soft palate)	Vomiting	+
Dental lesions	Dental erosions	Carbonated drinks (Rt)	+
		Vomiting (Pt)	+
	Caries	Sweets (Rt)	+
Periodontal lesions	Gingivitis	Poor oral hygiene (Pt)	+
		Vitamin C deficiency (Rt)	+
		Poor oral hygiene (Pt)	+
Salivary manifestations	Periodontitis	Poor oral hygiene	+
	Salivary glands tumefaction (parotid, submandibular, minor salivary glands)	Sialoadenosis	+
	Hyposalivation	Drugs	±
Oral symptoms		Functional unbalance	±
	Necrotizing sialometaplasia		+
	Oral burning sensation	Somatoform disturbances	+
		Mucosal atrophy	+
	Glossodynia	Nutritional deficiency	+
		Somatoform disturbances	+
	Xerostomia	Drugs	+
		Somatoform disturbances	±
	Dysgeusia	Somatoform disturbances	±
	Dental sensitivity	Erosion-caries	+
	Episodes of oral pain	Caries	+
		Periodontal lesions and complications	+

### *Dental manifestations*

Dental erosion in ED patients can be frequently encountered especially on the palatal face of the anterior and posterior teeth; this is also known as perimolysis (Mc Lundie, 1991; Jarvinen *et al*, 1992; Bishop *et al*, 1994; Chadwick and Mitchell, 2001) and may have several causes. In patients with purging behavioral profile, it may be related to vomiting. In addition, it may develop secondary to the frequent use of acidic sports drinks during physical activity (Jarvinen *et al*, 1991), and can increase in severity over time. It may also result from abnormal use of some caffeinated and/or carbonated drinks, either to boost energy levels (O' Sullivan and Curzon, 2000) or to decrease the reflex hunger stimulus (Rytomaa *et al*, 1988; Lussi *et al*, 1995; Edwards *et al*, 1999; Moazzez *et al*, 2000; Al-Dlaigan *et al*, 2001) by increasing dilation of the stomach. Similarly, alcoholic beverages may be used for energy and stimulation but alcohol in general may be a cofactor for purging and, in addition, the acidity of some beverages, wine in particular, can contribute to erosion (Simmons and Thompson, 1987). Some patients will use vinegar and lemon juice (or slices of lemon) to eliminate/diminish the gustatory phase of the mechanism regulating hunger, which can also lead to erosion (Jarvinen *et al*, 1991; Del Signore *et al*, 1998). Such erosion is characterized by a chemical rather than a bacterial dissolution and leads to uniform, polished and spoon-like surfaces, in contrast to abrasion, which is

caused by mechanical wear (Mc Intyre, 1992; Ibarra *et al*, 2001), and which appear sharply cut, flat and angled. Sweetened beverages, sweets or sugared chewing gum are frequently used by ED patients not only for energy, but also to placate the constant feeling of hunger; as a consequence, caries risk is high because of the frequency and quantity of sugars ingested, although oral hygiene is generally satisfactory in anorexic patients. This risk can be further enhanced in patients manifesting an alteration in salivary flow because of either drugs or disordered function.

Dental lesions and their complications may cause oral symptoms ranging from dental sensitivity to episodes of oral pain.

### *Salivary manifestations*

The swelling of the major salivary glands, parotids in particular, is a frequent manifestation of ED and sometimes may be the presenting sign (Coleman *et al*, 1998). It is because of sialadenosis: a non-inflammatory enlargement of the salivary glands caused by a peripheral autonomic neuropathy, which is responsible for disordered metabolism and secretion, resulting in acinar enlargement and functional impairment. Reduction in saliva flow may also be related to side effects of drugs, especially, those used for underlying depressive conditions (Scully and Bagan, 2004).

It is worth noting that sialadenosis may also involve minor intraoral salivary glands (Mignogna *et al*, 2004;

Aframian, 2005); this may be of value in differential diagnosis of salivary enlargement permitting to avoid potentially invasive extra-oral procedures.

Necrotizing sialometaplasia has also been reported in association with bulimia (Solomon *et al*, 2007); it is a self-limiting disorder of uncertain etiopathogenesis, which can mimic invasive carcinoma. Recognition of necrotizing sialometaplasia is essential to avoid misdiagnosis and useless surgical therapy. There are some reports of sialadenitis associated with necrotizing sialometaplasia in patients with ED but the significance of this association remains unclear (Scully and Eveson, 2004).

#### *Other oral manifestations*

Eating disorders may also be associated with a number of oral symptoms: these can be secondary to objective lesions, as above discussed, or constitute medically unexplained symptoms, thus representing the expression of psychological discomfort and/or somatoform disturbances. This may be the case of oral burning sensation, dysgeusia (an altered taste sensation) and xerostomia (sensation of a dry mouth), which can be independent and disconnected from oral signs being of psychogenic origin and expressing somatization of underlying disorders. However, it is worth noting that recent investigations have also highlighted the potential role of some central and peripheral neurological changes in the pathogenesis of such unexplained symptoms (Fedele *et al*, 2007).

In the instance of xerostomia, care should be taken in excluding the presence of salivary hypofunction and intake of drugs inducing it (Scully and Bagan, 2004).

Multiple nutritional deficiencies may also constitute a predisposing factor for oral opportunistic infections both directly (e.g. reduction in iron deposits for mycotic infection; Paillaud *et al*, 2004; Lu and Wu, 2004) and through impairment of immunologic system function (Chandra, 2002).

In patients with AN, osteopenia and subsequently osteoporosis may occur within 6 months of the development of amenorrhea (Golden, 2003; Misra and Klibanski, 2006); this generalized bone loss may carry a number of systemic implications, while it is of little relevance for oral health. However, treatment for osteoporosis might significantly affect oral health. In fact, studies are ongoing (Bruni *et al*, 2006) regarding the use of bisphosphonates in prevention and management of generalized bone loss. Preliminary results suggest that bisphosphonates, at least in adults, are safe and effective in increasing bone mineral density and managing AN-induced early osteoporosis. Nevertheless, the risk for osteonecrosis of the jaws as a potential complication of such drugs has been recently recognized (Bilezikian, 2006).

## **Discussion**

Oral manifestations of ED may appear in different stages along disease progression and, thus, exhibit a number of implications in assessment, characterization

and management of this group of disorders (DeBate *et al*, 2005). In fact, some oral manifestations may occur very early during disease onset (e.g. sialadenitis, palatal erythema, clinical unexplained oral symptoms); therefore, identification/diagnosis can be very useful in early detection and adequate referral for a prompt recovery. This is of great importance as patients affected by ED often try to keep their food-related problems a secret and are reluctant to seek for medical attention. In this scenario, the oral health care provider may be one of the few and the first physicians contacted by the patient in the context of routine recall programs or incipient oral discomfort (i.e. dental sensitivity, oral pain, and unusual oral sensations). Furthermore, as the underlying disorder in ED is psychopathological, approaching individuals suspected to have ED requires proper communication (Burkhart *et al*, 2005) methods to overcome patients' reluctance and refusal. This is mandatory in both the diagnostic and the therapeutic phase. To achieve effective patient-physician communication, the visit should be conducted confidentially/private using appropriate language and terminology: the clinician should avoid judgment and pressure, observe the patients' body language, remain calm, reassuring and supportive.

Some oral lesions may also help in defining the patient behavioral model, especially in Pt where palatal erythema and dental erosions are very suggestive of vomiting induction. Furthermore, oral manifestations can be useful in monitoring treatment efficiency: in fact, compensation for nutritional deficiencies improves oral mucosa conditions; dental erosions stability and palatal mucosa lesions healing may give information on vomiting induction; changes in patients' oral care may indicate variations in her/his care for their body; finally, oral symptoms, which are not clinically related to oral lesions, may be strictly parallel to patients' psychological status.

The role and the value of oral manifestations in comprehensive medical management of ED patients go even further, if we consider that oral manifestations have a number of outcomes capable of activating ED etiopathogenetic mechanisms. In Table 2, the main effects of oral manifestations are summarized: these include oral function impairment, oral discomfort or pain, poor aesthetics and deterioration of quality of life. All of these outcomes may have a negative interference in different parts of the pathogenetic model, which is based on a double relation among three key points (Figure 1): dislike of body, self-esteem and diet. In fact, it seems superfluous to emphasize how all ED-related oral lesions and symptoms affecting oral anatomy and functions may significantly affect diet; in addition, the mouth has a strong impact on interpersonal relationships as it plays a key role also in facial aesthetics; thus, it appears that deteriorating aesthetics related to poor mouth conditions may further alter body perception and/or self-esteem and hence contribute to a very dangerous vicious cycle.

Hence, in the context of comprehensive management of ED, oral manifestations should be reconsidered and

**Table 2** Outcomes of oral manifestations of eating disorders (ED) and their possible interference with key factors of ED etiopathogenetic paradigm

Oral manifestations	Outcomes	Lack of self-esteem	Dislike of body	Diet
Mucosal lesions	Discomfort in oral functions		+	+
Dental lesions	Functional impairment		+	+
	Deterioration of aesthetics	+	+	
Periodontal lesions	Functional impairment		+	+
	Deterioration of aesthetics	+	+	
Salivary manifestations	Functional impairment			+
	Discomfort in oral functions	+	+	+
	Deterioration of aesthetics	+	+	
Oral symptoms	Oral generalized discomfort		+	+
	Poor quality of life	+		

+, possible interference.

attributed greater importance in both diagnosis and follow-up (Mueller, 2001). Furthermore, treatment of these manifestations may be important to the overall prognosis by preventing or reducing damages, which can modify eating habits and function, patient's self-image (Bonilla and Luna, 2001) and consequently self-esteem.

## References

- Aframian DJ (2005). Anorexia/bulimia-related sialadenosis of palatal minor salivary glands. *J Oral Pathol Med* **34**: 383.
- Al-Dlaigan YH, Shaw L, Smith A (2001). Dental erosion in a group of British 14-year-old school children. Part II: Influence of dietary intake. *Br Dent J* **190**: 258–261.
- Anders D, Harms D, Kriens O et al (1975). Sialadenosis as secondary organ manifestation of anorexia nervosa (author's transl). *Klin Padiatr* **187**: 156–162.
- Becker AE, Grinspoon SK, Klibanski A et al (1999). Eating disorders. *N Engl J Med* **340**: 1092–1098.
- Bilezikian JP (2006). Osteonecrosis of the jaw—do bisphosphonates pose a risk? *N Engl J Med* **355**: 2278–2281.
- Bishop K, Briggs P, Kelleher M (1994). The aetiology and management of localized anterior tooth wear in the young adult. *Dent Update* **21**: 153–160.
- Bonilla ED, Luna O (2001). Oral rehabilitation of a bulimic patient: a case report. *Quintessence Int* **32**: 469–475.
- Bruni V, Filicetti MF, Pontello V (2006). Open issues in anorexia nervosa; prevention and therapy of bone loss. *Ann N Y Acad Sci* **1092**: 91–102.
- Bulik CM, Sullivan PF, Tozzi F et al (2006). Prevalence, heritability, and prospective risk factors for anorexia nervosa. *Arch Gen Psychiatry* **63**: 305–312.
- Burkhart N, Roberts M, Alexander M et al (2005). Communicating effectively with patients suspected of having bulimia nervosa. *J Am Dent Assoc* **136**: 1130–1137.
- Carter JC, Bewell C, Blackmore E et al (2006). The impact of childhood sexual abuse in anorexia nervosa. *Child Abuse Negl* **30**: 257–269.
- Chadwick RG, Mitchell HL (2001). Conduct of an algorithm in quantifying simulated palatal surface tooth erosion. *J Oral Rehabil* **28**: 450–456.
- Chandra RK (2002). Nutrition and the immune system from birth to old age. *Eur J Clin Nutr* **56**(Suppl. 3): S73–S76.
- Christopher K, Tammamo D, Wing EJ (2002). Early scurvy complicating anorexia nervosa. *South Med J* **95**: 1065–1066.
- Coleman H, Altini M, Nayler S et al (1998). Sialadenosis: a presenting sign in bulimia. *Head Neck* **20**: 758–762.
- DeBate RD, Tedesco LA, Kerschbaum WE (2005). Knowledge of oral and physical manifestations of anorexia and bulimia nervosa among dentists and dental hygienists. *J Dent Educ* **69**: 346–354.
- Del Signore A, Campisi B, Di Giacomo F (1998). Characterization of balsamic vinegar by multivariate statistical analysis of trace element content. *J AOAC Int* **81**: 1087–1095.
- Edwards M, Creanor SL, Foye RH et al (1999). Buffering capacities of soft drinks: the potential influence on dental erosion. *J Oral Rehabil* **26**: 923–927.
- Emans SJ (2000). Eating disorders in adolescent girls. *Pediatr Int* **42**: 1–7.
- Favaro A, Tenconi E, Santonastaso P (2006). Perinatal factors and the risk of developing anorexia nervosa and bulimia nervosa. *Arch Gen Psychiatry* **63**: 82–88.
- Fedele S, Fricchione G, Porter SR, Mignogna MD (2007). Burning mouth syndrome (stomatodynia) *QJM* Epub ahead of print, doi: 10.1093/qjmed/hcm049.
- Golden NH (2003). Osteopenia and osteoporosis in anorexia nervosa. *Adolesc Med* **14**: 97–108.
- Gorwood P, Bouvard M, Mouren-Simeoni MC et al (1998). Genetics and anorexia nervosa: a review of candidate genes. *Psychiatr Genet* **8**: 1–12.
- Gurenlian JR (2002). Eating disorders. *J Dent Hyg* **76**: 219–234; quiz 236–237.
- Ibarra G, Senna G, Cobb D et al (2001). Restoration of enamel and dentin erosion due to gastroesophageal reflux disease: a case report. *Pract Proced Aesthet Dent* **13**: 297–304.
- Jarvinen VK, Rytomaa II, Heinonen OP (1991). Risk factors in dental erosion. *J Dent Res* **70**: 942–947.
- Jarvinen V, Rytomaa I, Meurman JH (1992). Location of dental erosion in a referred population. *Caries Res* **26**: 391–396.
- Kaye WH, Klump KL, Frank GK et al (2000a). Anorexia and bulimia nervosa. *Annu Rev Med* **51**: 299–313.
- Kaye WH, Lilienfeld LR, Berrettini WH et al (2000b). A search for susceptibility loci for anorexia nervosa: methods and sample description. *Biol Psychiatry* **47**: 794–803.
- Kugu N, Akyuz G, Dogan O et al (2006). The prevalence of eating disorders among university students and the relationship with some individual characteristics. *Aust N Z J Psychiatry* **40**: 129–135.
- Little JW (2002). Eating disorders: dental implications. *Oral Surg Oral Med Oral Pathol Oral Radiol Endod* **93**: 138–143.
- Lo Muzio L, Lo Russo L, Massaccesi C et al (2007). Eating disorders: a threat for women's health. Oral manifestations in a comprehensive overview. *Minerva Stomatol* **56**: 281–292.
- Lu SY, Wu HC (2004). Initial diagnosis of anemia from sore mouth and improved classification of anemias by MCV and RDW in 30 patients. *Oral Surg Oral Med Oral Pathol Oral Radiol Endod* **98**: 679–685.
- Lussi A, Jaeggi T, Jaeggi-Scharer S (1995). Prediction of the erosive potential of some beverages. *Caries Res* **29**: 349–354.

- Matsunaga H, Kaye WH, McConaha C *et al* (2000). Personality disorders among subjects recovered from eating disorders. *Int J Eat Disord* **27**: 353–357.
- Matsushita S, Suzuki K, Murayama M *et al* (2004). Serotonin transporter regulatory region polymorphism is associated with anorexia nervosa. *Am J Med Genet B Neuropsychiatr Genet* **128**: 114–117.
- Mayerhausen W, Vogt HJ, Fichter MM *et al* (1990). Dermatologic aspects of anorexia and bulimia nervosa. *Hautarzt* **41**: 476–484.
- Mc Intyre JM (1992). Erosion. *Aust Prosthodont J* **6**: 17–25.
- Mc Lundie AC (1991). Localised palatal tooth surface loss and its treatment with porcelain laminates. *Restorative Dent* **7**: 43–44.
- Mehler PS (2003). Clinical practice. Bulimia nervosa. *N Engl J Med* **349**: 875–881.
- Mignogna MD, Fedele S, Lo Russo L (2004). Anorexia/bulimia-related sialadenosis of palatal minor salivary glands. *J Oral Pathol Med* **33**: 441–442.
- Misra M, Klibanski A (2006). Anorexia nervosa and osteoporosis. *Rev Endocr Metab Disord* **7**: 91–99.
- Moazzez R, Smith BG, Bartlett DW (2000). Oral pH and drinking habit during ingestion of a carbonated drink in a group of adolescents with dental erosion. *J Dent* **28**: 395–397.
- Mueller JA (2001). Eating disorders: identification and intervention. *J Contemp Dent Pract* **2**: 98.
- Ngai ES, Lee S, Lee AM (2000). The variability of phenomenology in anorexia nervosa. *Acta Psychiatr Scand* **102**: 314–317.
- O' Sullivan EA, Curzon ME (2000). A comparison of acidic dietary factors in children with and without dental erosion. *ASDC J Dent Child* **67**: 186–192.
- Paillaud E, Merlier I, Dupeyron C *et al* (2004). Oral candidiasis and nutritional deficiencies in elderly hospitalised patients. *Br J Nutr* **92**: 861–867.
- Prousky JE (2003). Pellagra may be a rare secondary complication of anorexia nervosa: a systematic review of the literature. *Altern Med Rev* **8**: 180–185.
- Rytomaa I, Meurman JH, Koskinen J *et al* (1988). In vitro erosion of bovine enamel caused by acidic drinks and other foodstuffs. *Scand J Dent Res* **96**: 324–333.
- Scully C, Bagan JV (2004). Adverse drug reactions in the orofacial region. *Crit Rev Oral Biol Med* **15**: 221–239.
- Scully C, Eveson J (2004). Sialosis and necrotising sialometaplasia in bulimia; a case report. *Int J Oral Maxillofac Surg* **33**: 808–810.
- Simmons MS, Thompson DC (1987). Dental erosion secondary to ethanol-induced emesis. *Oral Surg Oral Med Oral Pathol* **64**: 731–733.
- Solomon LW, Merzianu M, Sullivan M *et al* (2007). Necrotizing sialometaplasia associated with bulimia: case report and literature review. *Oral Surg Oral Med Oral Pathol Oral Radiol Endod* **103**: e39–e42.
- Spigset O (1991). Oral symptoms in bulimia nervosa. A survey of 34 cases. *Acta Odontol Scand* **49**: 335–339.
- Strumia R, Varotti E, Manzato E *et al* (2001). Skin signs in anorexia nervosa. *Dermatology* **203**: 314–317.
- Touyz LZ (1997). Oral scurvy and periodontal disease. *J Can Dent Assoc* **63**: 837–845.
- Yager J, Andersen AE (2005). Clinical practice. Anorexia nervosa. *N Engl J Med* **353**: 1481–1488.

Copyright of Oral Diseases is the property of Blackwell Publishing Limited and its content may not be copied or emailed to multiple sites or posted to a listserv without the copyright holder's express written permission. However, users may print, download, or email articles for individual use.