

## ORIGINAL ARTICLE

# Involvement of MT1-MMP and TIMP-2 in human periodontal disease

A Oyarzún<sup>1</sup>, R Arancibia<sup>2</sup>, R Hidalgo<sup>3</sup>, C Peñafiel<sup>3</sup>, M Cáceres<sup>2</sup>, M-J González<sup>4</sup>, J Martínez<sup>5</sup>, PC Smith<sup>2</sup>

<sup>1</sup>Faculty of Odontology, Universidad Finis Terrae; <sup>2</sup>Laboratory of Periodontal Physiology, Dentistry Academic Unit, Faculty of Medicine, Pontificia Universidad Católica de Chile; <sup>3</sup>Faculty of Odontology, Universidad de Chile; <sup>4</sup>Cell Biology Program, Institute of Biomedical Sciences, Faculty of Medicine, Universidad de Chile; <sup>5</sup>Laboratory of Cell Biology, Institute of Nutrition and Food Technology, Universidad de Chile, Santiago, Chile

**OBJECTIVES:** Periodontal disease is characterized by an increased collagen metabolism. Although membrane type-1 matrix metalloproteinase (MT1-MMP) plays a critical role in collagen degradation, its involvement in human periodontitis remains to be determined.

**METHODS:** MT1-MMP and TIMP-2 expression and distribution were evaluated in gingival tissue samples derived from 10 healthy and 12 periodontitis-affected human subjects. MT1-MMP and TIMP-2 expression were assessed through Western-blot of tissue homogenates. The main cell types involved in MT1-MMP and TIMP-2 production were evaluated by means of immunohistochemistry.

**RESULTS:** Both MT1-MMP and TIMP-2 were significantly increased in periodontitis-affected gingival tissues when compared to healthy gingiva. Moreover, the balance between MT1-MMP and its inhibitor TIMP-2 was altered in periodontitis-affected tissues, suggesting an imbalance in this proteolytic axis. Immunohistochemistry demonstrated the expression of MT1-MMP in fibroblasts and macrophages in gingival tissues. MT1-MMP was detected in cells in close association with the gingival collagen matrix. TIMP-2 expression was identified in fibroblasts, macrophages and epithelial cells.

**CONCLUSIONS:** Our observations show an increased expression of MT1-MMP and TIMP-2 in periodontitis-affected gingival tissues. The altered balance between these two molecular mediators of collagen remodeling suggests their involvement in human periodontal disease.

*Oral Diseases* (2010) 16, 388–395

**Keywords:** MMP; MMP-14; MT1-MMP; TIMP-2; periodontal disease

## Introduction

Periodontal disease is an inflammatory disorder initiated by a group of pathogenic bacteria that leads to periodontal tissue destruction and tooth loss (Page *et al*, 1997). Excessive breakdown of the extracellular matrix (ECM) has been associated with several diseases such as cancer, atherosclerosis, osteoarthritis and periodontal disease (Burrage *et al*, 2006; Sorsa *et al*, 2006; Orlichenko and Radisky, 2008; Raffetto and Khalil, 2008). Among the proteolytic enzymes involved in these events, matrix metalloproteinases (MMPs) play a central role in these pathological conditions (Page-McCaw *et al*, 2007). MMPs constitute a family of zinc-dependent endopeptidases comprising 25 members that have been associated with the degradation of almost all the components of the ECM (Page-McCaw *et al*, 2007).

Degradation of type-I collagen is a key step in periodontal attachment loss. Previous studies have identified that gingival collagen fibers are effectively degraded by the action of fibroblasts and mononuclear cells in chronic periodontitis (Ma *et al*, 2003). However, the particular enzymes involved in gingival collagen degradation have not been fully characterized. Type I collagen is effectively degraded by a restricted group of enzymes termed interstitial collagenases that include MMP-1, MMP-8 and MMP-13 (Jeffrey, 1998). Although the membrane-anchored enzyme MT1-MMP is not classified as a member of the collagenases group, it has been demonstrated that this MMP plays a physiologically relevant role in type-I collagen remodeling (Holmbeck *et al*, 1999). Several studies have analyzed the involvement of MMP-1, MMP-8 and MMP-13 in periodontal disease (Wooley and Davies, 1981; Ingman *et al*, 1994; Meikle *et al*, 1994; Haerian *et al*, 1995; Lee *et al*, 1995; Kubota *et al*, 1996; Silva *et al*, 2008). Although previous studies have identified the expression of MT1-MMP in gingival connective tissue cells and gingival crevicular fluid, they have been unable to determine its specific involvement in human periodontitis (Tervahartiala *et al*, 2000; Dahan *et al*, 2001).

Correspondence: Patricio C. Smith, Laboratory of Periodontal Physiology, Dentistry Academic Unit, Faculty of Medicine, Pontificia Universidad Católica de Chile, Marcoleta 391, Santiago, Chile. Tel: +56 2 354 3408, E-mail: psmith@med.puc.cl  
Received 30 July 2009; revised 29 October 2009; accepted 2 November 2009

Moreover, several studies have established that MMPs cleave and regulate the biological activity of a wide range of molecules such as growth factors, cytokines, cell surface receptors and protease inhibitors (Page-McCaw *et al*, 2007). Previous studies have suggested that besides collagen, MT1-MMP may degrade other biological substrates like cytokines, cell surface receptors and growth factors (Tam *et al*, 2004). Therefore, the role played by MMPs in inflammatory diseases may not only involve the catabolic degradation of the ECM, but also the regulation of critical cell functions such as cell proliferation, differentiation and migration (Page-McCaw *et al*, 2007).

MT1-MMP may activate proMMP-2 in the presence of a small amount of Tissue inhibitor of metalloproteinases-2 (TIMP-2). It has been proposed that this may result from the formation of a ternary complex composed of proMMP-2/TIMP-2/MT1-MMP on the cell surface (Strongin *et al*, 1995). However, in the presence of higher TIMP-2 levels, MT1-MMP activity is inhibited. Moreover, a direct binding between TIMP-2 and MT1-MMP has been described (Zucker *et al*, 1998). These data suggests that TIMP-2 may act as a highly specific inhibitor for MT1-MMP.

The aim of the present study was to investigate the expression and distribution of MT1-MMP and of its physiological inhibitor, tissue inhibitor of matrix metalloproteinase-2 (TIMP-2), in gingival tissue samples derived from periodontitis-affected patients and healthy controls.

## Materials and methods

### *Gingival tissue samples*

Gingival tissue samples were collected from 10 healthy subjects and 12 periodontitis-affected individuals from both genders. All gingival tissue samples were obtained with informed consent from patients attending a private dental practice in Santiago, Chile. The experimental protocol for obtaining tissue samples was approved by the Ethical Committee, Faculty of Dentistry, University of Chile. None of these patients had received periodontal treatment during the last 12 months and all gingival biopsies were obtained prior to periodontal therapy. No relevant pre-existing medical or drug histories were cited preceding 6 months. Before obtaining a sample, one examiner (RH), using a University of North Carolina periodontal probe (Hu-Friedy, Chicago, IL, USA), did a complete periodontal examination in every tooth (six sites per tooth) measuring probing depth, attachment loss and bleeding on probing. As a condition for inclusion in the periodontitis group, periodontal examination should demonstrate at least three interproximal periodontal sites, distributed in three independent teeth, with a probing depth of 5 mm or more, 3 mm or more of attachment loss and gingival bleeding on probing. Biopsies were obtained from periodontal lesions exhibiting 5 or more mm of probing depth by a surgical incision comprising the pocket epithelium and gingival connective tissue. All the teeth selected for this procedure required their extraction due to poor periodontal prognosis.

Healthy samples were collected during the extraction of non-inflamed third molars or during crown lengthening surgery. For inclusion in the control group, periodontal examination should not demonstrate sites with a probing depth greater than 3 mm, 1 or more mm of attachment loss and bleeding on probing in less than 10% of the examined sites. Ten healthy and 12 periodontitis tissue samples were used for the MT1-MMP and TIMP-2 analyses through Western-blot. To this end, gingival biopsies were washed in cold physiological saline, frozen in liquid nitrogen and stored at  $-80^{\circ}\text{C}$  until tissue processing. A total of five healthy and eight periodontitis-affected tissue samples were fixed in buffered formalin and used for immunohistochemical procedures.

### *Processing of tissue homogenates for Western-blot*

Tissues were lysed in a buffer containing 1% NP-40 (Calbiochem, San Diego, CA, USA) 0.5% sodium deoxycolate (Calbiochem), 0.2% sodium dodecyl sulfate (Calbiochem), 150 mM NaCl (Calbiochem), 50 mM Tris-HCl (Calbiochem), pH 7.4, in the presence of 2 mM phenylmethylsulfonyl fluoride (Calbiochem), 2 mg ml<sup>-1</sup> pepstatin (Calbiochem), 2 µg ml<sup>-1</sup> leupeptin (Calbiochem), and 1 mM sodium orthovanadate (Calbiochem) in a ratio of 1:5 (weight:volume) at 4°C. The tissue lysate was then centrifuged at 19 000 g for 10 min at 4°C. Protein content in each sample was determined by means of the DC protein assay (Bio-Rad, Hercules, CA, USA). Proteins were resolved by 10% sodium dodecyl sulfate-polyacrylamide gel electrophoresis and transferred to polyvinylidene difluoride transfer membranes (Perkin Elmer Life Sciences, Boston, MA, USA). Membranes blocked with de-fatted milk (3%) and exposed to primary antibodies against MT1-MMP (MAB918) (R&D systems, Minneapolis, MN, USA), TIMP-2 (R&D Systems, Minneapolis, MN, USA) or  $\beta$ -actin (Sigma, St. Louis, MO, USA), secondary antibodies coupled to horseradish peroxidase, and finally developed with an enhanced chemiluminescence kit (Perkin Elmer Life Sciences). Recombinant MT1-MMP (Calbiochem, Darmstadt, Germany) was used as a reference to identify the (66 kDa) MT1-MMP band. Protein expression levels for MT1-MMP and TIMP-2 were estimated by scanning the bands obtained from Western-blot. Digitalized images for each experimental condition were analyzed using the Kodak Molecular Imaging software 4.0 upgrade (Toronto, Canada). These data were then normalized against  $\beta$ -actin levels for each patient.

### *Immunohistochemical analysis*

Tissue samples were fixed in buffered formalin at 4°C for 24 h. Specimens were dehydrated through graded ethanols, cleared in xylene and embedded in paraffin. Serial sections of approximately 5 µm thickness were collected on poly-L-lysine coated glass slides. Sections were deparaffinized in xylene, rehydrated in descending concentrations of ethanol, water and phosphate-buffered saline (PBS). Immunohistochemical detection was performed as follows: to detect MT1-MMP expression, a monoclonal antibody that recognizes the human

MT1-MMP ectodomain was used (R&D Systems, Minneapolis, MN, USA). For MT1-MMP detection, antigen retrieval was performed by immersing 5  $\mu$ m sections in 100 mM Tris-HCl, pH 9.0 and heated in a microwave oven for three cycles (5 min each) at 750 W. To detect TIMP-2 expression, a monoclonal antibody was used (R&D Systems, Minneapolis, MN, USA) and antigen retrieval was performed by degrading sections with trypsin (Sigma, St. Louis, Mo, USA) for 20 min at 37°C. Immunoreactive signal was identified by staining with the peroxidase-antiperoxidase technique (Histo-stain plus, Broad spectrum, Zimed Laboratories, South San Francisco, CA, USA), with diaminobenzidine as chromogenic substrate. In negative control sections, primary antibodies were replaced by non-immune goat serum (Sigma, St. Louis, MO, USA) diluted in 3% bovine serum albumin (BSA). After immunohistochemical procedures, Light green SF yellowish (Allied Chemicals, NY, USA) and Harris hematoxylin (Sigma, St. Louis, MO, USA) were used for counterstaining. Immunohistological specimens were observed and registered using an Axiostar Plus microscope (Carl Zeiss, Göttingen, Germany) coupled to a digital camera (Micropublisher 3.3 RTV, Qimaging, Canada). Shading was corrected using the Axiovision software (Carl Zeiss, Göttingen, Germany). Images were finally processed using the AdobePhotoshop CS2 software (Adobe Systems Incorporated, San Jose, CA, USA).

#### Statistical analysis

For statistical comparison between MT1-MMP and TIMP-2 expression levels and MT1-MMP/TIMP-2 ratios between healthy and periodontitis cases, the non-parametric Mann-Whitney *U*-test for unpaired samples was used. The confidence limit was predetermined at a  $\alpha$  level of 0.05.

## Results

#### Clinical measurements

Clinical records are listed in Table 1. As expected, significantly higher probing depth, attachment loss and bleeding on probing values were recorded in diseased patients compared to healthy subjects. No significant differences in age or gender distribution were observed between both groups.

#### MT1-MMP and TIMP-2 expression in tissue homogenates

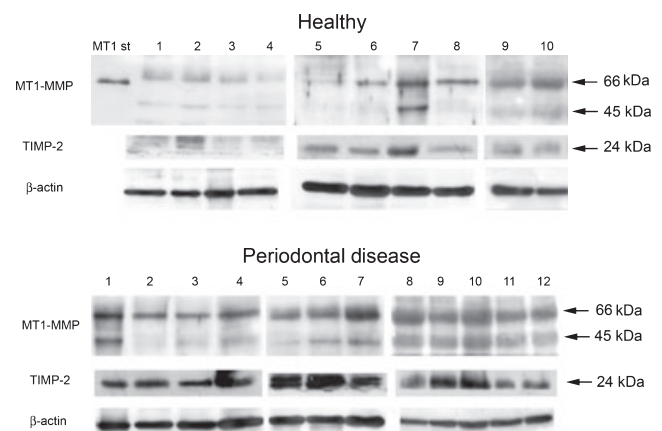
MT1-MMP expression was identified as a 66 kDa band in tissue homogenates of both healthy and periodontal

disease gingival tissues (Figure 1). Recombinant MT1-MMP, used as a reference to identify this protein, gave a slightly lower molecular weight (Figure 1). A quantitative analysis of MT1-MMP bands demonstrated a statistically significant increase in this proteolytic enzyme in samples derived from periodontitis-affected gingiva ( $n = 12$ ) when compared to healthy tissue samples ( $n = 10$ ) ( $P < 0.01$ ) (Figure 1). A second MT1-MMP band, with an estimated molecular weight of 45 kDa, was also detected. This molecular species probably corresponds to an autocatalytically generated band that lacks the catalytic domain (Tam *et al*, 2002). TIMP-2 expression was also identified in tissue homogenates from healthy and periodontitis-affected samples as an approximately 24 kDa band. The quantitative analysis also indicated increased TIMP-2 levels in periodontal disease tissue samples ( $P < 0.01$ ) (Figure 1).

The ratio between the 66 kDa MT1-MMP and TIMP-2 bands was calculated for healthy and periodontal disease tissues. A statistically significant increase in this ratio was observed for periodontitis-affected gingiva (1.4) when compared to healthy tissues (1.0) (Figure 2) ( $P < 0.01$ ).

#### Immunohistochemical analysis

Using immunohistochemistry we evaluated the distribution of MT1-MMP and TIMP-2 in five healthy and eight periodontitis-affected gingival tissue samples; both were detected in diseased and healthy tissue. MT1-MMP was identified in mononuclear cells that resembled tissue macrophages and fibroblasts (Figure 3). After immunohistochemistry, Light green counterstaining was used to evaluate the distribution of MT1-MMP within the gingival connective tissue (Figure 4a). A more intense expression for MT1-MMP was detected in areas characterized by a poorly stained collagenous fibrillar

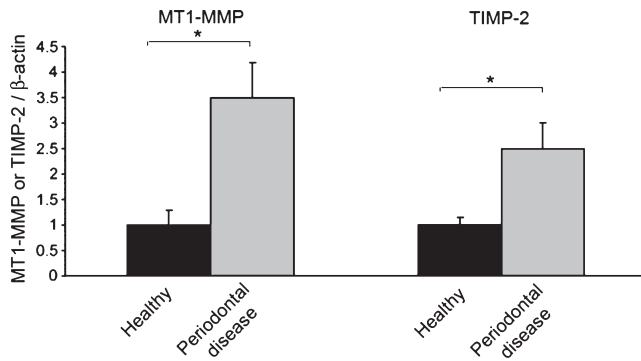


**Figure 1** Expression of MT1-MMP and TIMP-2 in gingival tissue homogenates. Expression levels for MT1-MMP and TIMP-2 were evaluated through Western-blot in healthy and periodontitis-affected gingival tissue samples as indicated in the Material and Methods section. Numbers indicated above each lane in healthy and periodontal disease tissue samples were derived from distinct patients. MT1 st corresponds to recombinant MT1-MMP. Molecular weights were estimated using a pre-stained molecular weight standard.  $\beta$ -actin levels were used as a loading control

**Table 1** Clinical assessment of the sampling sites. Where appropriate values are expressed as mean and standard deviation (s.d.)

	Healthy	Periodontal Disease
Age	40.2 (SD 11.67)	45.87 (SD 8.33) years
Gender	5 men/5 women	5 men/7 women
Attachment loss	0.36 (SD 0.50)	6.62 (SD 2.69) mm
Probing Depth	2 (SD 0.44)	5.5 (SD 1.21) mm
Bleeding on probing	No	Yes





**Figure 2** MT1-MMP and TIMP-2 ratios. MT1-MMP and TIMP-2 expression levels normalized against  $\beta$ -actin are represented as average and standard deviations for healthy and periodontal disease tissue samples. Asterisks indicate statistically significant differences

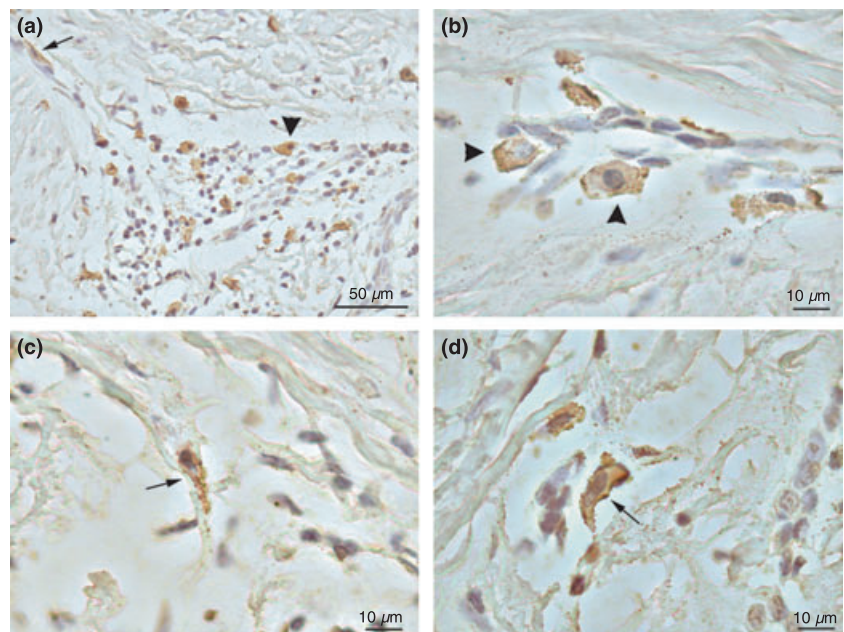
matrix (Figure 4a') when compared to more fibrous areas of the connective tissue (Figure 4a''). A striking observation was an intense staining for MT1-MMP in cells closely associated with fibrillar components of the extracellular matrix (Figure 4b,c). An abundant dotted immunoreactive signal for MT1-MMP was also detected along these fibrillar elements in gingival tissue samples derived from periodontitis patients (arrows in Figure 4c).

TIMP-2 expression was identified in gingival epithelial cells of the oral and pocket epithelium, mononuclear cells and fibroblasts (Figure 5). Negative control sections did not show immunoreactive signals (Figure 6).

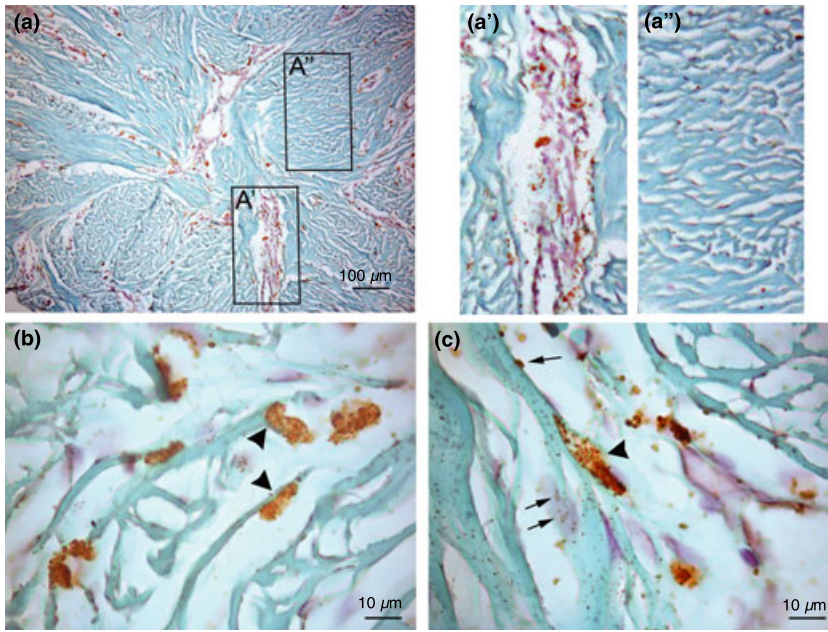
## Discussion

The present study has evaluated the involvement of MT1-MMP and its inhibitor TIMP-2 in untreated

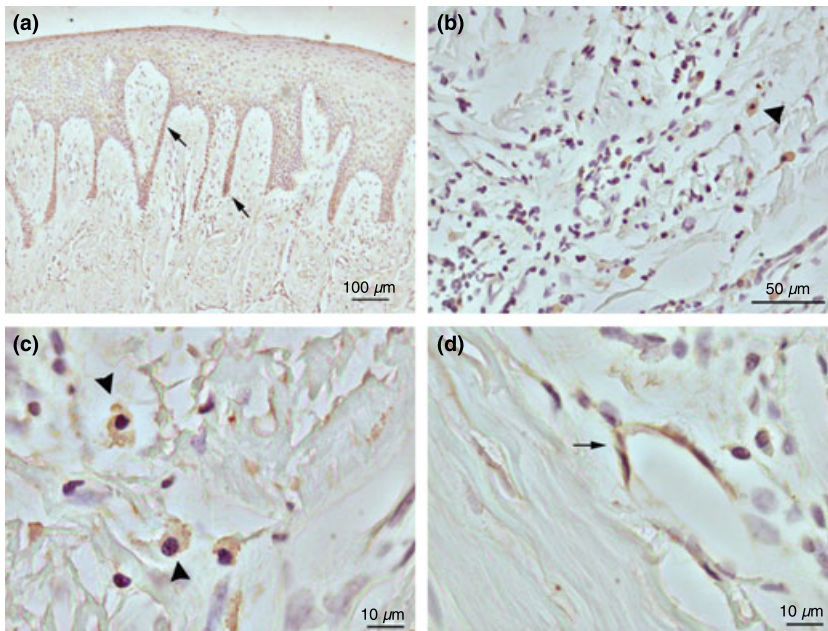
human periodontal disease. Our quantitative Western-blot results show that for both, MT1-MMP and TIMP-2, protein is expressed at higher levels in periodontitis-affected tissues compared to healthy controls. Previous studies have been unable to show a significant change in the expression of MT1-MMP or TIMP-2 in human periodontal disease (Tervahartiala *et al*, 2000; Dahan *et al*, 2001). Using *in situ* hybridization and reverse-transcription polymerase chain reaction, Dahan *et al* (2001), were unable to identify changes in the expression of MT1-MMP and TIMP-2 mRNA levels comparing healthy and periodontal disease tissue samples. However, these authors obtained their tissue samples during flap surgery after completion of an initial phase of scaling and root planning (Dahan *et al*, 2001). Hence, it is probable that this initial phase of periodontal therapy reduced the inflammatory response in the tissues, precluding the observation of significant changes in the expression of the mRNA for MT1-MMP and TIMP-2. Our samples were obtained from patients who did not receive periodontal treatment during the last 6 months prior to sample harvesting. Moreover, the clinical characterization of our samples was planned to identify a control group with a healthy periodontium and a periodontal disease group with evident signs of periodontitis. Therefore, it is possible to assume that our samples were representative of the natural course of periodontal disease. It is important to mention that in a rat model of periodontitis, MT1-MMP and MMP-2 mRNA expression levels were shown to increase following the initiation of this lesion (Achong *et al*, 2003). Previous studies have also identified that MT1-MMP expression is induced by inflammatory cytokines like tumor necrosis factor- $\alpha$  (TNF- $\alpha$ ) in human dermal and rheumatoid synovial fibroblasts (Migita *et al*, 1996; Han *et al*, 2001). Our study group has recently identified that



**Figure 3** MT1-MMP distribution in diseased human gingival tissues. MT1-MMP distribution was assessed through immunohistochemistry in gingival tissue samples affected by periodontal disease. MT1-MMP expression was identified in elongated cells (arrows) (a, c and d) and mononuclear cells that resembled tissue macrophages (arrowheads) (a and b)



**Figure 4** MT1-MMP distribution and gingival extracellular fibrillar matrix. MT1-MMP distribution was evaluated through immunohistochemistry in diseased human gingival tissue samples. The fibrillar extracellular matrix was stained with Light green staining. MT1-MMP (arrows) was present in areas where the gingival collagenous matrix was poorly stained. CT: connective tissue (a). a' and a'' are higher magnifications of insets in figure (a). Cells in close contact with the gingival connective tissue fibrillar matrix were stained for MT1-MMP (arrowheads) (b and c). A scattered staining for MT1-MMP was recognized along fibrillar elements of the gingival connective tissue (arrows) (c)



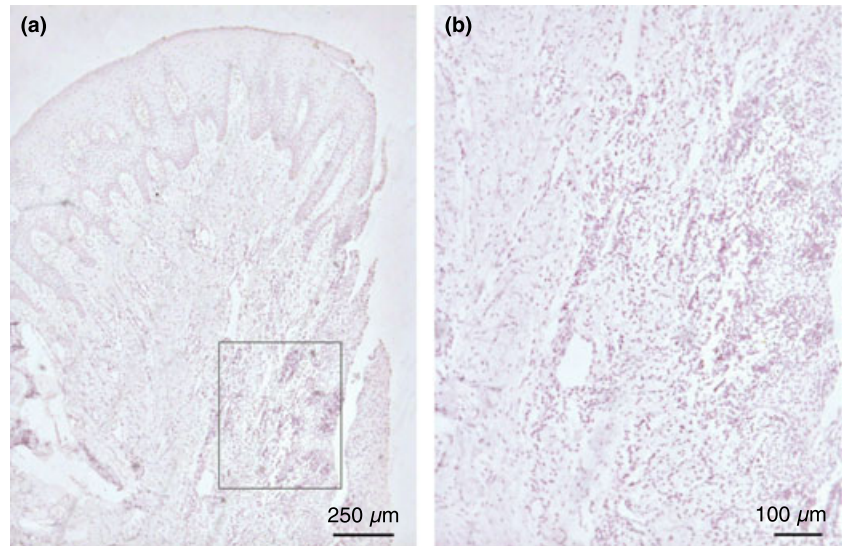
**Figure 5** TIMP-2 distribution in diseased human gingival tissue samples. TIMP-2 distribution was identified in gingival tissue samples using immunohistochemistry. TIMP-2 staining was recognized in epithelial cells of the gingival tissue (arrows) (a), mononuclear cells (arrowheads) (b and c), and elongated cells resembling fibroblasts (arrow) (d)

TNF- $\alpha$  is able to stimulate MT1-MMP production in gingival fibroblasts through the activation of epidermal growth factor receptor (Smith *et al*, 2009). These data supports the possibility that MT1-MMP expression is induced in the periodontium under inflammatory conditions and probably plays a role in periodontal tissue destruction.

Our immunohistochemical observations identified MT1-MMP expression in fibroblasts and macrophage-resembling cells in periodontal tissue samples. MT1-MMP mRNA expression has been identified in fibroblasts located close to inflammatory cells in periodontitis-affected human gingival tissues (Dahan

*et al*, 2001). MT1-MMP has been associated with cell migration in peripheral blood monocytes (Matías-Román *et al*, 2005), intestinal fibroblasts (Pender *et al*, 2000) and tumoral cells (Sabeh *et al*, 2004). In fibroblasts, MT1-MMP has an important role in collagen degradation previous to the phagocytic ingestion of this molecule (Lee *et al*, 2006). Therefore, it is highly probable that MT1-MMP is involved in collagen remodeling and cell migration in periodontal tissues. It is also important to mention that macrophages constitute the main source of TNF- $\alpha$  in periodontal tissues (Rossomando *et al*, 1990). Immunohistochemistry allowed us to identify that mononuclear cells resembling tissue macrophages





**Figure 6** Negative control. Periodontitis-affected gingival tissue sample where primary antibodies were replaced by non-immune serum (**a** and **b**). Figure b corresponds to the inset displayed in (**a**)

were positive for MT1-MMP expression. It is interesting to note that pro-TNF- $\alpha$  may be modified by the proteolytic activity of MT1-MMP (Tam *et al*, 2004). Therefore, it is tempting to propose that MT1-MMP might modify the inflammatory response through the modulation of TNF- $\alpha$  within these tissues. This hypothesis should be evaluated in future studies. Several studies have identified that the collagenolytic enzymes MMP-1 and MMP-13 are expressed by both fibroblasts and macrophages in periodontal tissues (Ingman *et al*, 1994; Meikle *et al*, 1994; Uitto *et al*, 1998). It has been identified that MT1-MMP may activate other collagen degrading enzymes like MMP-13 (Sato *et al*, 1994; Knäuper *et al*, 1996). Therefore, it is interesting to consider that MT1-MMP might contribute to collagen remodeling not only through the direct degradation of triple-helical collagen molecules, but also through the activation of other MMPs like MMP-13, a response that may amplify the proteolytic potential for tissue turn-over.

Our study also reports an imbalance in the MT1-MMP/TIMP-2 ratio in periodontitis-affected human gingival tissues. Several previous studies have suggested that an imbalance between MMPs and TIMPs might explain tissue destruction in periodontitis (Alpagot *et al*, 2001; Soell *et al*, 2002; Pozo *et al*, 2005; Kubota *et al*, 2008). However, to the best of our knowledge, this is the first study to report an imbalance between MT1-MMP and TIMP-2 in human periodontitis. Considering the powerful collagenolytic activity that has been reported for MT1-MMP (Holmbeck *et al*, 1999), it is possible to propose that this proteolytic enzyme might play a significant role in the degradation of the collagen fibers involved in periodontal attachment. Besides its role in collagen degradation, MT1-MMP may degrade and activate proMMP-2 and proMMP-13 (Osenkowski *et al*, 2004). Other non-matrix substrates degraded by MT1-MMP include interleukin-8, secretory leukocyte protease inhibitor, pro-tumor necrosis factor- $\alpha$ , death receptor-6, and connective tissue growth factor (Tam *et al*, 2004). Therefore, MT1-MMP might play an

important role in cell signaling and the regulation of the inflammatory response as well.

Western-blotting from gingival tissue homogenates allowed us to identify an approximately 66 kDa band that was confirmed with the recombinant version for MT1-MMP. This molecular weight is coincident with the premature/inactive version for MT1-MMP (Osenkowski *et al*, 2004). On the other hand, we also detected a second band for MT1-MMP with an estimated molecular weight of 45 kDa. It has been described that MT1-MMP is also found as a series of forms ranging from 40 to 45 kDa that probably correspond to an inactive degradation product that lacks catalytic activity (Lehti *et al*, 1998). Consequently, we considered that this lower molecular weight band corresponded to an inactive version for this enzyme. Therefore, the MT1-MMP/TIMP-2 analysis was performed considering the 66 kDa MT1-MMP band.

A striking observation of our study was the detection of a scattered staining for MT1-MMP along gingival connective tissue fibers. MT1-MMP staining was also detected in cells in close contact with this collagenous matrix. In support of our observation, it has been reported that MT1-MMP has displays the ability to bind to type I collagen through its hemopexin C domain (Tam *et al*, 2002). Although our observations were entirely morphological, we cannot exclude the possibility that MT1-MMP may associate with gingival collagen fibers *in vivo*, and therefore, might regulate collagen degradation in a process that is independent of the presence of cells.

The present study has documented the involvement of MT1-MMP and TIMP-2 in human gingival tissues affected by periodontal disease. Our results show increased levels for both, MT1-MMP and TIMP-2, and an imbalance between these mediators of tissue remodeling in periodontitis tissue samples.

We propose the involvement of the MT1-MMP/TIMP-2 proteolytic axis in periodontal disease as a mediator of connective tissue destruction.

## Acknowledgements

We thank the National Fund for Science and Technology from Chile (FONDECYT N° 1061065, granted to PS) for financing this study.

## Conflict of interest and sources of funding statement

The authors declare that they have no conflicts of interest to disclose.

## References

- Achong R, Nishimura I, Ramachandran H, Howell TH, Fiorellini JP, Karimbux NY (2003). Membrane type (MT)-1 matrix metalloproteinase (MMP) and MMP-2 expression in ligature-induced periodontitis in the rat. *J Periodontol* **74**: 494–500.
- Alpagot T, Bell C, Lundergan W, Chambers DW, Rudin R (2001). Longitudinal evaluation of GCF MMP-3 and TIMP-1 levels as prognostic factors for progression of periodontitis. *J Clin Periodontol* **28**: 353–359.
- Burrage PS, Mix KS, Brinckerhoff CE (2006). Matrix metalloproteinases: role in arthritis. *Front Biosci* **11**: 529–543.
- Dahan M, Nawrocki B, Elkaïm R et al (2001). Expression of matrix metalloproteinases in healthy and diseased human gingiva. *J Clin Periodontol* **28**: 128–136.
- Haerian A, Adonogianaki E, Mooney J, Docherty JP, Kinane DF (1995). Gingival crevicular stromelysin, collagenase and tissue inhibitor of metalloproteinases levels in healthy and diseased sites. *J Clin Periodontol* **22**: 505–509.
- Han Y-P, Tuan T-L, Huayang W, Hughes M, Garner WL (2001). TNF- $\alpha$  stimulates activation of pro-MMP2 in human skin through NF-KB mediated induction of MT1-MMP. *J Cell Sci* **114**: 131–139.
- Holmbeck K, Bianco P, Caterina J et al (1999). MT1-MMP-deficient mice develop dwarfism, osteopenia, arthritis, and connective tissue disease due to inadequate collagen turnover. *Cell* **99**: 81–92.
- Ingman T, Sorsa T, Michaelis J, Konttinen YT (1994). Immunohistochemical study of neutrophil- and fibroblast-type collagenases and stromelysin-1 in adult periodontitis. *Scand J Dent Res* **102**: 342–349.
- Jeffrey JJ (1999). Interstitial collagenases. In: Parks WC, Mecham RP, eds *Matrix metalloproteinase*. 1st edn. San Diego: Academic Press, pp. 15–42.
- Knäuper V, Will H, López-Otin C et al (1996). Cellular mechanisms for human procollagenase-3 (MMP-13) activation. Evidence that MT1-MMP (MMP-14) and gelatinase a (MMP-2) are able to generate active enzyme. *J Biol Chem* **271**: 17124–17131.
- Kubota T, Nomura T, Takahashi T, Hara K (1996). Expression of mRNA for matrix metalloproteinases and tissue inhibitors of metalloproteinases in periodontitis-affected human gingival tissue. *Arch Oral Biol* **41**: 253–262.
- Kubota T, Itagaki M, Hoshino C et al (2008). Altered gene expression levels of matrix metalloproteinases and their inhibitors in periodontitis-affected gingival tissue. *J Periodontol* **79**: 166–173.
- Lee W, Aitken S, Sodek J, McCulloch CAG (1995). Evidence of a direct relationship between neutrophil collagenase activity and periodontal tissue destruction in vivo: role of active enzyme in human periodontitis. *J Periodontol Res* **30**: 23–33.
- Lee H, Overall CM, McCulloch CA, Sodek J (2006). A critical role for the membrane-type 1 matrix metalloproteinase in collagen phagocytosis. *Mol Biol Cell* **17**: 4812–4826.
- Lehti K, Lohi J, Valtanen H, Keski-Oja J (1998). Proteolytic processing of membrane-type-1 matrix metalloproteinase is associated with gelatinase A activation at the cell surface. *Biochem J* **334**: 345–353.
- Ma J, Sorsa T, Billingham CR et al (2003). Direct evidence of collagenolysis in chronic periodontitis. *J Periodontol Res* **38**: 564–567.
- Matías-Román S, Gálvez BG, Genís L et al (2005). Membrane-type 1-matrix metalloproteinase is involved in migration of human monocytes and is regulated through their interaction with fibronectin or endothelium. *Blood* **105**: 3956–3964.
- Meikle MC, Hembry RM, Holley J, Horton C, McFarlane CG, Reynolds JJ (1994). Immunolocalization of matrix metalloproteinases and TIMP-1 (tissue inhibitor of metalloproteinases) in human gingival tissues from periodontitis patients. *J Periodontol Res* **29**: 118–126.
- Migita K, Eguchi K, Kawabe Y et al (1996). TNF- $\alpha$ -mediated expression of membrane-type matrix metalloproteinase in rheumatoid synovial fibroblasts. *Immunology* **89**: 553–557.
- Orlichenko LS, Radisky DC (2008). Matrix metalloproteinases stimulate epithelial-mesenchymal transition during tumor development. *Clin Exp Metastasis* **25**: 593–600.
- Osenkowski P, Toth M, Fridman R (2004). Processing, shedding, and endocytosis of membrane type-1 matrix metalloproteinase (MT1-MMP). *J Cell Physiol* **200**: 2–10.
- Page RC, Offenbacher S, Schroeder HE, Seymour GJ, Kornman KS (1997). Advances in the pathogenesis of periodontitis: summary of developments, clinical implications and future directions. *Periodontol* **2000**: 14. 216–248.
- Page-McCaw A, Ewald AJ, Werb Z (2007). Matrix metalloproteinases and the regulation of tissue remodelling. *Nat Rev Mol Cell Biol* **8**: 221–233.
- Pender SL, Salmela MT, Monteleone G et al (2000). Ligation of  $\alpha$ 4 $\beta$ 1 integrin on human intestinal mucosal mesenchymal cells selectively Up-regulates membrane type-1 matrix metalloproteinase and confers a migratory phenotype. *Am J Pathol* **157**: 1955–1962.
- Pozo P, Valenzuela MA, Melej C et al (2005). Longitudinal analysis of metalloproteinases, tissue inhibitors of metalloproteinases and clinical parameters in gingival crevicular fluid from periodontitis-affected patients. *J Periodontol Res* **40**: 199–207.
- Raffetto JD, Khalil RA (2008). Matrix metalloproteinases and their inhibitors in vascular remodeling and vascular disease. *Biochem Pharmacol* **75**: 346–359.
- Rossomando EF, Kennedy JE, Hadjimichael J (1990). Tumour necrosis factor  $\alpha$  in gingival crevicular fluid as a possible indicator of periodontal disease in humans. *Arch Oral Biol* **35**: 431–434.
- Sabeh F, Ota I, Holmbeck K et al (2004). Tumor cell traffic through the extracellular matrix is controlled by the membrane-anchored collagenase MT1-MMP. *J Cell Biol* **167**: 769–781.
- Sato H, Takino T, Okada Y et al (1994). A matrix metalloproteinase expressed on the surface of invasive tumour cells. *Nature* **370**: 61–65.
- Silva N, Dutzan N, Hernandez M et al (2008). Characterization of progressive periodontal lesions in chronic periodontitis patients: levels of chemokines, cytokines, matrix metalloproteinase-13, periodontal pathogens and inflammatory cells. *J Clin Periodontol* **35**: 206–214.

- Smith PC, Guerrero J, Tobar N, Cáceres M, González MJ, Martínez J (2009). Tumor necrosis factor- $\alpha$ -stimulated membrane type 1-matrix metalloproteinase production is modulated by epidermal growth factor receptor signaling in human gingival fibroblasts. *J Periodontol Res* **44**: 73–80.
- Soell M, Elkaim R, Tenenbaum H (2002). Cathepsin C, matrix metalloproteinases, and their tissue inhibitors in gingiva and gingival crevicular fluid from periodontitis-affected patients. *J Dent Res* **81**: 174–178.
- Sorsa T, Tjäderhane L, Kontinen YT *et al* (2006). Matrix metalloproteinases: contribution to pathogenesis, diagnosis and treatment of periodontal inflammation. *Ann Med* **38**: 306–321.
- Strongin AY, Collier L, Bannikov G, Marmer BL, Grant GA, Goldberg GI (1995). Mechanism of cell surface activation of 72-kDa type IV collagenase. Isolation of the activated form of the membrane metalloprotease. *J Biol Chem* **270**: 5331–5338.
- Tam EM, Wu YI, Butler GS, Stack MS, Overall CM (2002). Collagen binding properties of the membrane type-1 matrix metalloproteinase (MT1-MMP) hemopexin C domain. *J Biol Chem* **277**: 39005–39014.
- Tam EM, Morrison CJ, Wu YI, Stack MS, Overall CM (2004). Membrane protease proteomics: Isotope-coded affinity tag MS identification of undescribed MT1–matrix metalloproteinase substrates. *Proc Natl Acad Sci USA* **101**: 6917–6922.
- Tervahartiala T, Pirilä E, Ceponis A *et al* (2000). The in vivo expression of the collagenolytic matrix metalloproteinases (MMP-2, -8, -13, and -14) and matrilysin (MMP-7) in adult and localized juvenile periodontitis. *J Dent Res* **79**: 1969–1977.
- Uitto V-J, Airola K, Vaalamo M *et al* (1998). Collagenase-3 (matrix metalloproteinase-13) expression is induced in oral mucosal epithelium during chronic inflammation. *Am J Pathol* **152**: 1489–1499.
- Wooley DE, Davies RM (1981). Immunolocalization of collagenase in periodontal disease. *J Periodontol Res* **16**: 292–297.
- Zucker S, Drews M, Conner C *et al* (1998). Tissue inhibitor of metalloproteinase-2 (TIMP-2) binds to the catalytic domain of the cell surface receptor, membrane type 1-matrix metalloproteinase 1 (MT1-MMP). *J Biol Chem* **273**: 1216–1222.



Copyright of Oral Diseases is the property of Wiley-Blackwell and its content may not be copied or emailed to multiple sites or posted to a listserv without the copyright holder's express written permission. However, users may print, download, or email articles for individual use.