

CH Kau  
A Cronin  
P Durning  
AI Zhurov  
A Sandham  
S Richmond

# A new method for the 3D measurement of postoperative swelling following orthognathic surgery

## Authors' affiliations:

C.H. Kau, P. Durning, A.I. Zhurov, S. Richmond, Dental Health and Biological Sciences, Wales College of Medicine, Biology, Life and Health Sciences, Cardiff University, Cardiff, UK

A. Cronin, Department of Oral and Maxillofacial Surgery, Cardiff and Vale NHS Trust, University Hospital of Wales, Cardiff, UK

A. Sandham, Department of Orthodontics, University Medical Center Groningen, Groningen, The Netherlands

## Correspondence to:

Dr Chung How Kau  
Department of Dental Health and Biological Sciences  
Wales College of Medicine, Biology, Life and Health Sciences  
Cardiff University  
Heath Park  
Cardiff CF14 4XY  
UK  
Tel.: +44 29 20742447  
Fax: +44 29 20746489  
E-mail: [kauc@cardiff.ac.uk](mailto:kauc@cardiff.ac.uk)

## Dates:

Accepted 29 June 2005

To cite this article:

*Orthod Craniofacial Res* 9, 2006; 31–37

Kau CH, Cronin A, Durning P, Zhurov AI, Sandham A, Richmond S:

A new method for the 3D measurement of postoperative swelling following orthognathic surgery

Copyright © Blackwell Munksgaard 2006

## Structured Abstract

**Authors** – Kau CH, Cronin A, Durning P, Zhurov AI, Sandham A, Richmond S

**Objective** – To describe a new method for measuring facial swelling following orthognathic surgery using a 3D laser-scanning device.

**Design** – Prospective clinical trial.

**Setting and Sample Population** – University Dental Hospital, Wales College of Medicine, Biology Life and Health Sciences. Three subjects requiring bi-maxillary orthognathic surgery were recruited for the study.

**Experimental Variables** – Laser-scanned images of the subjects were obtained under a reproducible and controlled environment with two Minolta Vivid 900 (Osaka, Japan) optical laser-scanning devices assembled as a stereo-pair. A set of left and right scanned images was taken for each subject and each scan took an average of 2.5 s. 3D laser scans were recorded over six time periods (T1 – pre-surgical scan, postoperatively: T2 – 1 day, T3 – 1 week, T4 – 1 month, T5 – 3 months and T6 – 6 months).

**Outcome Measure** – Facial scans from different time periods were overlaid onto the baseline (T6) facial scan to determine the reduction and changes in swelling following orthognathic surgery.

**Results** – The results showed that swelling could be accurately quantified following surgery. Furthermore, there was a significant reduction in the amount of swelling 1 month postoperatively. Furthermore, the facial morphology returned to approximately 90% of the baseline facial scan at 3 months.

**Conclusion** – The 3D laser-scanning device and the method described was a reliable and accurate measure of facial swelling following surgery.

**Key words:** 3D; clinical study; facial evaluation; laser scanning; orthognathic surgery; postoperative swelling

## Introduction

3D technology has improved at a rapid pace over the last decade allowing newer machines and advanced software support to be created. These have produced fast, efficient and cost-effective applications for the clinical setting.

There have been a numerous reports of methods to capture facial images and these may be broadly classified into the following:

1. 3D Cephalometry (1)
2. Laser scanning [MGI Group (2–4), Minolta 700 (5,6), Minolta 900 (7,8), Hand-held devices (9), others (10)]
3. Moire Techniques (11,12)
4. 3D morphometry (13,14)
5. Stereo-photogrammetry (15–17)
6. Patterned light techniques (18–20)
7. Conventional CT scans
8. 3D Cone Beam CT scans (21–23)
9. 3D MRI scans

The variety of applications with these three-dimensional devices has resulted in a better understanding of the craniofacial form. In recent times, three-dimensional images have been created to establish databases for normative populations (24), cross-sectional growth changes (25,26), and also in the assessment of clinical outcomes in surgical (27–33) and non-surgical treatments (34–36) in the head and neck region.

One area of interest to a multi-disciplinary group of clinicians is the study of soft tissue changes associated with orthognathic surgery. Previous studies have described the changes in soft tissue dimensions following surgery by plotting linear measurements on landmark-based points (37). Others have compared treatment changes between groups of normal adults and those with facial disproportion (38) by comparing the colour codes on facial deviation maps. Recently, studies have also compared facial asymmetry before and after surgery (39). To optimize the advancement in technology, some studies have also attempted to combine hard and soft tissue data imaging techniques (40,41). All these improvements in software applications have meant that validation and quantification of volumetric changes following routine oral and maxillofacial surgery can be attempted easily (9,42,43).

3D laser scanning is a useful tool in the study of facial morphology. The 3D images are obtained by laser triangulation from an optical source projected onto the subject to be measured. The resultant distortion of the light pattern on the subject is captured on a charged couple device (CCD) device and converted into a computer-generated image. The scanning process is non-invasive and normally completed within a few seconds. Previous studies have reported on the validity and high accuracy of the Minolta 700 and 900 scanners (Osaka, Japan) and found them to be accurate to the level of  $1.9 \pm 0.8$  mm (5) and  $1.1 \pm 0.3$  mm (41). Other studies by the authors have shown that the Minolta 900 is accurate to a level of  $0.56 \pm 0.25$  mm (8) and the error in computerized registration of left and right scans is  $0.13 \pm 0.18$  mm (44). Furthermore, three-dimensional soft tissue capture can be carried out reliably and in a reproducible manner (45).

Despite the increasing number of reports in the literature, no study has attempted to evaluate the amounts of facial swelling following orthognathic surgery in 3D. This study describes a new method to determine the amounts of facial swelling following orthognathic surgery and attempts to provide information both to the clinician and patient on the associated soft tissue changes.

## Materials and methods

### Subjects

Approval for the study was obtained from the relevant ethics committee and each patient consented to participate in the study. The sample consisted of three clinical subjects (two males and one female) with a mean age of 20.3 years, each requiring orthognathic surgery. Each patient presented at the time of investigation with a Class III skeletal malocclusion underwent a bi-maxillary operation by a single operator to correct the relevant facial deformity. The severity of the malocclusion and surgical procedures carried out are recorded in Table 1.

The pharmacological management of postoperative swelling was standardized and each patient received three doses of 1.3 g Augmentin® (GlaxoSmithKline UK, Uxbridge, UK) and 8 mg Dexametasone® (Faulding Pharmaceuticals, Warwickshire, UK); one dose at the

**Table 1. Classification of subject malocclusion and surgical movements carried out (F, forward movement; B, backward movement)**

Subject	Overjet at start of treatment (mm)	Surgical movements	
		Maxilla (mm) (F)	Mandible (mm) (B)
JR	-4.0	5	2
BP	-5.0	4	2.5
CR	-4.0	4	3

induction of anaesthesia and two other postoperative doses during the period of recovery in the hospital. All subjects were discharged within 3 days following surgery.

### Three-dimensional imaging system

The laser-scanning system, consisting of two high-resolution Minolta Vivid VI900 3D cameras, with a reported manufacturing accuracy of 0.3 mm, operating as a stereo-pair, was used. Each of these cameras emits an eye safe Class I laser (FDA)  $\lambda = 690$  nm at 30 mW with an object to scanner distance of 600–2500 mm and a fast mode scan time of 0.3 s. The system uses a one-half-frame transfer CCD and can acquire 307 000 data points. The scanner's output data is  $640 \times 480$  pixels for 3D and includes red, green and blue colour data. Data were recorded on a desktop workstation with a 2 GHz Pentium 4 processor. For surface registration, a Minolta medium range lens with focal length of 14.5 mm was used. The scanners were placed at a distance of 1350 mm from the head frame. The scanners were controlled with Multi-scan<sup>TM</sup> software (@ cebas Computer GmbH, Eppelheim, Germany) and data coordinates were saved in a vivid file format (vvd). Information was transferred to a reverse modelling software package Rapidform<sup>TM</sup> 2004 PP2 (@ INUS Technology Inc., Seoul, Korea) – RF4 for analysis. This software provides nine different 3D work activities and together allows high-quality polygon meshes, accurate freeform Non-Uniform Rationale B-Spline surfaces and geometrically perfect solid models to be created. RF4 generates data as absolute mean shell deviations, standard deviations of the errors during shell overlaps, maximum and minimum range maps, histogram plots and colour maps. All linear measurements are made in millimetres.

### Data capture technique

A custom-built studio facilitated standardized light conditions. Natural head posture (NHP) was adopted for this study as this has been shown to be clinically reproducible (46). The subjects sat on a self-adjustable stool and were asked to look into a mirror with standard horizontal and vertical lines simulating a cross marked on it. They were asked to level their eyes to the horizontal line and the midline of the face was aligned to the vertical line. Adjustments to seating heights were made to assist the subjects in achieving NHP. The subjects were also instructed to swallow hard and to keep their jaws in a relaxed position just before the scans were taken. The total scan time was approximately 7.5 s.

### Data processing of left and right facial scans

Extraneous data were removed by an in-house developed software sub-routine (47). This automatic and systematic process further reduced the scanned images into shells and identified those small shells that represented minor scanning distortions. These images were smoothed out, while preserving all shape and volume, and the left and right scans were aligned to one another based on the areas of overlap of the faces. The pre-merged scans were carefully checked individually and unwanted areas that could not be automatically removed were done so manually by dividing the unwanted areas from the main shell before proceeding to the next stage. Finally, one whole face was generated for each subject.

### Facial analysis

3D laser scans were recorded over six time periods (T1 – pre-surgical scan, postoperatively: T2 – 1 day, T3 – 1 week, T4 – 1 month, T5 – 3 months and T6 – 6 months). To facilitate the study of surface changes associated with facial swelling after surgery, the surface scan recorded on the sixth month (T6) was used as the baseline to compare all the surface changes after surgery. Each individual's surface scan for the time period was overlaid on the baseline by aligning five points on the facial scans (our points at the outer and inner cantus of the eyes and one point on the nasal tip). The superimposition was finalized by using the iterative closest point (ICP) or best fit algorithm inbuilt with RF4.

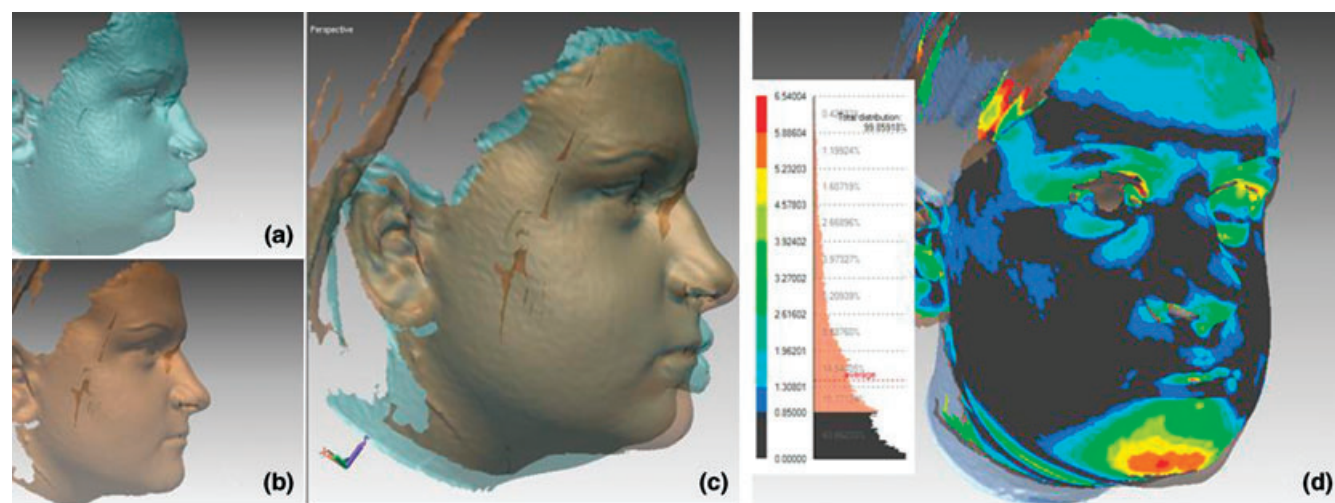


Fig. 1. (a) Facial scan at 6 months, (b) facial scan at baseline (T6), (c) alignment of facial scans based on the ICP or best fit algorithm, (d) shell deviation map showing the differences between surface facial scans. A tolerance of 0.85mm has been applied and corresponds to 43.66% for both faces indicating no change between the faces.

The shell-to-shell deviation was measured on a sliding colour scale which displayed the percentage changes corresponding to the deviation in facial contours between each time point (Fig. 1).

To determine the facial changes as a result of treatment, a previously known value of 0.80 mm was applied to each set of shell deviations (48). The percentage not corresponding to this value was recorded as the percentage change from treatment changes and facial swelling after surgery. The above-mentioned value was obtained from a study to determine the reproducibility of facial morphology using 3D facial scans over a 1 week period.

Results

The results of the study are summarized in Table 2 and Fig. 2 for the three subjects BP, CR and JR.

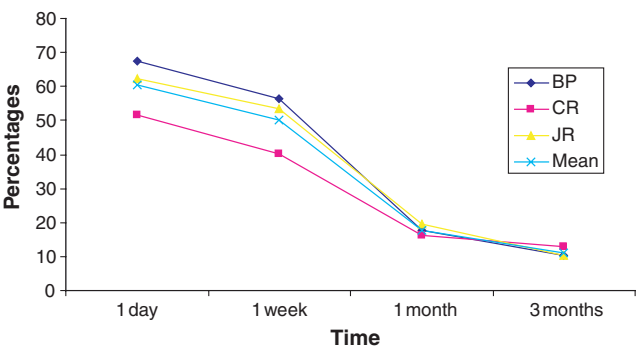


Fig. 2. Percentage decrease in facial swelling over a 6-month period.

Facial swelling changes

The percentage change in facial swelling was greatest during the first day following surgery and this corresponded to a mean increase of 60.35%. The areas where the majority of the postoperative swelling occurred corresponded well with the location of the surgical

Table 2. Areas showing no changes to baseline facial scan during the different time periods

Subject	Skeletal relationship	Areas corresponding to 0.80 mm as percentages			
		T2 vs. T6 (1 day)	T3 vs. T6 (1 week)	T4 vs. T6 (1 month)	T5 vs. T6 (3 months)
BP	Class III	32.70	43.67	82.20	89.65
CR	Class III	48.53	59.85	83.77	87.22
JR	Class III	37.71	46.52	80.62	89.70
Mean	Class III	39.65	50.01	82.20	88.86

movements. These areas could be isolated and quantified by changes in the facial maps (Fig. 3).

Facial swelling reduced substantially within the first month following surgery. The amount of overlap between the faces at the relevant time period was on average 82.20%. This was further improved to 88.8% at 3 months.

#### Reduction in facial swelling

In order to determine the percentage reduction in facial swelling, the difference as a result of facial deviation for each set of scans was calculated by subtracting the present amounts of swelling against the original amount of swelling present on the 'first day' (T2 vs. T6). This value was further divided by the original 'first day' swelling value to give a percentage score representing the reduction in swelling that occurred. [For example, the facial change for BP at 1 week was calculated as  $(56.33 - 67.30) / 67.30 = 16.30\%$ ].

The changes for each subject were recorded at each time period and the mean scores calculated. The improvements in facial swelling were recorded as 17.15%, 70.51% and 81.54% after 1 week, 1 month and 3 months respectively. The greatest reduction in swelling occurred within the first month following orthognathic surgery.

## Discussion

3D soft tissue changes following orthognathic surgery have been of great interest to clinicians and patients. Most of the current studies measure soft tissue changes a significant time period after surgery has been conducted.

A recent study did attempt to quantify the swelling changes following surgical removal of mandibular third molars. 3D facial morphology from each subject was studied before and 2 days after surgery and an attempt at quantifying volumetric changes was made. The results however, were not conclusive about the reduction in postoperative swelling after surgery, although the authors managed to describe a range of volume changes (9).

No study to date has described chronologically the changes that occur as a result of surgery. Therefore, a number of limitations and questionable assumptions had to be made by this initial study. The first assumption presumed that the soft tissue remained stable after 6 months. This is not entirely accurate as soft tissue changes do occur some time later (up to 2 years postoperatively). However, the changes are minimal and the majority of the facial morphology should be close to the final morphology and minor changes can be tolerated. A second assumption of this study was the stability of the surgical movements

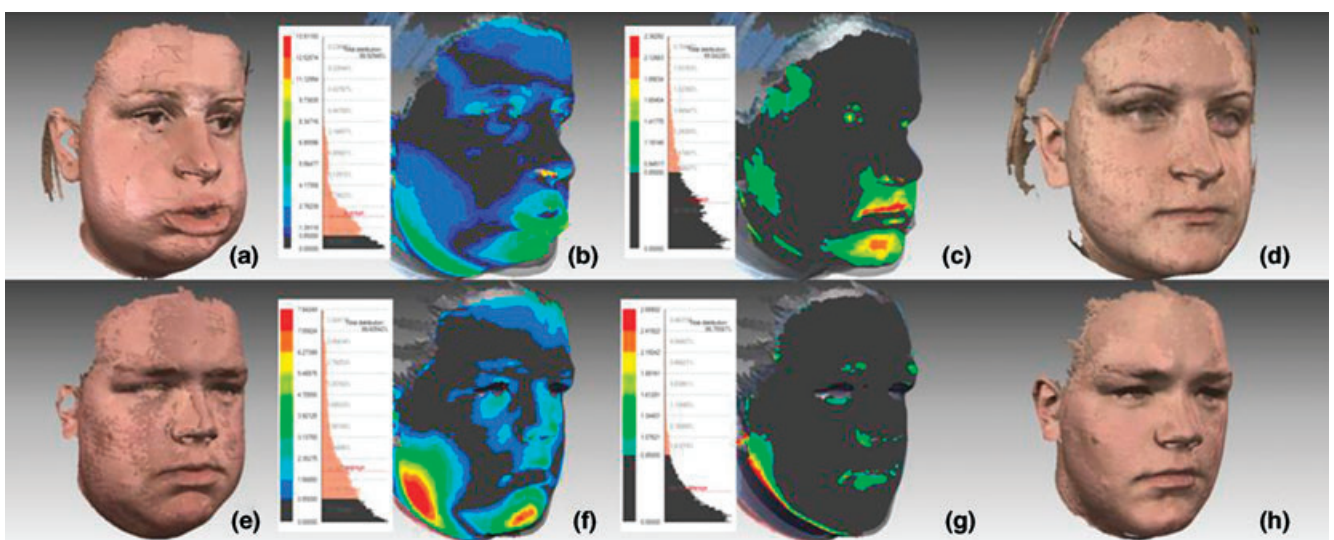


Fig. 3. Measurement of facial swelling following orthognathic surgery. (a–d) Subject BP: (a) 1 day after surgery, (b) facial map comparing 1 day and baseline (67% swelling present), (c) facial map comparing 1 month and baseline (17.8% swelling still present), (d) 6 months after surgery. (e–h) Subject CR: (e) 1 day after surgery, (f) facial map comparing 1 day and baseline (51.47% swelling present), (g) facial map comparing 1 month and baseline (16.23% swelling still present), (h) subject 6 months after surgery.

made, as these would also contribute to the changes in the volumes seen during the study. Bi-maxillary surgery has been shown to be a relatively stable treatment procedure (49). Therefore, it could be assumed that no adverse bony relapse occurred during the 6-month study period.

This study describes a new method of studying postoperative swelling following orthognathic surgery and forms part of a larger trial currently in progress. Patients are often anxious to know the treatment effects following orthognathic surgery and current information available provided has been extrapolated from research using 2D data. As a result, clinicians may not have been able to provide an accurate picture to the patient and to give advice regarding the morbidity involved. The successful application of this new method of analysis means that clinical trials can now be designed to improve surgical techniques and drug regimes. Finally, the imaging device used is fast, non-invasive and an efficient method to capture 3D information of facial morphology.

## Conclusion

The following conclusions may be drawn from this study:

1. The laser-scanning system employed in this study is a quick, efficient and non-invasive method to capture facial morphology.
2. A significant amount of swelling is reduced after 1 month following bi-maxillary orthognathic surgery.
3. Facial morphology recovers to approximately 90% of the baseline (T6) within 3 months following surgery.

**Acknowledgements:** Ethical approval was granted by the ethics committee at the University Hospital, Cardiff 04/WSE03/109. We would like to thank Mr Frank Hartles, Mr Roger Maggs, Miss Angela Stych, Miss Bethan Lewis, Miss Claire Donaghy and Dr Jeremy Knox for their contributions and supportive roles.

## References

1. Broadbent BHS, Broadbent BHJ, Golden WH. *Bolton Standards of Dentofacial Developmental Growth*. St Louis, MO: CV Mosby; 1975.
2. Moss JP. Northcroft revisited. *Br J Orthod* 1989;**16**:155–67.
3. Moss JP, Coombes AM, Linney AD, Campos J. Methods of three dimensional analysis of patients with asymmetry of the face. *Proc Finn Dent Soc* 1991;**87**:139–49.
4. Moss JP, Grindrod SR, Linney AD, Arridge SR, James D. A computer system for the interactive planning and prediction of maxillofacial surgery. *Am J Orthod Dentofacial Orthop* 1988;**94**:469–75.
5. Kusnoto B, Evans CA. Reliability of a 3D surface laser scanner for orthodontic applications. *Am J Orthod Dentofacial Orthop* 2002;**122**:342–8.
6. Tuncay OC. Three-dimensional imaging and motion animation. *Semin Orthod* 2001;**7**:244–50.
7. Marmulla R, Muhling J, Luth T, Eggers G, Hassfeld S. Advanced surface-recording techniques for computer-assisted oral and maxillofacial surgery. *Br J Oral Maxillofac Surg* 2004;**42**:511–9.
8. Kau CH, Zhurov AI, Knox J, Richmond S. The validity and reliability of a portable 3-dimensional laser scanner for field studies. In: Giuliani R, Galliani EE, editors. 7th European Craniofacial Congress, 2004, Bologna, Italy: Monduzzi Editore – International Proceedings Division; 2004. pp. 41–5.
9. Harrison JA, Nixon MA, Fright WR, Snape L. Use of hand held laser scanning in the assessment of facial swelling: a preliminary study. *Br J Oral Maxillofac Surg* 2004;**42**:8–17.
10. Zhang J, Lu P, Wang Y. A study on the stability and reliability of 3D laser cranio-maxillofacial reconstruction. *Zhonghua Kou Qiang Yi Xue Za Zhi* 2002;**37**:469–71.
11. Rabey G. *Morphanalysis*. London: Hatch, Pinner and Co. Ltd; 1968.
12. Takasaki H. Moire topography. *Appl Opt* 1970;**9**:1457–72.
13. Ferrario VF, Sforza C, Puleo A, Poggio CE, Schmitz JH. Three-dimensional facial morphometry and conventional cephalometrics: a correlation study. *Int J Adult Orthodon Orthognath Surg* 1996;**11**:329–38.
14. Ferrario VF, Sforza C, Poggio CE, Serrao G. Facial three-dimensional morphometry. *Am J Orthod Dentofacial Orthop* 1996;**109**:86–93.
15. Von Thomann J, Rivett LJ. Applications of photogrammetry to orthodontics. *Aust Orthod J* 1982;**7**:162–7.
16. Ayoub AF, Wray D, Moos KF, Jin J, Niblett TB, Urquhart C et al. A three-dimensional imaging system for archiving dental study casts: a preliminary report. *Int J Adult Orthodon Orthognath Surg* 1997;**12**:79–84.
17. Burke PH. Stereophotogrammetric measurement of normal facial asymmetry in children. *Hum Biol* 1971;**43**:536–48.
18. Mah J, Ritto AK. Imaging in orthodontics: present and future. *J Clin Orthod* 2002;**36**:619–25.
19. Curry S, Baumrind S, Carlson S, Beers A, Boyd R. Integrated three-dimensional craniofacial mapping at the Craniofacial research instrumentation laboratory/University of the Pacific. *Semin Orthod* 2001;**7**:258–65.
20. Techalertpaisarn P, Kuroda T. Three-dimensional computer-graphic demonstration of facial soft tissue changes in mandibular prognathic patients after mandibular sagittal ramus osteotomy. *Int J Adult Orthodon Orthognath Surg* 1998;**13**:217–25.
21. Kau CH, Palomo JM, Richmond S, Hans MG. Three-dimensional cone beam computerized tomography. *J Orthod* 2005;**32**:281–92.
22. Danforth RA, Peck J, Hall P. Cone beam volume tomography: an imaging option for diagnosis of complex mandibular third molar anatomical relationships. *J Calif Dent Assoc* 2003;**31**:847–52.

23. Mah J, Hatcher D. Three-dimensional craniofacial imaging. *Am J Orthod Dentofacial Orthop* 2004;**126**:308–9.
24. Yamada T, Mori Y, Katsuhiko M, Katsuaki M, Tsukamoto Y. Three-dimensional analysis of facial morphology in normal Japanese children as control data for cleft surgery. *Cleft Palate Craniofac J* 2002;**39**:517–26.
25. Nute SJ, Moss JP. Three-dimensional facial growth studied by optical surface scanning. *J Orthod* 2000;**27**:31–8.
26. Kau CH, Zhurov AI, Bibb R, Hunter ML, Richmond S. The investigation of the changing facial appearance of identical twins employing a three-dimensional laser imaging system. *Orthod Craniofac Res* 2005;**8**:85–90.
27. Ayoub AF, Siebert P, Moos KF, Wray D, Urquhart C, Niblett TB. A vision-based three-dimensional capture system for maxillofacial assessment and surgical planning. *Br J Oral Maxillofac Surg* 1998;**36**:353–7.
28. Ayoub AF, Wray D, Moos KF, Siebert P, Jin J, Niblett TB et al. Three-dimensional modeling for modern diagnosis and planning in maxillofacial surgery. *Int J Adult Orthodon Orthognath Surg* 1996;**11**:225–33.
29. Ji Y, Zhang F, Schwartz J, Stile F, Lineaweaver WC. Assessment of facial tissue expansion with three-dimensional digitizer scanning. *J Craniofac Surg* 2002;**13**:687–92.
30. Khambay B, Nebel JC, Bowman J, Walker F, Hadley DM, Ayoub A. 3D stereophotogrammetric image superimposition onto 3D CT scan images: the future of orthognathic surgery. A pilot study. *Int J Adult Orthodon Orthognath Surg* 2002;**17**:331–41.
31. McCance AM, Moss JP, Fright WR, Linney AD, James DR. Three-dimensional analysis techniques – Part 1: Three-dimensional soft-tissue analysis of 24 adult cleft palate patients following Le Fort I maxillary advancement: a preliminary report. *Cleft Palate Craniofac J* 1997;**34**:36–45.
32. Marmulla R, Hassfeld S, Luth T, Muhling J. Laser-scan-based navigation in cranio-maxillofacial surgery. *J Craniomaxillofac Surg* 2003;**31**:267–77.
33. McCance AM, Moss JP, Wright WR, Linney AD, James DR. A three-dimensional soft tissue analysis of 16 skeletal class III patients following bimaxillary surgery. *Br J Oral Maxillofac Surg* 1992;**30**:221–32.
34. Moss JP, Ismail SF, Hennessy RJ. Three-dimensional assessment of treatment outcomes on the face. *Orthod Craniofac Res* 2003;**6**(Suppl. 1):126–31; discussion 179–82.
35. Ismail SF, Moss JP, Hennessy R. Three-dimensional assessment of the effects of extraction and nonextraction orthodontic treatment on the face. *Am J Orthod Dentofacial Orthop* 2002;**121**:244–56.
36. McDonagh S, Moss JP, Goodwin P, Lee RT. A prospective optical surface scanning and cephalometric assessment of the effect of functional appliances on the soft tissues. *Eur J Orthod* 2001;**23**:115–26.
37. Berkowitz S, Cuzzi J. Biostereometric analysis of surgically corrected abnormal faces. *Am J Orthod* 1977;**72**:526–38.
38. McCance AM, Moss JP, Fright WR, Linney AD, James DR. Three-dimensional analysis techniques – Part 2: Laser scanning: a quantitative three-dimensional soft-tissue analysis using a color-coding system. *Cleft Palate Craniofac J* 1997;**34**:46–51.
39. Hajeer MY, Ayoub AF, Millett DT. Three-dimensional assessment of facial soft-tissue asymmetry before and after orthognathic surgery. *Br J Oral Maxillofac Surg* 2004;**42**:396–404.
40. Xia J, Samman N, Yeung RW, Wang D, Shen SG, Ip HH et al. Computer-assisted three-dimensional surgical planning and simulation. 3D soft tissue planning and prediction. *Int J Oral Maxillofac Surg* 2000;**29**:250–8.
41. Marumulla R, Hassfeld S, Luth T, Muhling A. Laser-scan-based navigation in cranio-maxillofacial surgery. *J Craniomaxillofac Surg* 2003;**31**:267–77.
42. Hajeer MY, Mao Z, Millett DT, Ayoub AF, Siebert JP. A new three-dimensional method of assessing facial volumetric changes after orthognathic surgery. *Cleft Palate Craniofac J* 2005;**42**:113–20.
43. Yip E, Smith A, Yoshino M. Volumetric evaluation of facial swelling utilizing a 3-D range camera. *Int J Oral Maxillofac Surg* 2004;**33**:179–82.
44. Kau CH, Zhurov AI, Scheer R, Bouwman S, Richmond S. The feasibility of measuring three-dimensional facial morphology in children. *Orthod Craniofac Res* 2004;**7**:198–204.
45. Kau CH, Richmond S, Zhurov AI, Chestnutt I, Hartles FR, Knox J et al. Reliability of measuring facial morphology using a 3-dimensional laser scanning system. *Am J Orthod Dentofacial Orthop* 2005;**128**:424–30.
46. Kau CH, Hartles FR, Knox J, Zhurov AI, Richmond S. Natural head posture for measuring three-dimensional soft tissue morphology. In: Middleton J, Shrive MG, Jones ML, editors. *Computer Methods in Biomechanics & Biomedical Engineering* – 5. Cardiff: FIRST Numerics Ltd; 2005. ISBN 0-9549670-0-3.
47. Zhurov AI, Kau CH, Richmond S. Computer methods for measuring 3D facial morphology. In: Middleton J, Shrive MG, Jones ML, editors. *Computer Methods in Biomechanics & Biomedical Engineering* – 5. Cardiff: FIRST Numerics; 2005. ISBN 0-9549670-0-3.
48. Savio C, Mallorie C, Kau CH, Richmond S. Reproducibility of adult facial morphology. In: *Joint Meeting of the Continental European (CED) and the Scandinavian (NOF) Divisions of IADR*, Amsterdam; 2005.
49. Bailey LJ, Cevidanes LH, Proffit WR. Stability and predictability of orthognathic surgery. *Am J Orthod Dentofacial Orthop* 2004;**126**:273–7.

Copyright of *Orthodontics & Craniofacial Research* is the property of Blackwell Publishing Limited and its content may not be copied or emailed to multiple sites or posted to a listserv without the copyright holder's express written permission. However, users may print, download, or email articles for individual use.