

AM Toma
A Zhurov
R Playle
E Ong
S Richmond

Reproducibility of facial soft tissue landmarks on 3D laser-scanned facial images

Authors' affiliation:

A.M. Toma, A. Zhurov, R. Playle, E. Ong,
S. Richmond, Department of Applied Clinical
Research & Public Health (Orthodontic
Department), Cardiff University Dental
Hospital, Heath Park, Cardiff, CF14 4XY,
Wales, UK

Correspondence to:

Arshed M. Toma
Department of Applied Clinical Research &
Public Health/Orthodontic Department
Cardiff University Dental Hospital – 1st
Floor, Graduate Room
Heath Park, Cardiff,
CF14 4XY, Wales
UK
E-mail: tomaa@cardiff.ac.uk,
arshedtoma@gmail.com

Structured Abstract

Authors – Toma AM, Zhurov A, Playle R, Ong E, Richmond S

Background – The three-dimensional (3D) measuring technology is useful to inspect facial shape in three planes of space (X, Y, and Z). Recent work has been directed to analyse craniofacial morphology using facial soft tissue landmarks to identify facial differences among population. The reproducibility of facial landmarks is almost necessary to ensure accurate 3D facial measurements.

Objective – The aim of this study is to assess the reproducibility of facial soft tissue landmarks using laser-scan 3D imaging technology.

Subjects and Methods – Facial landmarks were assessed for 30 15½-year-old British-Caucasian children (15 males and 15 females). The sample was recruited from the Avon Longitudinal Study of Parents and Children (ALSPAC). The 3D facial images were acquired for each subject using two high-resolution Konica/Minolta laser scanners. Twenty-one facial landmarks (63 X, Y, and Z coordinates) were identified and recorded on each 3D facial image by two examiners. The reproducibility of landmarks identification at 2-week interval was assessed for one of the examiners (intra-examiner). In addition, the reproducibility of landmarks was assessed between the two examiners (inter-examiner). Using Bland-Altman plots, both intra- and inter-examiner assessments had evaluated landmarks reproducibility in three dimensions for the sample divided by gender. The reproducibility of the 3D-coordinates for each landmark was considered under three categories (<0.5 mm, < 1 mm, and > 1 mm) for both intra- and inter-examiner reproducibility assessments.

Results – The distribution of coordinates at the three levels of reproducibility show the following percentages: intra-examiner: <0.5 mm (38%), < 1 mm (51%), > 1 mm (11%); inter-examiner: <0.5 mm (35%), < 1 mm (48%), > 1 mm (17%). Generally, 10 landmarks were reproducible to less than 1 mm for both intra- and inter-examiner reproducibility assessments. The Labiale Superius was the most reproducible and Palebrale Superius was the least reproducible landmark. Some landmarks showed greater reliability in certain planes of space; the Glabella was more reliable in the Z than the Y axis. Gender differences were found; Subnasale was more reproducible in the Y-axis in males compared with females.

Conclusions – The reproducibility of facial landmarks should be considered in the three planes of space. The majority of X-Y-Z coordinates taken to the 21 facial landmarks were reproducible to < 1 mm which is clinically acceptable. The accuracy of landmarks identification ranged from 0.39 to 1.49 mm. The reliability in identification depends on the clarity and definition of each landmark as well as

Dates:

Accepted 8 November 2008

To cite this article:

Toma AM, Zhurov A, Playle R, Ong E, Richmond S:
Reproducibility of facial soft tissue landmarks on
3D laser-scanned facial images
Orthod Craniofac Res 2009;12:33–42

gender characteristics. The different landmarks reproducibility should be considered when evaluating changes related to growth and healthcare interventions.

Key words: ALSPAC; Bland-Altman plots; facial landmarks; reproducibility; three-dimensional imaging

Introduction

Our understanding of facial growth and shape is improving with the development of accurate three-dimensional (3D) acquisition systems. The emergence of 3D imaging technologies in the 1970s and 1980s facilitated realistic interactive surgical planning (1, 2). Attention was given to the field of facial reconstructive surgery, where the final result has a direct effect on patient appearance. The recent innovations in this field have led to the development of non-invasive, optically based, 3D digitization techniques (3–5).

The most popular 3D data acquisition technique that has been successfully applied to human facial measurement is laser surface scanning (6). This technique involves projecting a stripe of laser light onto the object of interest and viewing its contour from an offset camera. The laser scanner is a valuable tool because of its ease of application and creation of accurate 3D images. The scanned images can be used to create valuable resources for normative populations (7); cross-sectional growth changes (8); clinical outcomes in the surgical and non-surgical treatments in the head and neck regions (9, 10).

Two-dimensional cephalometric radiographs record mainly hard tissue information. Today, the paradigm of our treatment goals has shifted from hard to soft tissue (11). This shift requires using novel approaches for 3D imaging and creative diagnostic methods.

One of these methods includes the use of facial soft tissue landmarks to identify facial differences among various groups of population (12–15). Accurate placement of these landmarks on the 3D facial scans is important to ensure accurate facial measurements which could be useful in identifying facial shape variation.

Several studies (16–19) had investigated the reproducibility of facial landmarks on the 3D facial scans. Each study has its own method of scanning and visualizing the face in the three dimensions of space with inherent advantages and disadvantages.

In this study, the reproducibility of identifying different facial soft tissue landmarks on the 3D facial scans was assessed using a laser-based acquisition system and a new statistical approach to conduct the results.

Subjects and methods

This study was undertaken on 30 British-Caucasian children aged 15½ years, divided into 15 males and 15 females. The sample was recruited from the Avon Longitudinal Study of Parents and Children – ALSPAC (20). Ethical approval for this study was obtained from the ALSPAC Law and Ethics Committee and the Local Research Ethics Committees.

Three-dimensional facial images were captured using two high-resolution Konica Minolta Vivid (VI900) cameras (Konica Minolta Sensing Europe Company, Milton Keynes, UK). The 3D cameras were fitted with lenses of focal length 14.5 mm and were connected in serial via a Small Computer System Interface (SCSI) cable to a desktop computer workstation (Dell 8200 Inspiron with 2 GHz Pentium 4 Processor; DELL Company, Bracknell, UK). The left and right facial images of each scanned subject were processed, registered and merged using a locally developed subroutine in RAPIDFORM™ Software (RF6; INUS Technology Inc., Seoul, South Korea) (21–24). This subroutine was utilized also to standardize automatically the 3D facial images within the reference framework by orienting each 3D facial shell in the three planes of space (X, Y, and Z) using three reference planes: sagittal (Y-Z plane), coronal (X-Y plane), and transverse (X-Z plane). These planes were basically referenced to the mid-intercanthal point (origin) as this point has shown to be most stable with the growth of the face. The sagittal plane was referenced to this point running through the midline of the face, the coronal plane was established as average Natural Head Posture (NHP), and the transverse plane was established across the inner

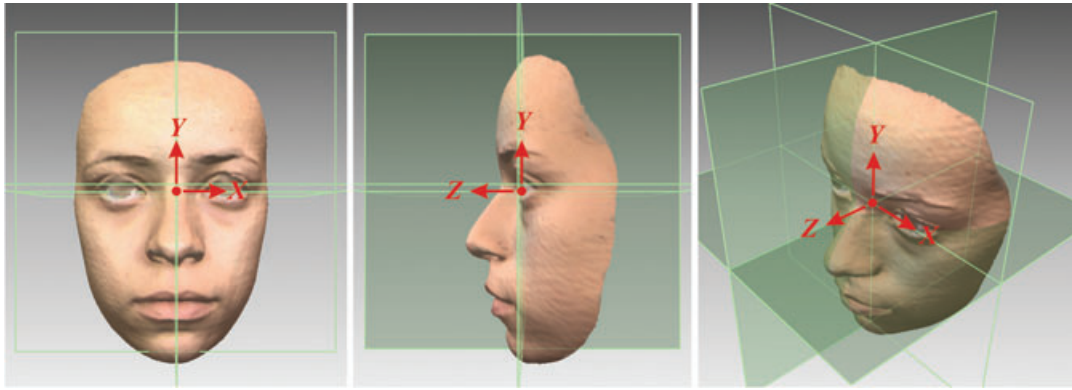


Fig. 1. Standardizing the 3D facial images in the three planes of space.

canthi points, as shown in Fig. 1. This is a crucial step to standardize the 3D facial images in the three planes of space so that we can get comparable X, Y, and Z coordinates to be assessed for reproducibility of the facial landmarks (25).

Twenty-one facial landmarks as defined by Farkas (26) were placed manually on the 3D facial images (Fig. 2) and the X, Y, and Z coordinates for each landmark were recorded by two examiners (63 coordinates in total).

The selected landmarks represent those used most commonly in the previous studies of 3D facial imaging. Accurate landmarks identification requires full 3D control by the operator in changing the perspective and magnifying the images in order to correctly identify the landmarks on the 3D facial scans.

The reproducibility of landmarks identification at 2-week interval was assessed for one of the examiners (intra-examiner). In addition, the reproducibility of landmarks was assessed between the two examiners (inter-examiner). Using Bland-Altman plots (27), both intra- and inter-examiner assessments had evaluated landmarks reproducibility in three dimensions for the sample divided by gender.

The errors in landmark identification were expressed as a distance between two points (incorporation differences in X, Y, and Z) and broken down further for errors in each axis. The errors were categorized accordingly: <0.5 mm, <1 mm, and >1 mm.

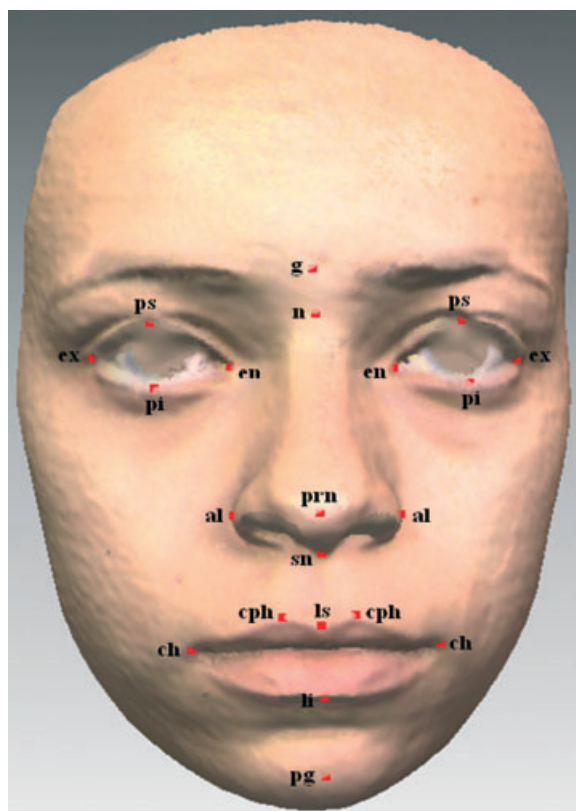
Results

The Bland-Altman plots were used to illustrate the level of agreement between readings taken for each

3D-coordinate (X, Y, and Z) of the 21 facial landmarks. These plots were conducted for both, intra- and inter-examiner reproducibility assessments. For each Bland-Altman plot, the difference between readings for each landmark-coordinate was calculated and plotted against the average of the readings for that particular coordinate.

Some examples are given in Fig. 3 for coordinates of selected landmarks to illustrate the high, moderate, and lower levels of agreement between readings taken for the coordinates at different occasions.

- Figure 3a shows an example for Bland-Altman plot obtained to assess the reproducibility of the landmark Glabella (g) in the Z-plane for the 15 males involved in the intra-examiner reproducibility assessment. The vertical axis of this plot shows the difference between readings taken for the landmark Glabella for each of the 15 subjects; whereas the horizontal axis shows the average of the readings. The (zero) line refers to subjects where the difference between readings equal to zero (highest reproducibility). The dotted lines (arrows) refer to subjects where maximum difference exhibit between the readings. This plot shows the coordinate (Glabella, Z) has high reproducibility, as the difference between readings for all subjects was <0.5 mm.
- Figure 3b shows another example for Bland-Altman plot obtained to assess the reproducibility of the landmark Alare/Right in the Y-plane for the 15 males involved in the inter-examiner reproducibility assessment. This plot shows the coordinate (Alare/Right, Y) has moderate reproducibility, as the difference between readings for some subjects exceeds 0.5 mm, but still less than 1 mm.



Landmarks

- Glabella (g)
- Nasion (n)
- Endocanthion (en) L/R
- Exocanthion (ex) L/R
- Palpebrale superius (ps) L/R
- Palpebrale inferius (pi) L/R
- Pronasale (prn)
- Subnasale (sn)
- Alare (al) L/R
- Labiale superius (ls)
- Labiale inferius (li)
- Crista philtri (cph) L/R
- Cheilion (ch) L/R
- Pogonion (pg)

Definition

- Most prominent midline point between eyebrows
- Deepest point of nasal bridge
- Inner commissure of the left and right eye fissure
- Outer commissure of the left and right eye fissure
- Superior mid-portion of the free margin of upper left and right eyelids
- Inferior mid-portion of the free margin of lower left and right eyelids
- Most protruded point of the apex nasi
- Mid-point of angle at columella base
- Most lateral point on left and right alar contour
- Mid-point of the upper vermillion line
- Mid-point of the lower vermillion line
- Point on left and right elevated margins of the philtrum just above VL
- Point located at left and right labial commissure
- Most anterior mid-point of the chin

Fig. 2. Facial soft tissue landmarks.

- Figure 3c shows another example for Bland-Altman plot obtained to assess the reproducibility of the landmark Palpebrale Superius/Right in the X-plane for the 15 females involved in the inter-examiner reproducibility assessment. This plot shows the coordinate (Palpebrale Superius/Right, X) has poor reproducibility, as the difference between readings for three subjects exceeds 1 mm, however, the majority of the subjects are within 0.5 mm.

Generally, the Bland-Altman Plots have shown that:

- The coordinates, where differences between readings for all subjects were less than 0.5 mm, have been classified as ‘Highly Reproducible’ coordinates, whereas;
- The coordinates, where differences between readings for some subjects were more than 0.5 mm but less than 1 mm, considered as being ‘Moderately Reproducible’ coordinates; and

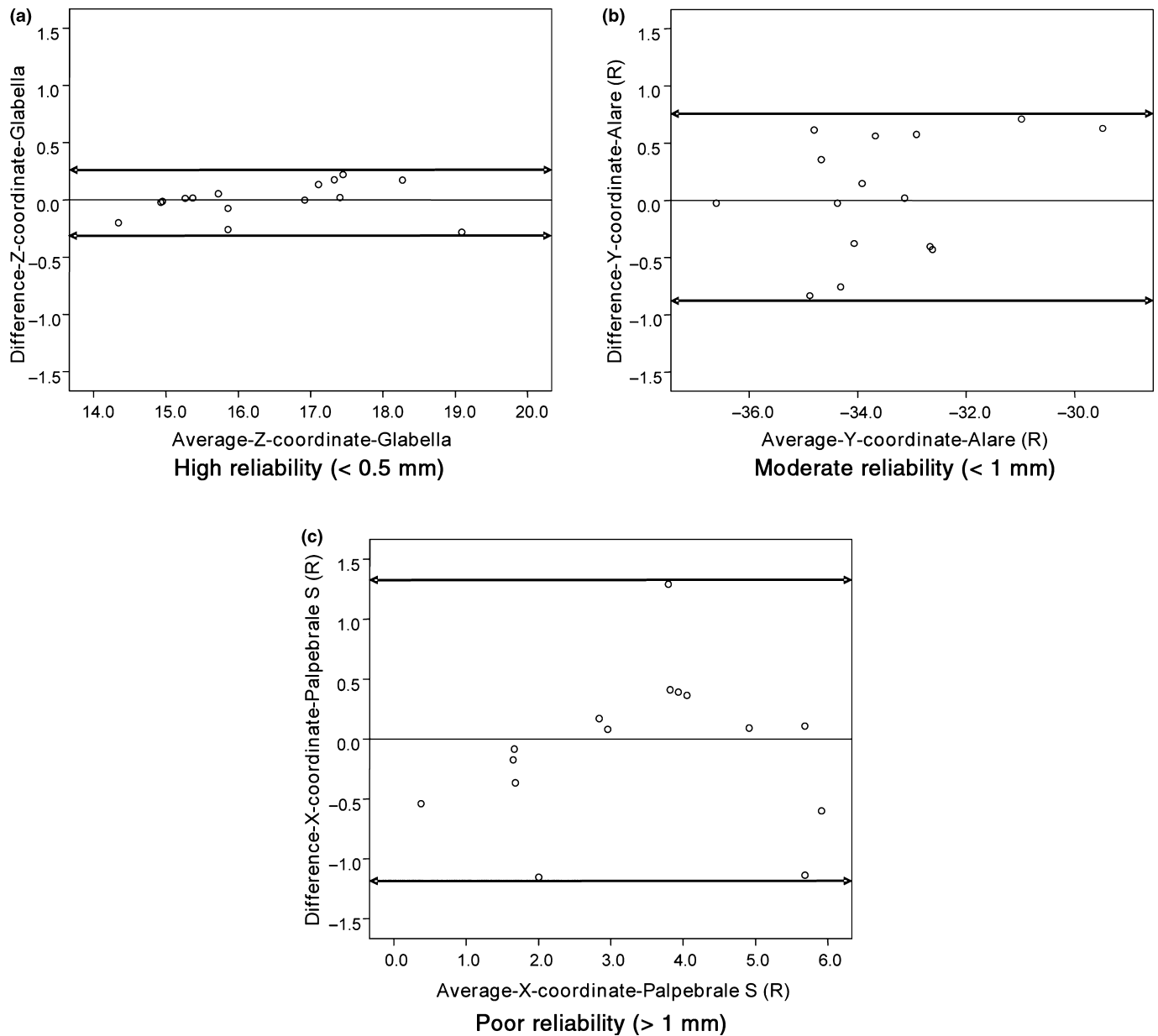


Fig. 3. Reproducibility of landmarks identification (Bland-Altman plots).

Table 1. Reproducibility of landmarks identification (total sample)

Method of assessment	Intra-examiner (n = 30)			Inter-examiner (n = 30)		
	<0.5	<1	>1	<0.5	<1	>1
Reproducibility level (mm)						
Number of coordinates	24	32	7	22	30	11
Percentages	38	51	11	35	48	17

Total number of coordinates = 63.

- The coordinates, where differences between readings for some subjects show values greater than 1 mm, were considered as having 'Poor reproducibility'.

Table 1 shows the results obtained for the intra- and inter-examiner reproducibility assessments for the total sample (30 subjects). Numbers and percentages were given for the 3D-coordinates showing the reproducibility at the three levels (<0.5 mm, <1 mm, and >1 mm).

The majority of coordinates were reproducible to less than 1 mm (intra-examiner 51%, and inter-examiner 48%). The highest reproducibility (<0.5 mm) coordi-

nates form 38% (intra-examiner) and 35% (inter-examiner). The poorest reproducibility (>1 mm) coordinates constitute 11% (intra-examiner) and 17% (inter-examiner).

The intra- and inter-examiner reproducibility of landmarks identification in respect to the three planes of space are detailed further in Table 2 for the sample divided by gender (15 males and 15 females).

Table 2 shows the following findings:

- Poorer reproducibility was noticed more in the inter-examiner reproducibility assessment than intra-examiner reproducibility assessment, and in females more than males especially for those landmarks related to the eyes.
- Other coordinates showing poor reproducibility were noticed in both, intra- and inter-examiner reproducibility assessment, include: 1) Glabella (g) and Nasion (n) in the Y-axis; 2) left and right Alare (al) in the Z-axis.
- The chin point Pogonion (pg) in the Y-axis was noticed to have poor reproducibility in the inter-examiner reproducibility assessment, only.
- Subnasale (sn) in the Y-axis was more reproducible in males than females for the intra-examiner reproducibility assessment.
- Other landmarks, identifying the lips and mouth, were noticed to have higher reproducibility in females than males for the intra-examiner reproducibility assessment, these include: 1) labiale inferius (li) in the Y- and Z-axis; 2) left and right cheilion (ch) in the Y-axis.

Table 3 ranks the landmarks from the most reproducible to the least reproducible for both intra- and inter-examiner reproducibility assessments. Each landmark was assessed according to the differences in readings taken at different occasions for the X, Y, and Z coordinates, using the following equation:

$$D = \sqrt{(\Delta x)^2 + (\Delta y)^2 + (\Delta z)^2}$$

where D is total distance, Δx is difference in the X-axis, Δy is difference in the Y-axis and Δz is difference in the Z-axis.

For each landmark, an average and standard deviation were calculated for the total sample (30 subjects) for both intra- and inter-examiner assessments. Gen-

erally, the accuracy of different landmarks identification ranged from 0.39 to 1.49 mm. Ten landmarks were reproducible to less than 1 mm for both intra- and inter-examiner assessments.

The landmark labiale superius (ls) was the most reproducible landmark (<0.5 mm) for both intra- and inter-examiner assessments. The landmarks: crista philtri (cph), labiale inferius (li), subnasale (sn), pronasale (prn), cheilion (ch), and palpebrale inferius (pi) followed with averages less than 1 mm for both intra- and inter-examiner assessments. The rest of landmarks: alare (al), nasion (n), glabella (g), exocanthion (ex), and palpebrale superius (ps) followed with averages more than 1 mm for both intra- and inter-examiner assessments. The landmark palpebrale superius (ps) was the least reproducible landmark.

Some landmarks showed differences in their reproducibility between intra- and inter-examiner assessments, these include: endocanthion (en) and pogonion (pg) which were moderately reproducible (<1 mm) in the intra-examiner assessment and poorly reproducible (>1 mm) in the inter-examiner assessment.

Discussion

The reproducibility of facial soft tissue landmarks has been studied at length in two dimensions through the role of cephalometrics in orthodontics for the purposes of determining aetiology, diagnosis, treatment planning and outcome assessment. However, as the face is a 3D structure, the need to record its position in three dimensions has been highlighted (28). The current study investigated the reproducibility of various soft tissue landmarks identified on the 3D facial images of our sample. The results show variation among the various landmarks placed on the face according to the following criteria:

1. Good description/definition of each landmark.
2. Morphology, distinctive features and gender influences. A landmark associated with a point like labiale superius (ls) and crista philtri (cph) is more likely to produce less error compared with landmark placed on a flat surface like glabella (g) and alare (al).
3. Examiner factors: e.g. visual acuity, discipline, organization skills and ability to identify landmarks according to the definition.

Table 2. Reproducibility of landmarks identification (sample divided by gender)

Intra-examiner						Inter-examiner					
Females (n = 15)			Males (n = 15)			Females (n = 15)			Males (n = 15)		
< 0.5 mm (n = 27)	< 1 mm (n = 28)	> 1 mm (n = 8)	< 0.5 mm (n = 22)	< 1 mm (n = 35)	> 1 mm (n = 6)	< 0.5 mm (n = 22)	< 1 mm (n = 28)	> 1 mm (n = 13)	< 0.5 mm (n = 22)	< 1 mm (n = 31)	> 1 mm (n = 10)
gZ	gX	gY	gZ	gX	gY	gZ	gX	gY	gZ	gX	gY
nZ	nX	nY	nX	enLY	nY	nZ	nX	nY	nZ	nX	nY
psLZ	enLX	exLY	nZ	enLZ	psLY	psLZ	enLX	enRX	enRY	enLX	enLZ
psRZ	enLY	psLX	enLX	enRX	psRY	psRZ	enLY	exLX	piRZ	enLY	exLX
piLZ	enLZ	psLY	enRY	enRZ	alLZ	piLZ	enLZ	exLZ	prnX	enRX	exRX
piRZ	enRX	psRY	piRZ	exLX	alRZ	piRZ	enRY	exRX	prnZ	enRZ	psLY
prnX	enRY	alLZ	prnZ	exLY		prnZ	enRZ	psLY	snX	exLY	psRX
prnZ	enRZ	alRZ	snX	exLZ		snX	exLY	psRX	snZ	exLZ	alLZ
snX	exLX		snY	exRX		snZ	exRY	psRY	alLX	exRY	alRZ
snZ	exLZ		snZ	exRY		alLX	exRZ	piRX	alRX	exRZ	pgY
alLX	exRX		alLX	exRZ		alRX	psLX	alLZ	lsX	psLX	
alRX	exRY		alRX	psLX		lsX	piLX	alRZ	lsY	psLZ	
lsX	exRZ		lsX	psLZ		lsY	piLY	pgY	lsZ	psRY	
lsY	psRX		lsY	psRX		lsZ	piRY		liX	psRZ	
lsZ	piLX		lsZ	psRZ		liZ	prnX		cphLY	piLX	
liX	piLY		liX	piLX		cphLY	prnY		cphLZ	piLY	
liY	piRX		cphLY	piLY		cphLZ	snY		cphRY	piLZ	
liZ	piRY		cphLZ	piLZ		cphRY	alLY		cphRZ	piRX	
cphLY	prnY		cphRZ	piRX		cphRZ	alRY		chLZ	piRY	
cphLZ	snY		chLZ	piRY		chLY	liX		chRY	prnY	
cphRY	alLY		chRZ	prnX		chLZ	liY		chRZ	snY	
cphRZ	alRY		pgZ	prnY		pgZ	cphLX		pgZ	alLY	
chLY	cphLX		alLY				cphRX			alRY	
chLZ			alRY				chLX			liY	
chRY	cphRX		liY				chRX			liZ	
chRZ			liZ				chRY			cphLX	
pgZ	chLX		cphLX				chRZ			cphRX	
	chRX		cphRX				pgX			chLX	
	pgX		cphRY							chLY	
	pgY		chLX							chRX	
			chLY							pgX	
			chRX								
			chRY								
			pgX								
			pgY								

g, glabella; n, nasion; ps, palpebrale superius; pi, palpebrale inferius; prn, pronasale; sn, subnasale; al, alare; ls, labiale superius; li, labiale inferius; cph, crista philtri; ch, cheilion; pg, pogonion; en, endocanthion; ex, exocanthion; L, left; R, right; X, X-axis; Y, Y-axis; Z, Z-axis.

Code: Landmark abbreviation + side of the face (if applicable) + plane axis.

High reproducibility (< 0.5 mm); moderate reproducibility (< 1 mm); poor reproducibility (> 1 mm).

Table 3. Ranking of facial soft tissue landmarks in respect to their reproducibility assessment in the three planes of space

Rank	Intra-examiner (n = 30)			Inter-examiner (n = 30)		
	Landmark	Average	SD	Landmark	Average	SD
1	ls	0.39	0.22	ls	0.42	0.26
2	cphL	0.56	0.28	cphL	0.55	0.42
3	cphR	0.60	0.45	cphR	0.61	0.35
4	li	0.60	0.44	sn	0.64	0.34
5	sn	0.65	0.32	prn	0.73	0.38
6	prn	0.77	0.44	li	0.76	0.45
7	chL	0.83	0.54	chL	0.76	0.35
8	enL	0.83	0.46	chR	0.81	0.44
9	pg	0.87	0.46	piL	0.94	0.49
10	piL	0.91	0.43	piR	0.97	0.41
11	enR	0.96	0.57	enL	1.03	0.65
12	piR	1.07	0.55	alR	1.04	0.55
13	chR	1.11	0.59	enR	1.06	0.89
14	n	1.11	0.79	alL	1.11	0.70
15	alR	1.17	0.67	g	1.20	0.74
16	alL	1.20	0.76	exL	1.23	0.72
17	exL	1.21	1.22	exR	1.27	0.62
18	g	1.27	0.68	n	1.27	0.83
19	psL	1.30	1.08	pg	1.34	0.74
20	exR	1.33	0.74	psL	1.34	0.99
21	psR	1.49	1.05	psR	1.42	0.89

g, glabella; n, nasion; ps, palpebrale superius; pi, palpebrale inferius; prn, pronasale; sn, subnasale; al, alare; ls, labiale superius; li, labiale inferius; cph, crista philtri; ch, cheilion; pg, pogonion; en, endocanthion; ex, exocanthion; L, left; R, right; SD, standard deviation.

4. High quality display of images to adjust perspective and magnification to locate the appropriate landmarks positions on the face.
5. The three planes of space (X, Y, and Z) identifying the exact position for each particular landmark on the face.

The reproducibility of facial soft tissue landmarks has been considered in the three planes of space. The majority of X-Y-Z coordinates taken to the 21 facial landmarks were reproducible to less than 1 mm which is clinically acceptable (51% intra-examiner and 48% inter-examiner).

Most of those coordinates with poor reproducibility were associated with the eyes because this area with its complex geometry was difficult to capture using a laser-based acquisition system which may affect the

mesh production during the computerized processing of the 3D facial images; therefore, in some cases the image 'wire framework' showed large polygons, and landmarks placed on these areas will not be as specific as those placed in areas of high-density wire polygons, which may be reflected on the degree of reproducibility exhibited by landmarks being identified on those processed areas of the 3D facial image. Therefore, precautions should be taken in the computerized processing of these areas of the face so that complete dense mesh production can be achieved, making the identification of landmarks more accurate and reproducible.

Those landmarks with relatively poor reproducibility in the Y-axis (glabella, nasion, and pogonion) were mainly due to the difficulty of placing those points accurately with the patient in a NHP in lateral profile. This requires good manipulation skills in order to move the image to the correct position and also a good clinical knowledge of NHP. Failing to achieve this may mean that such points will be placed either too high or too low vertically. However, in the X- and Z-axis, the reproducibility was much better.

Some coordinates showed variation between females and males. The landmark Subnasale in the Y-axis was relatively more reproducible in males than females for the intra-examiner reproducibility assessment only. This is due to the fact that where 'nasolabial angle' is found with curved contour, locating the point can be quite difficult. This angle should ideally be about 100–110° for a woman and 90–100° for a man. In our sample, the nasolabial angle was also smaller in males than females which made it easier to identify the point Subnasale in the Y-axis. Females tend to exhibit well-defined lips and mouth borders compared to males and consequently make it easier to record the landmarks: labiale inferius (li) in the Y- and Z-axis; left and right cheilion (ch) in the Y-axis.

Labiale superius (ls) was the most reproducible landmark in respect to the three planes of space (X-Y-Z), this was due to the well-defined contours at this area of the upper lip make it easier to identify the exact position of this point on the face. Palpebrale superius (ps) was the least reproducible landmark on the face because of the difficulty in identifying upper eyelid borders which in some images were affected by computerized processing of the 3D facial image, resulting in poor mesh production at this area of the face. Gener-

ally, the results and findings conducted in this study were nearly similar to previous studies (16–19) using different approaches.

Conclusions

- To be of clinical use, the reproducibility of each landmark must be assessed in all three planes of space (X, Y, and Z).
- Reproducibility of the facial landmarks varies depending upon the landmark being placed and the method of reproducibility assessment whether intra- or inter-examiner assessment. For good reproducibility, landmarks must be well defined and clearly understood by the assessors placing the landmarks.
- Different facial landmarks have wide variation in their degree of reproducibility. Landmarks placed on well-defined borders showed higher degrees of reproducibility than those placed on gently curving slopes. This may have association to gender differences in facial morphology that can affect the identification of certain landmarks.
- It is important to become familiar with the software program used to view and process the 3D facial images in order to improve landmarks reproducibility.
- The majority of the X, Y, and Z coordinates taken to the 21 facial landmarks were reproducible to less than 1 mm which is clinically acceptable (51% intra-examiner and 48% inter-examiner). The accuracy of landmarks identification generally ranged from 0.39 to 1.49 mm.
- The different landmarks reproducibility should be considered when evaluating changes related to growth and healthcare interventions.

Clinical relevance

The 3D imaging has many applications in health care with particular applications in craniofacial growth, orthodontic/orthognathic planning and assessment of treatment outcomes. In common with all techniques, it is important to ensure that landmarks can be reproduced over time so that valid comparisons can be

made. This study highlights certain facial landmarks are more reproducible than others.

Acknowledgements: The authors are extremely grateful to all the families who took part in this study, the midwives for their help in recruiting them, and the whole ALSPAC team, which includes interviewers, computer and laboratory technicians, clerical workers, research scientists, managers, receptionists and nurses. The UK Medical Research Council, the Wellcome Trust and the University of Bristol provide core support for ALSPAC. This publication is the work of the authors (Arshed M. Toma, Alexei Zhurov, Rebecca Playle, Egle Ong, and Stephen Richmond) and will serve as guarantors for the contents of this paper.

References

1. Brewster U, Trivedi SS, Tuy HK, Udupa JK. Interactive surgical planning. *IEEE Comput Graph* 1984;4:31–40.
2. Moss JP, Grindrod SR, Linney AD, Arridge SR, James D. A computer system for the interactive planning and prediction of maxillofacial surgery. *Am J Orthod Dentofacial Orthop* 1988;94:469–75.
3. Marshall SJ, Rixon RC, Whiteford DN, Cumming JT. The OrthoForm 3-Dimensional Clinical Facial Imaging System. *Proceedings of the 15th IFHE Congress* 1998;15:83–7.
4. McCance AM, Moss JP, Fright WR, James DR, Linney AD. A three dimensional analysis of soft and hard tissue changes following bimaxillary orthognathic surgery in skeletal III patients. *Br J Oral Maxillofac Surg* 1992;30:305–12.
5. McCance AM, Moss JP, Wright WR, Linney AD, James DR. A three-dimensional soft tissue analysis of 16 skeletal class III patients following bimaxillary surgery. *Br J Oral Maxillofac Surg* 1992;30:221–32.
6. Arridge S, Moss JP, Linney AD, James DR. Three-dimensional digitization of the face and skull. *J Maxillofac Surg* 1985;13: 136–43.
7. Yamada T, Mori Y, Minami K, Mishima K, Tsukamoto Y. Three-dimensional analysis of facial morphology in normal Japanese children as control data for cleft surgery. *Cleft Palate Craniofac J* 2002;39:517–26.
8. Nute SJ, Moss JP. Three-dimensional facial growth studied by optical surface scanning. *J Orthod* 2000;27:31–8.
9. Ayoub AF, Siebert P, Moos KF, Wray D, Urquhart C, Niblett TB. A vision-based three-dimensional capture system for maxillofacial assessment and surgical planning. *Br J Oral Maxillofac Surg* 1998;36:353–7.
10. Moss JP, Ismail SF, Hennessy RJ. Three-dimensional assessment of treatment outcomes on the face. *Orthod Craniofac Res* 2003;6(Suppl. 1):126–31.
11. Proffit WR, White RP, Sarver DM. *Contemporary Treatment of Dentofacial Deformity*. St. Louis: CV Mosby Co; 2003.
12. Hennessy RJ, Kinsella A, Waddington JL. 3D laser surface scanning and geometric morphometric analysis of craniofacial shape as an index of cerebro-craniofacial morphogenesis: initial application to sexual dimorphism. *Biol Psychiatry* 2002;51:507–14.

13. Hennessy RJ, Lane A, Kinsella A, Larkin C, Waddington J. 3D morphometrics analysis of craniofacial dysmorphology reveals sex-specific asymmetries in schizophrenia. *Schizophr Res* 2004;67:261–8.
14. Hennessy RJ, McLearn S, Kinsella A, Waddington JL. Facial surface analysis by 3D laser scanning and geometric morphometrics in relation to sexual dimorphism in cerebral – craniofacial morphogenesis and cognitive function. *J Anat* 2005;207:283–95.
15. Hammond P, Hutton TJ, Allanson JE, Campbell LE, Hennekam R, Holden S et al. 3D analysis of facial morphology. *Am J Med Genet Part A* 2004;126:339–48.
16. Hajeer MY, Ayoub AF, Millett DT, Bock M, Siebert JP. Three-dimensional imaging in orthognathic surgery: the clinical application of a new method. *Int J Adult Orthodon Orthognath Surg* 2002;17:318–30.
17. Gwilliam JR, Cunningham SJ, Hutton T. Reproducibility of soft tissue landmarks on three-dimensional facial scans. *Eur J Orthod* 2006;28:408–15.
18. Baik HS, Lee HJ, Lee KJ. A proposal for soft tissue landmarks for craniofacial analysis using 3-dimensional laser scan imaging. *World J Orthod* 2006;7:7–14.
19. Coward TJ, Watson RM, Scott BJJ. Laser scanning for the identification of repeatable landmarks of the ears and face. *Br J Plast Surg* 1997;50:308–14.
20. Golding J, Pembrey M, Jones R, Team AS. ALSPAC – the Avon Longitudinal Study of Parents and Children-Study methodology. *Paediatr Perinat Epidemiol* 2001;15:74–87.
21. Kau CH, Zhurov A, Scheer R, Bouwman S, Richmond S. The feasibility of measuring 3D facial morphology in children. *Orthod Craniofac Res* 2004;7:198–204.
22. Kau CH, Zhurov A, Bibb R, Hunter L, Richmond S. The investigation of the changing facial appearance of identical twins employing a three-dimensional laser imaging system. *Orthod Craniofac Res* 2005;8:85–90.
23. Toma AM, Zhurov A, Playle R, Richmond S. A three-dimensional look for facial differences between males and females in a British-Caucasian sample aged 15½ years old. *Orthod Craniofac Res* 2008;11:180–5.
24. Zhurov A, Kau CH, Richmond S. Computer methods for measuring 3D facial morphology. In: Middleton J, Shrive MG, Jones ML, editors. *Computer Methods in Biomechanics and Biomedical Engineering-5*. Cardiff: First Numerics Ltd; 2005. pp. 2–7 (ISBN 0-9549670-0-3).
25. Toma AM. *A three-dimensional analysis of facial morphology using laser-scan imaging technology*. Thesis (MPhil). Wales, UK: Applied Clinical Research and Public Health, Dental School, Cardiff University; 2007.
26. Farkas LG. *Anthropometry of the Head and Face*, 2nd edn. New York: Raven Press; 1994.
27. Bland JM, Altman DG. Statistical methods for assessing agreement between two methods of clinical measurement. *Lancet* 1986;1:307–10.
28. Ferrario VF, Sforza C, Poggio CE, Serrao G. Facial three-dimensional morphometry. *Am J Orthod Dentofacial Orthop* 1996;109:86–93.

Copyright of *Orthodontics & Craniofacial Research* is the property of Blackwell Publishing Limited and its content may not be copied or emailed to multiple sites or posted to a listserv without the copyright holder's express written permission. However, users may print, download, or email articles for individual use.