

JR Lewis  
AM Reiter  
EA Mauldin  
ML Casal

## Dental abnormalities associated with X-linked hypohidrotic ectodermal dysplasia in dogs

### Authors' affiliations:

J.R. Lewis, A.M. Reiter, Assistant Professor of Dentistry and Oral Surgery, Department of Clinical Studies, Matthew J. Ryan Veterinary Hospital, University of Pennsylvania, Philadelphia, PA, USA

E.A. Mauldin, Assistant Professor of Dermatopathology, University of Pennsylvania School of Veterinary Medicine, Laboratory of Pathobiology and Toxicology, Philadelphia, PA, USA

M.L. Casal, Assistant Professor of Medical Genetics, Department of Clinical Studies, Matthew J. Ryan Veterinary Hospital, University of Pennsylvania, Philadelphia, PA, USA

### Correspondence to:

John R. Lewis  
Assistant Professor of Dentistry and Oral Surgery  
Department of Clinical Studies  
Matthew J. Ryan Veterinary Hospital  
University of Pennsylvania  
3900 Delancey Street  
Philadelphia, PA 19104-6010  
USA  
E-mail: jrlewis@vet.upenn.edu

### Structured Abstract

**Authors** – Lewis JR, Reiter AM, Mauldin EA, Casal ML

**Objectives** – X-linked hypohidrotic ectodermal dysplasia (XLHED) occurs in several species, including humans, mice, cattle and dogs. The orofacial manifestations of ectodermal dysplasia in humans and mice have been extensively studied, but documentation of dental abnormalities in dogs is lacking. The current study describes the results of clinical and radiographic examinations of XLHED-affected dogs and demonstrates profound similarities to findings of XLHED-affected humans.

**Setting and sample population** – Section of Medical Genetics at the University of Pennsylvania, School of Veterinary Medicine. Clinical and radiographic oral examinations were performed on 17 dogs with XLHED, three normal dogs, and two dogs heterozygous for XLHED.

**Materials and methods** – The prevalence and severity of orofacial and dental abnormalities were evaluated by means of a sedated examination, photographs, and full-mouth intraoral radiographs.

**Results** – Crown and root abnormalities were common in dogs affected by XLHED, including hypodontia, oligodontia, conical crown shape, decreased number of cusps, decreased number of roots, and dilacerated roots. Persistent deciduous teeth were frequently encountered. Malocclusion was common, with Angle Class I mesioversion of the maxillary and/or mandibular canine teeth noted in 15 of 17 dogs. Angle Class III malocclusion (maxillary brachygnathism) was seen in one affected dog.

**Conclusion** – Dental abnormalities are common and severe in dogs with XLHED. Dental manifestations of canine XLHED share characteristics of brachydont tooth type and diphodont dentition, confirming this species to be an orthologous animal model for study of human disease.

**Key words:** developmental abnormalities; dogs, tooth abnormalities; ectodermal dysplasia; XLHED

### Dates:

Accepted 10 September 2009

### To cite this article:

Lewis JR, Reiter AM, Mauldin EA, Casal ML:  
Dental abnormalities associated with X-linked hypohidrotic ectodermal dysplasia in dogs  
*Orthod Craniofac Res* 2010;13:40–47

© 2010 John Wiley & Sons A/S

## Introduction

X-linked hypohidrotic ectodermal dysplasia (XLHED) is a congenital disorder which has been described in humans, mice, cattle and dogs (1, 2). In affected individuals, structures of ectodermal origin may be absent or abnormally formed, including skin, lacrimal glands and teeth.

Skin lesions manifest as hairlessness and absence of eccrine sweat glands (Fig. 1). Congenital alopecia was first described in the dog in 1910 (3). X-linked recessive inheritance has been confirmed in one dog breed by pedigree analysis (4). Although dental and craniofacial abnormalities associated with XLHED have been well documented in humans (5–12) and mice (13–17), a complete description of the dental abnormalities in XLHED-affected dogs is lacking. The present study describes dental abnormalities seen in XLHED-affected dogs and compares them to those described in humans and mice.

Ectodermal dysplasia has been extensively studied in mice. Ectodysplasin (EDA) is a ligand of the tumor necrosis factor (TNF) family that binds to an EDA receptor (EDAR) and transmits an intracellular signal via an adaptor protein (EDARADD) (18). Spontaneous genetic mutations responsible for expression of these proteins have been identified in mice, resulting in mouse mutants Tabby (mutation of EDA) (19), Downless Jackson and Downless Sleek (mutation of EDAR), and Crinkled (mutation of EDARADD) (20–23). In mice, EDAR mutation results in development of fewer molar teeth than normal, and those molars present have fewer cusps. When EDA is overexpressed, supernumerary molar teeth develop with a normal number of cusps. When EDAR is overexpressed, the tooth number is variable (increased, normal or decreased), and more cusps are present on molar teeth (18). Tabby mice, the orthologue for XLHED in humans and dogs, exhibit missing molar and incisor teeth with variations in severity, and the cusps of molar teeth are reduced in size and number (24). The XLHED dogs evaluated in the present study suffer from a mutation in EDA (25).

The canine species shows great variation in head shape, ranging from brachycephalic (short, compact skull with little or no muzzle, as seen in pugs and boxers), mesaticephalic (most common skull shape seen in dogs), and dolichocephalic (seen in collies, greyhounds and other long-muzzled breeds). All dogs of the current study were of mesaticephalic skull conformation. The complete canine dentition includes three incisors, one canine tooth, four premolars and two molars in each maxillary quadrant. The mandibular quadrants each contain three incisors, one canine tooth, four premolars and three molar teeth. The mandibular incisors should be palatal to the maxillary incisors when the mouth is closed and the coronal third of the mandibular incisors rests against the cingulum of the maxillary incisors. When the mouth is closed, the mandibular canine is distal to the maxillary third incisor and mesial to the maxillary canine, without touching either of these teeth. The premolars are not in occlusion with the opposing premolar teeth, but when the mouth is closed, the maxillary premolar cusps sit in the interdental space of mandibular premolars. The term ‘carnassial’ describes the largest shearing tooth of the upper and lower jaw in dogs (maxillary fourth premolar and mandibular first molar). These teeth work together during mastication and contribute most significantly to the masticatory effort. The upper jaw is anisognathic, the maxilla being wider than the mandible. Therefore, the maxillary fourth premolar tooth normally occludes lateral (buccal) to the mandibular first molar tooth. In contrast to humans, dogs have more shearing cusps and fewer occlusal surfaces. Two maxillary and three mandibular molars of dogs have occlusal surfaces that are capable of grinding and

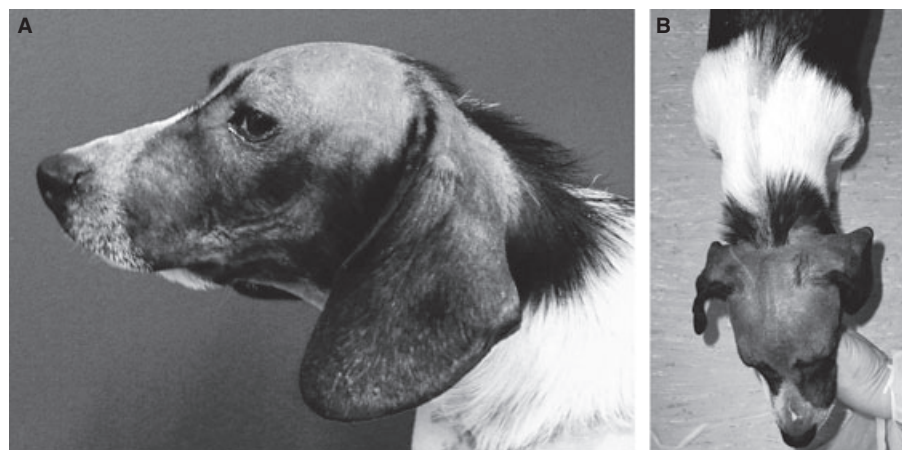


Fig. 1. (A) Typical appearance of XLHED-associated congenital alopecia in the dog, lateral view; (B) dorsal view. Note the marked alopecia of the head, ears and dorsum.

crushing hard food particles. The relative lack of occlusal surfaces partly explains the increased susceptibility of humans to pit and fissure caries compared to dogs (26, 27).

## Materials and methods

Mixed-breed dogs ranging from 2 to 12 months of age received a conscious orofacial examination. Seventeen dogs (sixteen males and one female) were XLHED-affected, nine dogs were normal controls (all male dogs), and seven dogs were heterozygous for XLHED (all female dogs). In addition to conscious orofacial examination, twenty-two dogs were sedated for full-mouth intraoral radiographs (17 affected, 2 heterozygote and 3 control dogs). All dogs were evaluated in accordance with guidelines established by an Institutional Animal Care and Use Committee (IACUC)-approved protocol. Dogs were cared for in accordance with principles outlined in the NIH Guide for the Care and Use of Laboratory Animals and in the International Guiding Principles for Biomedical Research Involving Animals. In the 22 dogs sedated for intraoral dental radiography, small-bolus intravenous administration of propofol (1–2 mg/kg) was given to effect. Prior to intravenous sedation, each dog was premedicated with butorphanol tartrate (0.2 mg/kg), acepromazine maleate (0.055 mg/kg) and atropine sulfate (0.02 mg/kg) intramuscularly, and an intravenous catheter was placed in a peripheral vein. Results of the oral examination were documented on a dental record, noting type of dentition (deciduous, mixed or permanent), presence or absence of teeth, location and position of teeth, shape of the tooth crowns,

structural crown abnormalities, presence of malocclusion, and presence of persistent deciduous teeth. Full-mouth dental radiographs were obtained using size 2 and 4 D-speed intraoral film (Kodak Ultra-speed, Rochester, NY, USA) and a wall-mounted intraoral X-ray unit (Gendex GX-770, Des Plaines, IL, USA). Radiographs were evaluated for the presence of unerupted teeth, dilacerated roots, abnormal number of roots, pulp chamber and root canal abnormalities, and classification of diminutive teeth (deciduous vs. permanent).

## Results

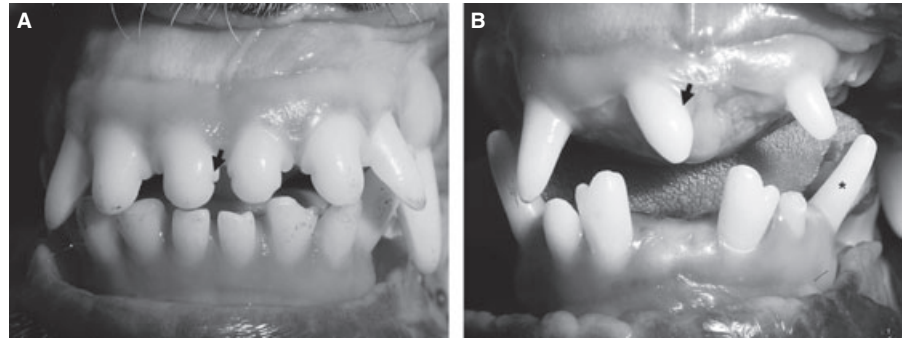
### Conscious examination

Crown morphology and positional abnormalities were seen in deciduous and permanent teeth of XLHED-affected dogs. Deciduous canine teeth were commonly persistent, resulting in crowding of the erupted permanent canine teeth in 55.0% of adult XLHED-affected dogs. Malocclusion was seen in 16 of 17 XLHED-affected dogs (94.1 %). Deciduous canine teeth often exhibited Angle class I mesioversion in dogs with XLHED. Mesioversion also occurred in permanent canine teeth (Fig. 2). Mesioversion was seen in 15 of 17 affected dogs (88.2%), compared to 2 of 7 heterozygous dogs. Two of 17 affected dogs (11.8%) exhibited labioversion of their permanent mandibular canine teeth (Fig. 3). Angle class III malocclusion (maxillary brachygnathism) was seen in one XLHED-affected dog (5.9%). Caudal crossbite (analogous to posterior crossbite in humans) was seen in two XLHED-affected dogs (11.8%). Malocclusions were not present in any of the nine normal dogs.

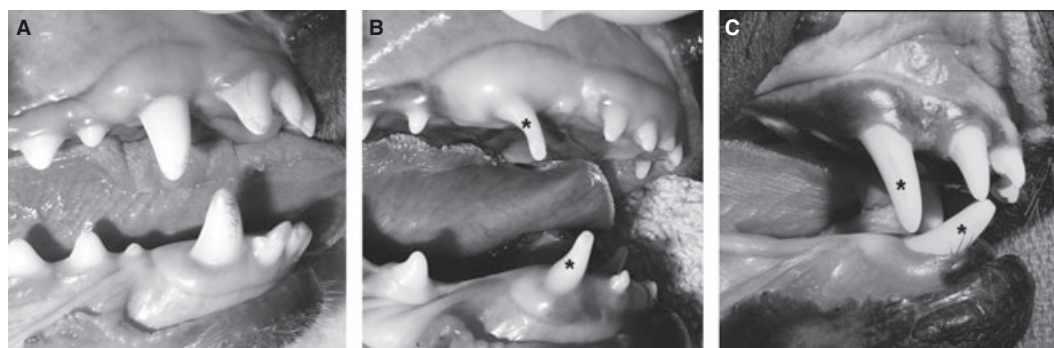

Fig. 2. (A) Canine and incisor teeth of dogs with normal permanent dentition, (B) XLHED-affected deciduous dentition, and (C) XLHED-affected permanent dentition. Note the mesioversion of both the deciduous and permanent maxillary and mandibular canine teeth (asterisks).

**Fig. 3.** (A) Comparison of incisor teeth of normal and (B) XLHED-affected permanent dentitions in the dog. The affected dog is missing multiple teeth, and some teeth are smaller than normal incisors. The number of cusps is generally reduced as seen by lack of mamelons (arrow) of the maxillary incisors. Labioversion of the left mandibular canine tooth is also present (asterisk).



Hypodontia and oligodontia were the most common dental manifestations of dogs affected with XLHED. On conscious examination, 16 of 17 XLHED-affected dogs were missing at least one permanent tooth, whereas 0 of 9 control dogs were missing permanent teeth. Premolars were the most commonly absent teeth on both the maxilla and the mandible (Table 1). In XLHED-affected dogs, incisor teeth were missing or reduced in size compared to normal permanent incisors, though still larger than deciduous incisors (Fig. 3). In young XLHED-affected dogs, deciduous teeth were present without radiographic evidence of permanent successors (Figs 4, 5). A mixed dentition of deciduous and permanent teeth was present beyond adolescence in 55% of adult XLHED-affected dogs.

#### Sedated examination and radiographic evaluations

The crowns and roots of permanent premolar and molar teeth, when present, exhibited conformational abnormalities in all XLHED-affected dogs (100%), including conical or peg-shaped crowns, decreased number of roots, diminutive roots compared to normal counterparts, fused roots, and dilaceration of the crowns or roots (Figs 5, 6).

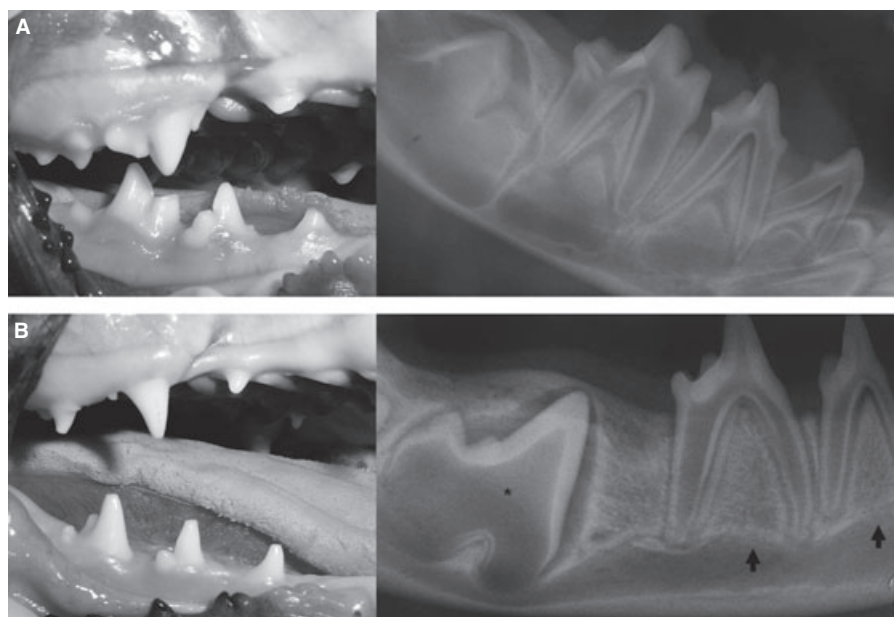
Two heterozygotes were sedated for dental radiographs. One dog exhibited normal crown and root structures with no missing teeth. Another carrier dog exhibited a mixture of normal and abnormally-shaped crowns and roots, missing teeth, persistent deciduous teeth, and mesioverted canine teeth. Radiographically, this heterozygote showed focal mineralization of the

**Table 1.** Comparison of percent of abnormal and missing teeth in XLHED-affected, heterozygous and normal dogs

Genotype	Incisors			Canines			Premolars			Molars		
	N	A	M	N	A	M	N	A	M	N	A	M
<b>Maxilla</b>												
Normal	100	0	0	100	0	0	100	0	0	100	0	0
Heterozygous	91.6	0	9.4	100	0	0	85.4	4.2	10.4	100	0	0
XLHED	0	78.8	21.2	0	95.5	4.5	0	37.5	62.5	0	81.8	18.2
<b>Mandible</b>												
Normal	100	0	0	100	0	0	100	0	0	100	0	0
Heterozygous	55.6	0	44.4	75	0	25	81.3	2.1	16.6	97.2	2.8	0
XLHED	0	47.0	53.0	0	77.3	22.7	0	15.9	84.1	0	81.8	18.2

Comparison of the permanent dentition between normal ( $n = 9$ ), heterozygous ( $n = 7$ ), and XLHED-affected dogs ( $n = 17$ ). The presence of normal (N) and abnormally shaped crowns (A) is given in percent of total teeth of the same type (incisors, canines, premolars or molars). Missing teeth (M) are also indicated in percent of the total teeth that would normally be present. Teeth defined as normal were present and showed no evidence of morphological abnormalities in crown shape, cusp number, cusp height, or tooth position. Abnormal teeth showed clinical evidence of one or more of the above crown abnormalities. Teeth were documented as missing if they were not present on conscious oral examination.





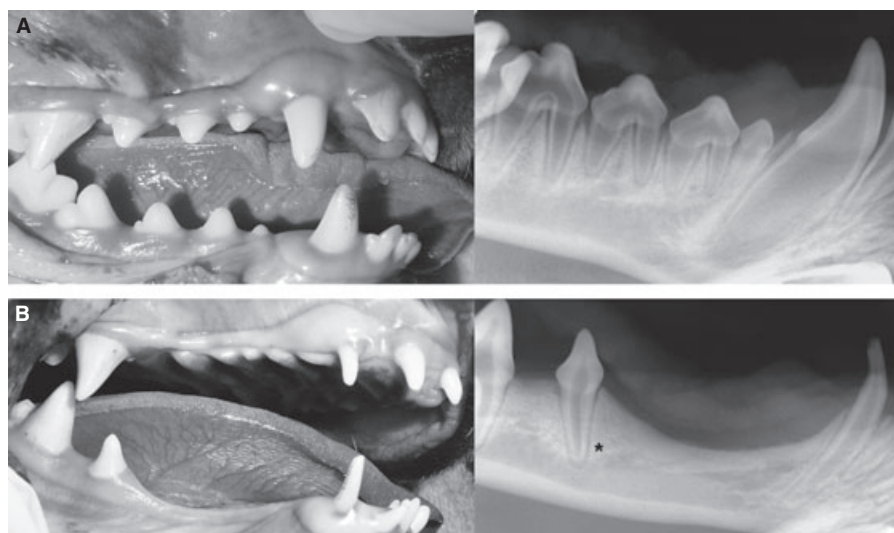
*Fig. 4. (A) Photographs and dental radiographs of normal and (B) XLHED-affected puppies. Deciduous teeth of affected dogs exhibit conical crowns with a reduced number of cusps. Note the abnormally shaped crown of the developing mandibular first molar tooth (asterisk) and no evidence of developing permanent premolars beneath the deciduous premolars (arrows).*

pulp chamber indicative of pulp stone formation of deciduous and permanent teeth (Fig. 7). This radiographic finding was also seen in one of the 17 XLHED-affected dogs (5.9%).

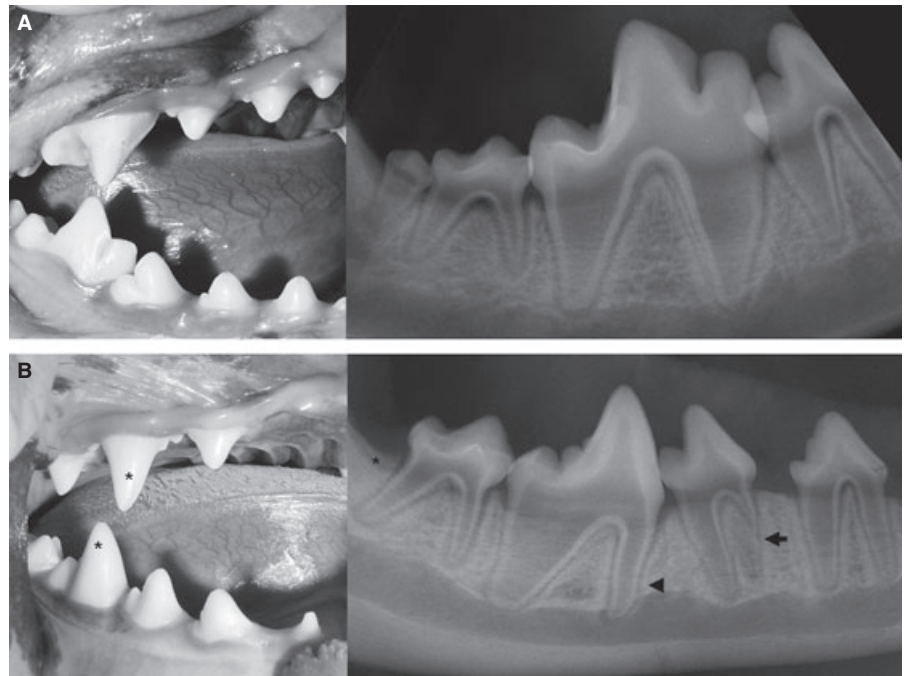
## Discussion

Ectodermal dysplasia has been described in pure and mixed-breed dogs, including the miniature poodle (28), Belgian shepherd (29), Labrador retriever (30), Bichon frise (31), German shepherd (4), whippet (32), cocker spaniel (33), and mixed breeds of the miniature pinscher and Pekingese (1). Chinese Crested and Mexican

hairless dogs are breeds which are affected by an autosomal dominant form of ED (34, 35). Diagnosis of ED can be made based on the characteristic distribution of congenital hairlessness, varying from complete alopecia to hypotrichosis of the top of the head, ventral chest and abdomen (Fig. 1) and dorsal pelvic area, the histological absence of piloglandular units in the alopecic areas, and the presence of dental abnormalities. Although heterozygous females may show mild signs of dysplasia, generally males are affected (1). Sixteen of the 17 affected dogs in the present study were males. The homozygous affected female was born to a heterozygous female that was bred to an XLHED-affected male.



*Fig. 5. (A) Photographs and intraoral dental radiographs of normal and (B) XLHED-affected canine and premolar teeth in adult dogs. The affected dog exhibits oligodontia, decreased number of roots (asterisk), and conical crowns. The deciduous mandibular canine teeth of the affected dog are still present with no evidence of formation of the permanent canine teeth.*



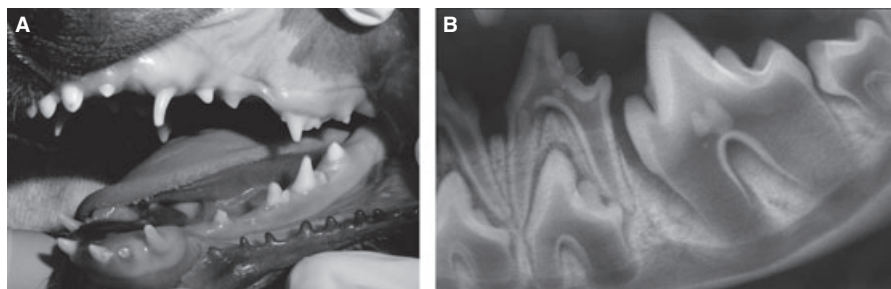
**Fig. 6.** (A) Photographs and dental radiographs of normal and (B) XLHED-affected molar and premolar teeth in adult dogs. The carnassial teeth (maxillary fourth premolar and mandibular first molar) exhibit conical crowns with a decreased number of cusps (asterisks). Note the convergence of the roots with malformation of the mesial root of the mandibular fourth premolar tooth (arrow), the diminutive mesial root of the mandibular first molar tooth (arrowhead), and the missing mandibular third molar tooth (asterisk).

One of the most prominent dental manifestations seen in XLHED-affected dogs is marked hypodontia and/or oligodontia (4). Interestingly, agenesis of teeth in humans with ED is more common on the left side than the right side (11), a feature that has also been recognized in patients with cleft lip and palate (36). An asymmetrical pattern of oligodontia was not recognized in XLHED-affected dogs of the present study. As seen in humans, teeth were more commonly missing from the mandible than the maxilla in the dogs of the current study.

In humans with ED, anterior teeth tend to be conical in shape, while posterior teeth are reduced in size and number of cusps (11). In XLHED-affected dogs, conical crown shape was seen in rostral (i.e., anterior) and caudal (i.e., posterior) teeth, with the carnassial teeth

being markedly affected (Fig. 6). A reduction in cusps is also seen in dogs, which is most prominent in the carnassial teeth. The term ‘peg tooth’ describes a form of microdontia occurring in humans, which can be due to XLHED, but is more commonly seen in humans without ED as an autosomal-dominant inheritance affecting lateral incisors (37). A ‘double tooth’, an anomaly of conjoined teeth, has also been reported in humans with ED. Double tooth is a general term of tooth anomaly indistinguishable as to whether fusion, gemination or schizodontia has occurred (8). No dogs in the present study exhibited fusion, gemination, concrescence or schizodontia.

Craniofacial abnormalities have been documented in humans with ED (6). The face often appears smaller due to frontal bossing and depression of the nasal



**Fig. 7.** (A) Photograph and (B) dental radiograph of a 4.5 month-old, female, mixed-breed dog heterozygous for XLHED. Mixed dentition reveals conical shape of maxillary and mandibular deciduous canine and mandibular fourth premolar teeth. Both the deciduous mandibular fourth premolar tooth and the developing permanent first molar tooth exhibit areas of focal mineralization within the pulp chamber suggestive of pulp stones. Similar pulpal mineralization has also been seen in one XLHED-affected dog.

bridge. The lips can be protuberant, and the ears may be more prominent. A high palatal arch or even a cleft palate may be present in humans with ED (6). The midface may be depressed, the cheek bones are frequently high, and the chin is often pointed (9). Since development of alveolar bone is dependent on the presence of teeth, edentulous areas show a hypoplastic or non-existent alveolar process (11). Dogs evaluated in the present study were mixed-breed dogs derived from mesaticephalic beagle and German shepherd lineage, therefore, conclusions about craniofacial abnormalities are difficult to make. Affected dogs appeared to have narrow muzzles compared to normal dogs from the same litter. Protuberant lips are generally present in XLHED-affected dogs at birth. However, no cleft lips or palates were seen in the 17 XLHED-affected dogs of the present study. Looking historically at a larger group of 100 XLHED dogs, three were affected with cleft lip and/or palate, whereas 1 of 125 normal/carrier dogs were affected by cleft lip/palate. Prevalence between these groups did not differ significantly when defined as a  $p$ -value of 0.05 or less. The prevalence of both groups was higher than the previously reported prevalence of 0.11% in an established line of 2650 research beagles (38).

## Conclusions

When developing postnatal treatment strategies of dental abnormalities associated with XLHED in humans, dogs may represent a more relevant study model than mice. Unlike dogs and humans, mice have neither canine nor premolar teeth. Mice have a mixture of brachyodont (short crowns with anatomical roots that stop growing once erupted) and aradicular hypsodont (large reserve crowns that continue to grow throughout life) teeth (39). Dogs and humans are similar in that their dentitions consist entirely of brachyodont teeth, which do not grow throughout life. Mice are monophyodont (having one set of teeth) whereas dogs and humans are diphyodont (having two dentitions, deciduous and a permanent). This is important when evaluating therapies for XLHED-associated dental abnormalities, since the diphyodont dentition of dogs and humans may allow for effective postnatal treatment in species with successional teeth (40), where the same therapies may only be effective in the embryonic monophyodont (41).

## Clinical relevance

Ectodermal dysplasia is seen in human and veterinary patients, and similarities between species suggest that the canine form of XLHED is an excellent model for study of future therapies in humans. However, to date, no canine studies have characterized the orthodontic and dental manifestations of the disease. Characterization of dental manifestations of XLHED in dogs will allow for better utilization of this model in the treatment of human and veterinary patients.

**Acknowledgements:** We thank Patricia O'Donnell, Bonnie Miller, Jodi Kristel, Jeanette Hernandez, and the veterinary students for their expert assistance and care of the dogs. This work was supported by NIH grants AR049817 and RR02512, and the National Foundation for Ectodermal Dysplasias.

## References

1. Moura E, Cirio SM. Clinical and genetic aspects of X-linked ectodermal dysplasia in the dog – a review including three new spontaneous cases. *Vet Dermatol* 2004;15:269–77.
2. Drogemuller C, Distl O, Leeb T. X-linked anhidrotic ectodermal dysplasia (ED1) in men, mice, and cattle. *Genet Sel Evol* 2003;35(Suppl.):S137–45.
3. Heller J. Alopecia congenita. *Die Vergleichende Pathologie der Haut*. Berlin: Verlag August Hirshwald; 1910. pp. 513.
4. Casal ML, Jczyk PF, Greek JM, Goldschmidt MH, Patterson DF. X-linked ectodermal dysplasia in the dog. *J Hered* 1997;88:513–7.
5. Tape MW, Tye E. Ectodermal dysplasia: literature review and a case report. *Compend Contin Educ Dent* 1995;16:524–8.
6. Ithagarun A, King NM. Ectodermal dysplasia: a review and case report. *Quintessence Int* 1997;28:595–602.
7. Hattab FN, Yassin OM, Sasa IS. Oral manifestations of Ellis-van Creveld syndrome: report of two siblings with unusual dental anomalies. *J Clin Pediatr Dent* 1998;22:159–65.
8. Atar G, Uzamis M, Olmez S. Ectodermal dysplasia with associated double tooth. *ASDC J Dent Child* 1997;64:362–4.
9. Vierucci S, Baccetti T, Tollaro I. Dental and craniofacial findings in hypohidrotic ectodermal dysplasia during the primary dentition phase. *J Clin Pediatr Dent* 1994;18:291–7.
10. Johnson EL, Roberts MW, Guckes AD, Bailey LJ, Phillips CL, Wright JT. Analysis of craniofacial development in children with hypohidrotic ectodermal dysplasia. *Am J Med Genet* 2002;112:327–34.
11. Prager TM, Finke C, Miethke RR. Dental findings in patients with ectodermal dysplasia. *J Orofac Orthop* 2006;67:347–55.
12. Lexner MO, Bardow A, Hertz JM, Nielsen LA, Kreiborg S. Anomalies of tooth formation in hypohidrotic ectodermal dysplasia. *Int J Paediatr Dent* 2007;17:10–8.
13. Pispas J, Jung HS, Jernvall J, Kettunen P, Mustonen T, Tabata MJ et al. Cusp patterning defect in tabby mouse teeth and its partial rescue. *Dev Biol* 1999;216:521–34.

14. Lesot H, Peterkova R, Kristenova P, Lisi S, Peterka M. Effect of the Tabby mutation on the dentition of mice. *Bull Group Int Rech Sci Stomatol Odontol* 2003;45:1–11.
15. Peterkova R, Kristenova P, Lesot H, Lisi S, Vonesch JL, Gendault JL et al. Different morphotypes of the tabby (EDA) dentition in the mouse mandible result from a defect in the mesio-distal segmentation of dental epithelium. *Orthod Craniofac Res* 2002;5:215–26.
16. Kristenova P, Peterka M, Lisi S, Gendault JL, Lesot H, Peterkova R. Different morphotypes of functional dentition in the lower molar region of tabby (EDA) mice. *Orthod Craniofac Res* 2002;5:205–14.
17. Risnes S, Peterkova R, Lesot H. Distribution and structure of dental enamel in incisors of Tabby mice. *Arch Oral Biol* 2005;50:181–4.
18. Tucker AS, Headon DJ, Courtney JM, Overbeek P, Sharpe PT. The activation level of the TNF family receptor, Edar, determines cusp number and tooth number during tooth development. *Dev Biol* 2004;268:185–94.
19. Falconer DS. A totally sex-linked gene in the house mouse. *Nature* 1952;169:664–5.
20. Ferguson BM, Brockdorff N, Formstone E, Ngyunen T, Kronmiller JE, Zonana J. Cloning of tabby, the murine homologue of the human EDA gene: evidence for a membrane associated protein with a short collagenous domain. *Hum Mol Genet* 1997;6:1589–94.
21. Headon DJ, Overbeek PA. Involvement of a novel TNF receptor homologue in hair follicle induction. *Nat Genet* 1999;22:370–4.
22. Headon DJ, Emmal SA, Ferguson BM, Tucker AS, Justice MJ, Sharpe PT, et al. Gene defect in ectodermal dysplasia implicates a death domain adapter in development. *Nature* 2002;414:913–6.
23. Srivastava AK, Pispa J, Hartung AJ, Du Y, Ezer S, Jenks T et al. The Tabby phenotype is caused by mutation in a mouse homologue of the EDA gene that reveals novel mouse and human exons and encodes a protein (ectodysplasin-A) with collagenous domains. *Proc Natl Acad Sci* 1997;94:13069–74.
24. Grüneberg H. Genes and genotypes affecting the teeth of the mouse. *J Embryol Exp Morphol* 1965;14:137–59.
25. Casal ML, Scheidt JL, Rhodes JL, Henthorn PS, Werner P. Mutation identification in a canine model of X-linked ectodermal dysplasia. *Mamm Genome* 2005;16:524–31.
26. Lewis JR, Miller BR. Veterinary dentistry. In: Bassett JM, McCurnin DM editors. *Clinical Textbook for Veterinary Technicians*, 7th edn. St. Louis: Elsevier Saunders; 2010. pp. 1093–148.
27. Hale FA. Dental caries in the dog. *J Vet Dent* 1998;15:79–83.
28. Selmanowitz VJ, Kramer KM, Orentreich N, Hyman AB. Congenital ectodermal dysplasia in male miniature poodle siblings. *Arch Dermatol* 1970;101:613–5.
29. Muller GH, Kirk RW, Scott DW. Congenital and hereditary defects. *Small Animal Dermatology*, 3rd edn. Philadelphia: W.B. Saunders; 1983. pp. 578–82.
30. Kunkle GA. Congenital hypotrichosis in two dogs. *J Am Vet Med Assoc* 1984;185:84–5.
31. Grieshaber TL, Blakemore JC, Yaskulski S. Congenital alopecia in a Bichon Frise. *J Am Vet Med Assoc* 1986;188:1053–4.
32. Thomsett LR. Congenital hypotrichia in the dog. *Vet Rec* 1961;73:915–7.
33. Kral F, Schwartzman RM. Functional disorders of the skin. *Veterinary and Comparative Dermatology*. Philadelphia: Lippincott; 1964. pp. 182–91.
34. Robinson R. Chinese crested dog. *J Hered* 1985;76:217–8.
35. Kimura T, Ohshima S, Doi K. The inheritance and breeding results of hairless descendants of Mexican hairless dogs. *Lab Anim* 1993;27:55–8.
36. Aizenbud D, Camasuvi S, Peled M, Brin I. Congenitally missing teeth in the Israeli cleft population. *Cleft Palate Craniofac J* 2005;42:314–7.
37. Regezi JA, Sciubba JJ, Jordan RCK. Abnormalities of teeth. *Oral Pathology: Clinical Pathologic Correlations*, 4th edn. St. Louis: Saunders; 2003. pp. 367–84.
38. Natsume N, Miyajima K, Kinoshita H, Kawai T. Incidence of cleft lip and palate in beagles. *Plast Reconstr Surg* 1994;93:439.
39. Crossley DA. Clinical aspects of rodent dental anatomy. *J Vet Dent* 1995;12:131–5.
40. Casal ML, Lewis JR, Mauldin EA, Tardivel A, Ingold K, Favre M et al. Significant correction of disease after postnatal administration of recombinant ectodysplasin A in canine X-linked ectodermal dysplasia. *Am J Hum Genet* 2007;81:1050–6.
41. Gaide O, Schneider P. Permanent correction of an inherited ectodermal dysplasia with recombinant EDA. *Nat Med* 2003;9:614–8.



Copyright of Orthodontics & Craniofacial Research is the property of Blackwell Publishing Limited and its content may not be copied or emailed to multiple sites or posted to a listserv without the copyright holder's express written permission. However, users may print, download, or email articles for individual use.