

# Therapeutic Protocols for Avulsed Permanent Teeth: Review and Clinical Update

Diana Ram, Dr Odont    Nestor Cohenca, DDS

*Dr. Ram is a clinical lecturer, Department of Pediatric Dentistry, Hebrew University, Hadassah School of Dental Medicine, Israel; Dr. Cohenca is a clinical lecturer, Department of Endodontics, Hebrew University, Hadassah School of Dental Medicine, and assistant professor, Division of Surgical, Therapeutic, and Bioengineering Sciences, University of Southern California School of Dentistry, Los Angeles, Calif.*

*Correspond with Dr. Ram at dianaram@netvision.net.il*

---

## Abstract

Traumatic injuries to permanent teeth include coronal and root fractures, subluxations, luxations, and avulsions. The most common complications after avulsions are necrosis of the pulp and root resorption. Treatment is often complex, time consuming, and expensive and requires multidisciplinary approaches such as endodontic and periodontal treatments, surgery, orthodontic movements, as well as esthetic coronal restoration. This review describes new clinical modalities for the treatment of avulsed teeth and discusses the rationale for their use. (*Pediatr Dent.* 2004;26:251-255)

**KEYWORDS: AVULSIONS, PERMANENT TEETH, PROTOCOL**

---

*Received June 9, 2003    Revision Accepted January 2, 2004*

The incidence of dental trauma due to automobile accidents and violence has increased significantly during the last decade causing the anterior teeth of children and teenagers to be commonly affected.<sup>1</sup> The incidence is even higher in children between 8 and 12 years old due to bicycle, skateboard, and sports accidents. The mean prevalence of dental and oral injuries reported in the literature oscillated between 14% and 27%. Boys showed a higher prevalence than girls, but this difference was only significant for age groups 12 and 13.<sup>2-3</sup> Certain predisposing factors like protruded maxillary incisors and insufficient lip closure may affect the extent of the dental trauma. In contrast, in adults the traumatic injuries are more likely related to car accidents, fights, and sports.

Avulsed teeth statistically represent 1% to 16 % of all traumatic injuries to permanent dentition.<sup>4</sup> The traumatic extraction of a tooth from its respective socket produces breakdown of the periodontal ligaments and the blood supply to the pulp tissue. In consequence, the dental pulp undergoes necrosis and periodontium is severely damaged.

Immediately after replantation, an inflammatory process in the periodontal tissues induces the reorganization of the new attachment apparatus. The type of healing will be directly related to the extension of the extraoral period and conditions in which the tooth was maintained prior to the replantation.<sup>5-6</sup>

Understanding the basic principles and therapeutic protocols can help to provide the appropriate treatment, and in some cases, prevent the development of root resorptions following trauma.

## Therapeutic protocols

Treatment of avulsed teeth is divided in 2 main stages:

1. emergency treatment that should be provided as soon as possible; and
2. definitive treatment based on a clinical and radiographic follow-up examination.

The American Association of Endodontics (AAE) published therapeutic protocols<sup>7</sup> to standardize the concept and treatment of dental trauma cases. The recommendations emphasized the importance of minimizing damage to the root cementum and periodontal tissues to prevent infection of the root canal. During the last years, the International Association of Dental Trauma (IADT) published new recommendations that established new concepts and suggestions especially for avulsed teeth that were kept outside of the mouth in nonbiological conditions for more than 60 minutes.<sup>8</sup>

The new therapeutic protocol emphasizes preconditioning the root as a prior stage to the replantation of the tooth. Treatment of teeth that have completed root development is different from that involving an immature root. It is very important to

take into consideration how long and under which conditions the tooth was kept out of the mouth (Figure 1).

#### Treatment at the place of accident

Avulsed teeth should be replanted in the socket as soon as possible. The long-term success depends mainly on the extraoral period.<sup>9</sup> Under the circumstances, best results will be achieved if the tooth remains out of the socket for less than 20 minutes.<sup>9-10</sup>

In case the tooth cannot be reimplanted at the place of the accident, it should be stored in special storage media like milk or in a biological medium like Hank's Balanced Salt Solution (HBSS) to maintain periodontal tissue in as good a state as possible until the patient receives appropriate treatment at a dental office. One of the best and most available mediums in which to store an avulsed tooth is HBSS.<sup>11-12</sup> Communities should be prompted to include the HBSS in every first aid kit available in schools, gyms, summer camps, playgrounds, ambulances, and emergency rooms.

Milk, another recommended medium,<sup>13</sup> is not as good as the HBSS but it can be found almost everywhere. In order of priority, sterile saline is the next medium to be used, even though it cannot easily be found in public places.

The tooth can be also kept in the child's mouth.<sup>14</sup> However, there are 2 main reasons to avoid this procedure. The first one is the dangerous possibility that the child will swallow the tooth. The second reason is that saliva is a septic medium that increases the possibility of infecting the periodontal tissues that remain attached to the root surface. Tap water is not recommended, but it can be used if any of the aforementioned mediums are not available.

#### Teeth that are replanted at the place of the accident

1. Clean the affected area with sterile saline or chlorhexidine.
2. Suture the soft tissues when necessary.
3. Verify the correct reposition of the tooth radiographically.

#### Teeth with 60 minutes or less extraoral dry time and teeth stored in a biological medium

Fully developed teeth with an extraoral dry time of 1 hour or less or teeth stored in a biological medium should be treated carefully to avoid further damage to the root surface and remaining periodontal ligament tissues. The tooth should be held by the crown, irrigated with sterile saline, and replanted with a gentle digital pressure.<sup>8</sup>

In cases of teeth with a partial development of the root, it is recommended to soak the tooth in Doxycycline

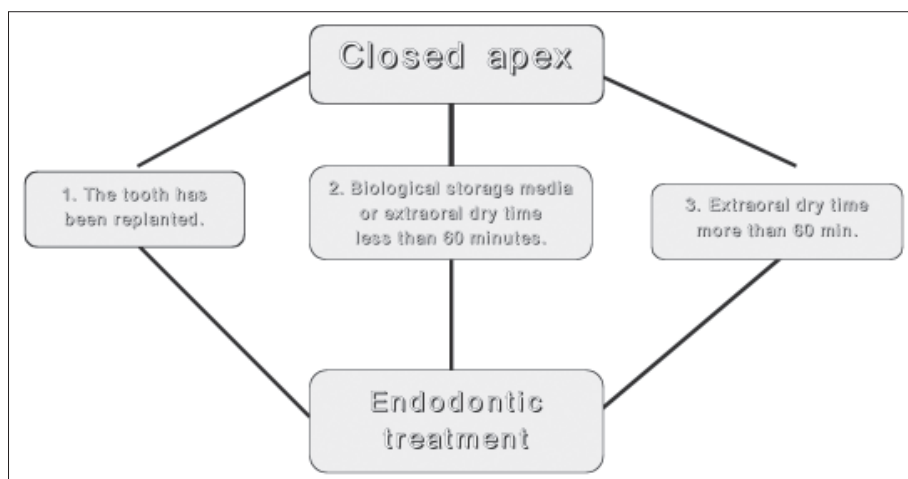


Figure 1. Therapeutic chart for avulsed teeth with closed apex.

0.005% for 5 minutes before replantation. It was found that pulp revascularization was significantly enhanced in up to 40% to 60% of the treated cases.<sup>15-16</sup>

#### Teeth with more than 60 minutes extraoral dry time

It can be assumed that, in cases of avulsed teeth stored in dry conditions for more than 1 hour, the periodontal ligament (PDL) will be necrotic and, consequently, replacement root resorption is expected to develop.<sup>17-18</sup> To attenuate or slow down the resorption process, it has been recommended to follow a root preconditioning protocol.<sup>15,19-22</sup>

#### Treatment of the root surface

1. Eliminate the necrotic tissue from the root surface. The procedure can be performed mechanically (curettage)<sup>19</sup> or chemically using EDTA 24%, citric acid, or sodium hypochlorite.<sup>23-24</sup>
2. Hold the tooth by the crown and irrigate the root surface with sterile saline.
3. Soak the tooth in a sodium fluoride 2.4% 5.5 pH solution for 20 minutes<sup>21</sup> or, if available, fill the socket with Emdogain.<sup>8</sup>

In recent years, several treatment modalities were proposed to delay or prevent the associated root resorption and, thus, increase the long-term success rate of avulsed teeth.<sup>19-22</sup> The International Association of Dental Traumatology (IADT) guideline for management of avulsed mature permanent teeth replanted after 60 minutes in dry extraoral conditions endorses the use of Emdogain prior to replantation.<sup>8</sup>

Emdogain consists of hydrophobic enamel matrix proteins extracted from porcine-developing embryonic enamel. Earlier studies suggested that enamel matrix proteins from Hertwig's epithelial root sheath initiated the formation of acellular cementum.<sup>25</sup> These proteins are synthesized by ameloblast cells and are secreted into the enamel extracellular matrix where they nucleate and regulate the growth of hydroxyapatite crystals to form the mineralized enamel.<sup>26</sup>

It has been suggested that Emdogain can be used for treating avulsed teeth prior to replantation to prevent or delay replacement root resorption by regenerating a healthy periodontium.<sup>8,26-29</sup> The mechanism of action of Emdogain is based on its ability to produce new periodontal ligament from the socket side cell population.

To date, clinical evidence regarding the success rate of avulsed teeth treated with Emdogain prior to replantation is lacking. In addition, the effect of 24% EDTA root preconditioning prior to the replantation on the long-term success rate merits further investigation.

#### **Treatment of the dental socket**

Recently, new emphasis has been placed on the role of the socket in cases of avulsed teeth. Damage to the socket during the replantation is directly related to the long-term success of the treatment.<sup>30-31</sup> The socket should be rinsed with sterile saline. If the alveolar bone has collapsed, it should be repositioned gently. In any case, the use of an air syringe should be avoided to dry the socket. A flap elevation is indicated only in cases where the bone interferes with the replantation of the tooth.

#### **Repositioning of the tooth**

After all the aforementioned treatment is performed, the tooth should be repositioned very gently in the dental socket with a light digital pressure.

#### **Treatment of the supporting tissues**

In cases of soft tissue lacerations, suturing should be done to stop the bleeding, allow primary type regeneration, and avoid the penetration of microorganisms into the periodontal tissues.

#### **Tooth immobilization**

It is recommended to immobilize the tooth with a semi-rigid splint during 7 to 10 days.<sup>1,32</sup> The splint should not interfere with the patient's capability to perform correct hygiene and should allow a physiological movement of the tooth. In cases of bone fracture, the tooth should be splinted for a longer period, (1 or 2 months), depending on the clinical situation. Rigid immobilization is contraindicated, except in cases of root fracture.<sup>8</sup> After the immobilization, a radiograph should be taken to verify the correct position of the tooth.

#### **Pharmacologic treatment**

It is recommended to prescribe antibiotic therapy to avoid the onset of infection during the first week after replantation.<sup>33</sup> The administration of systemic antibiotic prevents the development of external root resorption.<sup>33-34</sup> The antibiotic of choice is Amoxicillin 500 mg  $\times$  3/day for 7 days (children=50 mg/kg/day in divided doses every 8 hours),<sup>33</sup> although many studies showed the advantage of the use of Doxycycline 100 mg  $\times$  1/day for 7 days (children=2 mg/kg/day) in cases of avulsion.<sup>35-36</sup>

Chlorhexidine rinses must be prescribed and strict hygiene instructions given, during the entire splinting period. In case of pain, analgesics can be prescribed. Soft diet should be recommended during the days following the replantation. It is suggested to consult with a physician about the need for a tetanus booster during the first 48 hours after the accident.<sup>8</sup>

In cases of incomplete root development and extraoral dry time greater than 60 minutes, tooth replantation is not recommended.<sup>8</sup> The rationale to support this recommendation is based on the lack of a possible regeneration of the pulp and periodontal tissues. In such cases, the tooth remains immature with a very short root and thin dentinal walls. In most cases, considering the type of trauma, extraoral time, and age of the child, replacement root resorption is expected to progress very quickly.

#### **Endodontic treatment**

Timing of the endodontic treatment is directly linked to the stage of root development.

##### **Tooth with a completely developed root**

If the extraoral time was less than 1 hour or if the tooth was soaked immediately in a biological medium, it is recommended to extirpate the pulp tissue 10 to 14 days after replantation and fill the root canal with a medication based on calcium hydroxide for a period ranging between 2 weeks to 6 months. It has been shown that calcium hydroxide promotes disinfection of the root canal and prevents inflammatory root resorption.<sup>37-38</sup> Recent studies reported success in the use of Ledermix Paste (Lederle Pharmaceuticals, Wolfrantshausen, Germany), an endodontic medication based on steroids and antibiotics, in preventing root resorption.<sup>39-40</sup> A short follow-up period occurs, depending on the resorption progression, if diagnosed. Immediately after this stage, the root canal should be filled with a conventional filling.

If the tooth has been out of the socket and kept dry for more than 1 hour, it is recommended to leave the calcium hydroxide filling for a long follow-up period to evaluate the rate of the replacement root resorption before the permanent root filling is completed. Depending on the age of the patient and root resorption rate, surgical decoronation should be considered to preserve the width and height of the alveolar ridge.<sup>41</sup> During the procedure, the crown and root filling material are removed, allowing the decoronated root to be gradually fully resorbed.

##### **Tooth with an incomplete developed root**

If the extraoral time was less than 1 hour or if the tooth was stored in a biological medium, it should be replanted immediately to allow revascularization. It is contraindicated to perform endodontic treatment as a first treatment of choice. There is a great deal of evidence to support the possibility of pulp revascularization based on the development of young tissue rich in blood vessels.<sup>15,42-44</sup>

Periodical examination is mandatory at least once a month. In case pulp necrosis is diagnosed, long-term apexification with calcium hydroxide alone or short-term apexification with calcium hydroxide followed by apical seal with Mineral Trioxide Aggregate (MTA) should be performed to avoid inflammatory root resorption, and create an apical barrier. At the end of the treatment, a conventional endodontic filling should be placed. If the extraoral dry time was greater than 1 hour, it is not recommended to replant the tooth.<sup>8</sup>

### Crown restoration

Crown restoration and sealing the endodontic access cavity should be performed as soon as possible to prevent infection of the root canal filling and strengthen the cervical area of the tooth. It has been demonstrated that coronal leakage and penetration of microorganisms through the crown may be one of the main reasons for endodontic failure.<sup>45-46</sup>

### Follow-up period

Most of the surrounding and antagonist teeth and surrounding tissues are affected during a traumatic injury to the face. It is recommended to perform a clinical follow-up examination 1 week, 2 to 3 weeks, 3 to 4 weeks, 6 to 8 weeks, and then every 6 months over a period of 5 years.<sup>1,8</sup> During this period, complications can be early diagnosed and treated. The pulp vitality of the affected teeth must be re-evaluated periodically. Some complications like pulp necrosis or root resorption may occur long after the incident, requiring immediate treatment.

### References

- Andreasen JO, Andreasen FM. *Textbook and Color Atlas of Traumatic Injuries to the Teeth*. 3rd ed. Copenhagen: Munksgaard; 1994:383-425.
- Delattre JP, Resmond-Richard F, Allanche C, Perrin M, Michel JF, Le Berre A. Dental injuries among schoolchildren aged from 6 to 15. In: Rennes, ed. *Endod Dent Traumatol*. 1995;11:186-188.
- Levin L, Friedlander L, Geiger SB. Dental and oral trauma and mouthguard use during sport activities in Israel. *Dent Traumatol*. 2003;19:237-240.
- Fountain SB, Camp JH. Traumatic injuries. In: Cohen S, Burns AC, eds. *Pathways of the Pulp*. 6th ed. St Louis: Mosby; 1994.
- Andreasen JO. Periodontal healing after replantation of traumatically avulsed human teeth: Assessment by mobility testing and radiography. *Acta Odontol Scand*. 1975;335:325-335.
- Andreasen JO, Kristerson L. The effect of limited drying or removal of the periodontal ligament: Periodontal healing after replantation of mature permanent incisors in monkeys. *Acta Odontol Scand*. 1981;39:1-13.
- Treatment of the avulsed permanent tooth: Recommended guidelines of the American Association of Endodontists. AAE publication; 1995.
- Flores MT, Andreasen JO, Bakland LK, et al. Guidelines for the evaluation and management of traumatic dental injuries. *Dent Traumatol*. 2001;17:193-198.
- Andreasen JO. The effect of extra-alveolar period and storage media upon periodontal and pulpal healing after replantation of mature permanent incisors in monkeys. *Int J Oral Surg*. 1981;10: 43-45.
- Andreasen JO, Hjorting-Hansen E. Replantation of teeth 1. Radiographic and clinical study of 110 human teeth replanted after accidental loss. *Acta Odontol Scand*. 1966; 24:263-286.
- Hiltz J, Trope M. Vitality of human lip fibroblasts in milk, Hank's Balanced Salt Solution, and Viaspan storage media. *Endod Dent Traumatol*. 1991;7:69-72.
- Trope M, Friedman S. Periodontal healing of replanted dog teeth stored in Viaspan, milk, and Hank's Balanced Salt Solution. *Endod Dent Traumatol*. 1992;8:183-188.
- Blomloff L. Milk and saliva as possible storage media for traumatically exarticulated teeth prior to replantation. *Swed Dent J*. 1981;8:1-26.
- Lindskog S, Blomloff L. Influence of osmolarity and composition of some storage media on human periodontal ligament cells. *Acta Odontol Scand*. 1982;40:435-441.
- Cvek M, Cleaton-Jones P, Austin J, Lownie J, King M, Fatti P. Effect of topical application of doxycycline on pulp revascularization and periodontal healing in reimplanted monkey incisors. *Endod Dent Traumatol*. 1990;6:170-176.
- Yanpiset K, Trope M. Pulp revascularization of replanted immature dog teeth after different treatment methods. *Endod Traumatol*. 2000;16: 211-217.
- Lindskog S, Blomloff L, Hammarstrom L. Repair of periodontal tissues in vivo and in vitro. *J Clin Periodontol*. 1983;10:188.
- Trope M, Friedman S. Periodontal healing of replanted dog teeth stored in Viaspan, milk, and Hanks Balanced Salt Solution. *Endod Dent Traumatol*. 1992;8:183.
- Lindskog S, Pierce AM, Blomloff L, Hammarstrom L. The role of the necrotic periodontal membrane in cementum resorption and ankylosis. *Endod Dent Traumatol*. 1985;1:96-101.
- Krasner P, Rankow HJ. New philosophy for the treatment of avulsed teeth. *Oral Surg Oral Med Oral Pathol*. 1995;79:616-623.
- Shulman LB, Gedalia I, Feingold RM. Fluoride concentration in root surfaces and alveolar bone of fluoride immersed monkey incisors three weeks after replantation. *J Dent Res*. 1973;52:1314-1316.



22. Bjorvatn K, Selvig KA, Klinge B. Effect of tetracycline and SnF<sub>2</sub> on root resorption in replanted incisors in dogs. *Scand J Dent Res*. 1989;97:477-482.
23. Selvig KA, Bjorvatn K, Bogle GC, Wikesjo UME. Effect of stannous fluoride and tetracycline on periodontal repair after delayed tooth replantation in dogs. *Scand J Dent Res*. 1992;100:200-203.
24. Yang ZP, Chan CC, Yang SF, Lee G, Yang SF. The interrelationship between the root surface and alveolar bone of replanted avulsed tooth after etching. *Zhonghua Yi Xue Za Zhi* (Taipei). 1989;44:298-303.
25. Slavkin HC, Boyde A. Cementum: An epithelial secretory product? *J Dent Res*. 1975;53:157-160.
26. Zeichner-David M. Is there more to enamel matrix proteins than biomineralization? *Matrix Biol*. 2001;20:307-316.
27. Hammarstrom L. Enamel matrix, cementum development and regeneration. *J Clin Periodontol*. 1997;24:705.
28. Kenny DJ, Barret EJ, Johnsson DH, Sigal MJ, Tenenbaum HC. Clinical management of avulsed permanent incisors using Emdogain: Case report. *J Can Dent Assoc*. 2000;66:21.
29. Iqbal MK, Bamaas NS. Effect of Emdogain upon periodontal healing after replantation of permanent incisors in Beagle dogs. *Dent Traumatol*. 2001;17:36-45.
30. Trope M, Hupp JG, Mesaros SV. The role of the socket in the periodontal healing of replanted dogs teeth stored in Viaspan for extended periods. *Endod Dent Traumatol*. 1997;13:171-175.
31. Trope M. Avulsion and replantation. *J Israel Dent Assoc*. 2002;19:6-15.
32. Andreasen JO, Friskopp J, Blomloff L. Fiberglass splinting of traumatized teeth. *J Dent Child*. 1983;3:21-24.
33. Hammarstrom L, Blomloff L, Feiglin B, Andersson L, Lindskog S. Replantation of teeth and antibiotic treatment. *Endod Dent Traumatol*. 1986;2:51-57.
34. Hammarstrom L, Pierce A, Blomloff L, Feiglin B, Lindskog S. Tooth avulsion and replantation. *Endod Dent Traumatol*. 1986;2:1-8.
35. Keller DC, Carano A. Tetracycline effect on osteoclastic and osteoblastic activity. *Gen Dent*. 1995;43:60-63.
36. Sae-Lim V, Wang CY, Trope M. The effect of systemic tetracycline on resorption of dried replanted dogs teeth. *Endod Dent Traumatol*. 1998;14:216-220.
37. Bystrom A, Claesson R, Sundqvist G. The antibacterial effect of camphorated paramonochlorophenol, camphorated phenol, and calcium hydroxide in the treatment of infected root canals. *Endod Dent Traumatol*. 1985;1:170-175.
38. Sjogren M, Figdor D, Spandberg L, Sundqvist G. The antimicrobial effect of calcium hydroxide as a short-term intracanal dressing. *Int Endod J*. 1991;24:119-125.
39. Bryson EC, Levin L, Banchs F, Abbot PV, Trope M. Effect of immediate intracanal placement of Ledermix Paste on healing of replanted dog teeth after extended dry times. *Dent Traumatol*. 2002;18:316-321.
40. Wong KS, Sae-Lim V. The effect of intracanal Ledermix on root resorption of delayed replanted monkey teeth. *Dent Traumatol*. 2002;18:309-315.
41. Malmgren B, Malmgren O. Rate of infraposition of reimplanted ankylosed incisors related to age and growth in children and adolescents. *Dent Traumatol*. 2002;18:28-36.
42. Skoglund A, Tronstad L. Pulpal changes in replanted and auto-transplanted immature teeth of dogs. *J Endod*. 1981;7:309-313.
43. Kling, Cvek M, Mejare I. Rate and predictability of pulp revascularization in therapeutically reimplanted permanent incisors. *Endod Dent Traumatol*. 1986;2:83-88.
44. Mesaros S, Trope M. Revascularization of traumatized teeth assessed by laser Doppler flowmetry: Case report. *Endod Dent Traumatol*. 1997;13:24-30.
45. Wilcox LR, Diaz-Arnold A. Coronal microleakage of permanent lingual access restorations in endodontically treated teeth. *J Endod*. 1989;15:584-587.
46. Saunders WP, Saunders EM. Coronal leakage as a cause of failure in root canal therapy: A review. *Endod Dent Traumatol*. 1994;10:105-108.

Copyright of Pediatric Dentistry is the property of American Society of Dentistry for Children and its content may not be copied or emailed to multiple sites or posted to a listserv without the copyright holder's express written permission. However, users may print, download, or email articles for individual use.