



Multi-colored Dual-cured Compomer

Theodore P. Croll, DDS Mark L. Helpin, DMD Kevin J. Donly, DDS, MS

Dr. Croll is a pediatric dentist in private practice, Doylestown, Penn, and clinical professor, Department of Pediatric Dentistry, University of Pennsylvania School of Dental Medicine; Dr. Helpin is associate professor, Department of Pediatric Dentistry, University of Pennsylvania School of Dental Medicine, Philadelphia, Pa; Dr. Donly is professor and postdoctoral program director, Department of Pediatric Dentistry, Dental School, University of Texas Health Science Center at San Antonio, San Antonio, Tex.
Correspond with Dr. Croll at willipus@tradenet.net

Abstract

A new polyacid-modified resin-based composite (compomer) restorative material has been introduced. Unlike other compomers, this material undergoes both chemical polymerization and photocuring hardening reactions. The new compomer is called MagicFil, and its chief attraction to children is that it is manufactured in 4 different colors, all with glitter inclusions. (*Pediatr Dent.* 2004;26:273-276)

KEYWORDS: PRIMARY TEETH, COMPOMER, DUAL POLYMERIZATION, RESTORATIVE DENTISTRY

Received January 6, 2003 Revision Accepted August 12, 2003

A new polyacid-modified resin-based composite (compomer) dental restorative material was first introduced in Europe and then in North America in 2003. The material is called MagicFil (Zenith/DMG, Englewood, NJ) and it has 2 major features that make it different from most other compomers:

1. MagicFil polymerizes both by visible light activation and chemical resin curing.
2. The material is manufactured in various bright colors, with "glitter" inclusions, because it is made specifically to be used in primary teeth. The colors are blue, purple, yellow, and universal. A green color can be developed by mixing some yellow material with the blue.

Even though MagicFil is made to be decorative, it has physical properties that apparently are sufficient to hold up in the mouth until the restored primary tooth is lost. This colored compomer contains the same glass filler particles used in glass polyalkenoate (ionomer) systems and Bis-GMA resins that have dual-curing capabilities. The material is filled 63% by weight and 40% by volume and has a shelf life of 2 years.

The manufacturer lists the following physical properties:

1. compressive strength=200 MPa;
2. flexural strength=80 MPa;
3. flexural modulus=6500 MPa;
4. setting time (chemical)=4 minutes;
5. setting time (photo)=40 seconds.

Some children and parents prefer tooth-colored, imperceptible dental restorations. However, other children enjoy selecting a colorful filling material for their primary teeth, if given the opportunity. In addition, many parents consent to this novel approach to primary tooth restoration, comparing it to a child's selection of colored ligature elastics and decorated appliances used in orthodontics.

This article details a step-by-step procedure for use of MagicFil compomer material for occlusal restoration of a primary second molar. In addition, another patient is pictured with MagicFil restorations 1 year after placement.

Methods

MagicFil is used in the same manner as other compomer restorative materials.¹ Local anesthesia and rubber dam are used routinely, in the usual manner. Etching of enamel is recommended to enhance adhesion and minimize marginal microleakage. Primary second molar occlusal restoration in an 8-year-old girl was accomplished as follows:

1. The cavity preparation is similar to that for a Class I resin-based composite. Mechanical interlocking retention naturally occurs when a conservative outline form is used, and from complete debridement of carious tooth substance with slow-speed round burs. No other undercutting is required such as in a preparation for a silver amalgam restoration. Likewise, there is no need to include sharp internal line angles or to extend the preparation into all grooves "for prevention" or for

increased bulk of material (Figure 1). Outline form of the preparation for the tooth pictured in Figure 1 resembles that for a silver amalgam because of the extent and location of caries infection.

2. A resin-modified glass ionomer liner/base was used to replace dentin, because there were areas of deep dentinal preparation (Figure 2).^{2,3}
3. In the case of a Class II restoration, a matrix strip secured with a wedge would be used.
4. Enamel surfaces peripheral to the preparation should be roughened with a slow-speed round diamond bur, to enhance the acid etching process.⁴
5. In this case, a self-etching resin bonding system was used (Prompt L-Pop, 3M ESPE, St. Paul, Minn) to bond the compomer to the enamel and resin-modified glass ionomer liner (Figure 3). Other self-etching resin-adhesive systems could also be used according to the dentist's preference. Alternatively, the preparation and peripheral enamel can be etched with phosphoric acid-etching solution and rinsed and dried in the usual manner in preparation for application of a resin bonding agent.
6. A mixing tip was placed on the double-barreled mixing/injection syringe and a small increment of material (about 1-1.5 mm thick) was injected into the cavity preparation (Figure 4). The compomer was then light cured for 30 seconds (Figure 5). The patient chose the purple shade of MagicFil because she said "it is really cool."
7. A second layer of material was injected and spread to fill the preparation and overlap cavosurface margins. The light beam was applied for 40 seconds. In primary teeth, 2 increments of compomer usually suffice.
8. A large round diamond bur at slow speed was then used to trim excess compomer material and sculpt occlusal surface form (Figure 6).
9. A thin coating of self-etching adhesive was rubbed into the trimmed compomer surface and surrounding enamel for 15 seconds, followed by a similar coating of clear resin sealant. The light beam was applied for an additional 15 seconds (Figure 7). A final sealant coating seals marginal microgaps, repairs resin surface damage from the diamond finishing, and obviates the need for final polishing of the compomer surface.
10. Occlusion was evaluated with articulating paper, and, in this case, no adjustments were needed (Figure 8).
11. The purple restoration was intact and serving its purpose well, 10 months after placement (Figures 9 and 10). MagicFil restorations in another child are pictured 1 year after placement (Figure 11).

Discussion

Compomers can be used, within their limitations, for restoring primary teeth.¹ However, one must consider that the physical properties of the polyacid-modified resin-based composites do not match those of traditional resin-based composites; hence, long-term durability of the respective

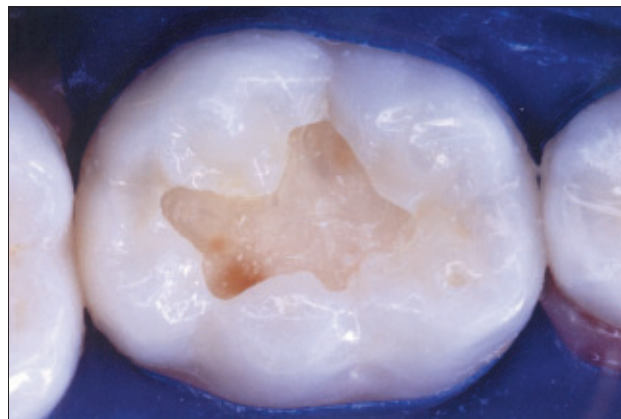


Figure 1. Initial outline form for occlusal restoration of primary second molar.

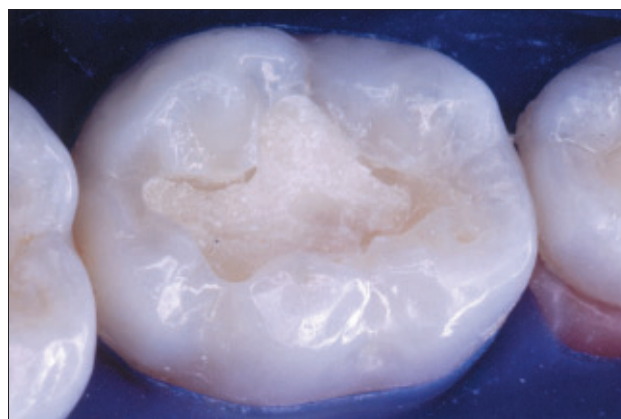


Figure 2. The carious substance is debrided and the resin-modified glass ionomer liner is placed, cured, and finished.

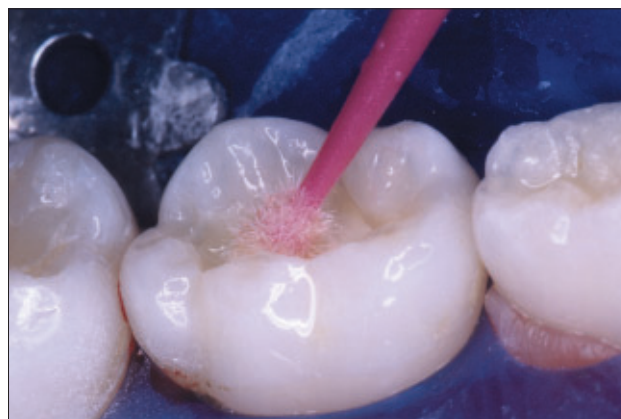

Figure 3. The self-etching adhesive bonding agent is applied after the enamel is roughened with a round diamond bur.⁴

resin formulations will vary. In primary teeth with caries lesions in stress-bearing regions, the authors have used MagicFil only for children whose treated teeth are expected to exfoliate within 3 to 5 years.

It is the authors' experience that certain children in the 7- to 11-year old range are the chief enthusiasts for the "rainbow-colored filling" concept. It is useful to complete MagicFil restorations on artificial teeth, as demonstration

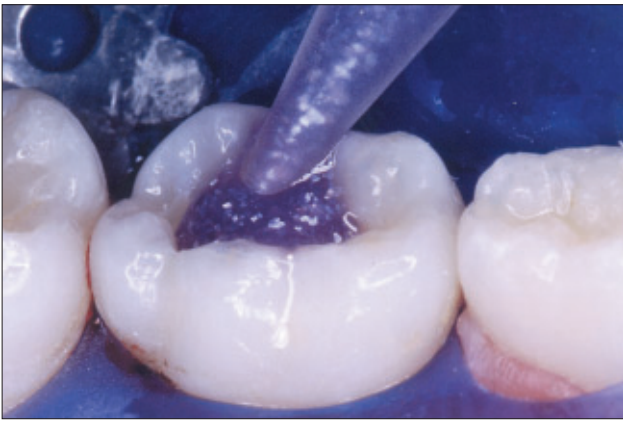

Figure 4. The first increment of MagicFil is syringed into place.

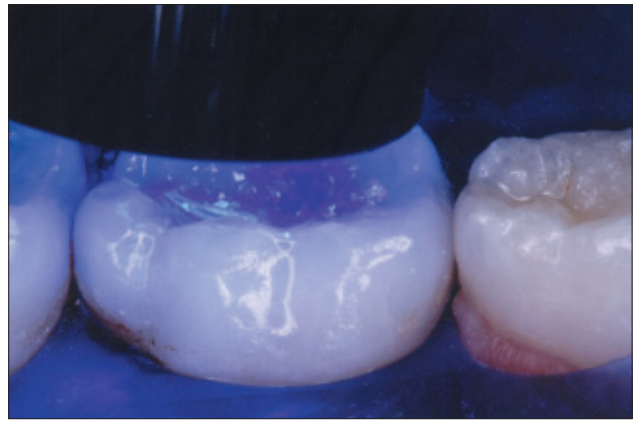

Figure 5. The initial light beam is applied.

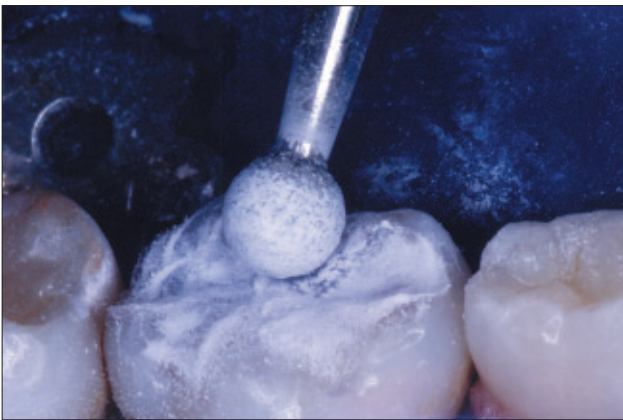


Figure 6. After the final increment is placed and cured, a large, round diamond bur at slow speed shapes the occlusal surface.

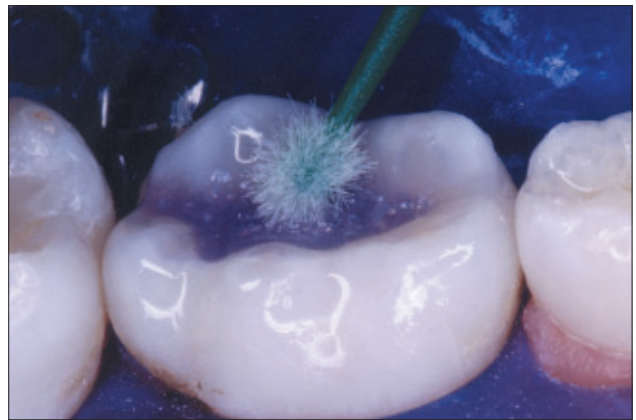

Figure 7. Clear sealant is applied after 15 second-application of the self-etching adhesive solution.

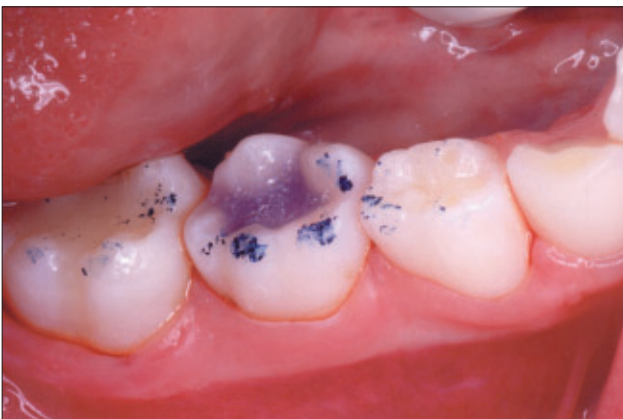

Figure 8. Occlusal contacts are evaluated.

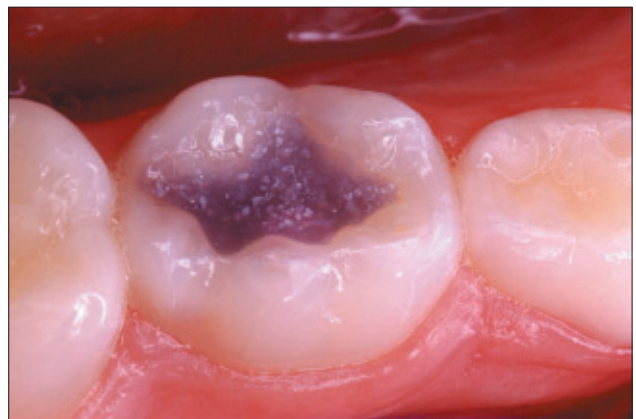

Figure 9. Occlusal MagicFil restoration observed 10 months after placement.

models, to teach children and parents about the restorative process and colored glittery compomer material (Figure 12). These models are educational and save much time that would otherwise be needed for a verbal or photographic description.

Because compomers contain glass filler particles and polyacid components in the resin framework, a modified acid base neutralization reaction occurs within the resin

mass, once the hardened material is saturated with saliva. A result of this mechanism is that fluoride ion is released and available for take-up by associated tooth structure. Studies to evaluate the amount of fluoride ion release from MagicFil and its effects on associated dentin and enamel should be performed.

Experience in the first year of use of this “colored kiddie compomer” has shown that it can be used for Class I, Class

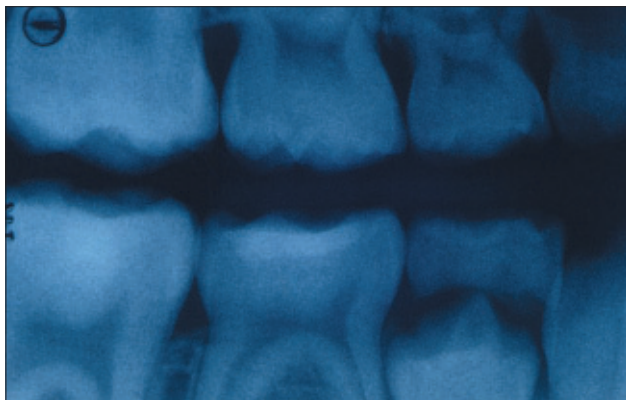


Figure 10. Bite-wing film recorded 10 months postoperatively shows radiopacity of the colored compomer.

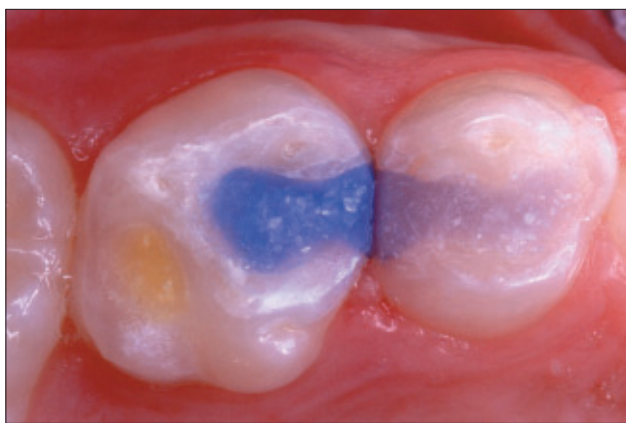


Figure 11. Purple and blue Class II restorations and yellow Class I restoration in an 8-year-old, 12 months after placement.

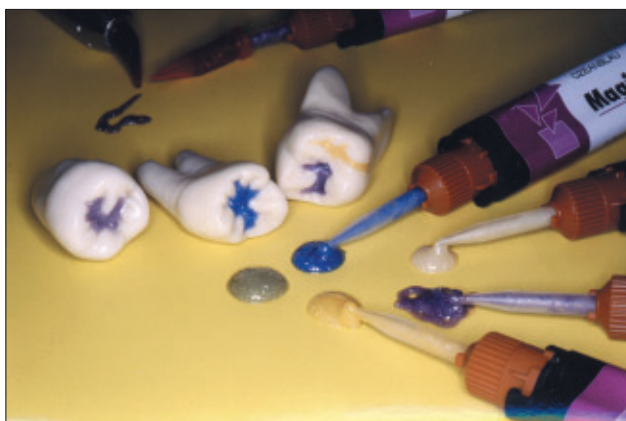

Figure 12. MagicFil sample restorations in artificial teeth are excellent educational models for children and parents.

II, and Class V primary tooth restoration (Figure 11). The authors have not used MagicFil for Class III, Class IV or full crown restorations. In preparations with minimal dentinal involvement, the total-etch technique (acid etching of dentin as well as enamel) can be used. A light-cured resin-modified glass ionomer dentin replacement liner/base is preferred in teeth with significant dentinal loss.^{2,3} Such "stratified" restorations eliminate post-operative sensitiv-

ity and the need for a complicated dentin/resin bonding protocol.

The dual-cure feature of MagicFil is unique. Other compomers undergo resin polymerization only by light exposure. The 2-component colored compomer is blended thoroughly while being injected through the mixing tip of the double-barreled syringe, thus initiating chemical polymerization. Self-curing gives assurance that material hardening will occur within 5 minutes throughout the resin mass, even if radiant energy from the light beam fails to penetrate completely.

Another multi-colored compomer with glitter inclusions has appeared recently in dental products journals. The product, called Twinky Star, is manufactured by VOCO GMBH, Cuxhaven, Germany. According to recent advertisements, the Twinky Star compomer is available in 7 colors (gold, silver, blue, pink, green, orange, and lemon), each containing glitter inclusions. Unlike MagicFil, Twinky Star hardens only by photopolymerization; it does not have a chemical resin-curing reaction. At the time of this writing (December 2002), the authors have not had any clinical experience with Twinky Star.

Disclosure

The authors have no financial interest in any product or company mentioned in this article.

References

1. Croll TP. Alternatives to silver amalgam and resin-composite in pediatric dentistry. *Quintessence Int.* 1998;29:697-703.
2. Paterson RC, Watts A, Saunders, WP, Pitts NB. Laminate restorations. In: *Modern Concepts in the Diagnosis and Treatment of Fissure Caries*. Chicago/L Berlin: Quintessence Publishing Co, Ltd; 1991:66-72.
3. Croll TP, Cavanaugh RR. Posterior resin-based composite restorations: A second opinion. *Journal of Esthetic and Restorative Dentistry.* 2002;14:303-312.
3. Kanemura N, Sano H, Tagami J. Tensile bond strength to and SEM evaluation of ground and intact enamel surfaces. *J Dent.* 1999;27:523-530.

Copyright of Pediatric Dentistry is the property of American Society of Dentistry for Children and its content may not be copied or emailed to multiple sites or posted to a listserv without the copyright holder's express written permission. However, users may print, download, or email articles for individual use.