



# Dentoalveolar Trauma in a Patient With Chronic Idiopathic Thrombocytopenic Purpura: A Case Report

David Finucane, BA, BDentSc, FFDRCSI, MSc    Padraig Fleming, BA, BDentSc, FFDRCSI, FDSRCSEd MSc,  
Owen Smith, MA, MB, FRCPath, FRCPI, FRCPEd, FRCPH

*Dr. Finucane is lecturer in pediatric dentistry, Dublin Dental School and Hospital, Dublin, Ireland; Dr. Fleming is consultant pediatric dentist, Our Lady's Hospital for Sick Children, Dublin, and Dublin Dental School and Hospital, Dublin; Dr. Smith is consultant pediatric hematologist, Our Lady's Hospital for Sick Children, Dublin.*  
*Correspond with Dr. Finucane at dfinucan@dental.tcd.ie*

## Abstract

A case is presented of a 13-year-old boy with chronic idiopathic thrombocytopenic purpura (ITP) who sustained traumatic labial luxation of both lower central incisors, with partial alveolar fracture resulting in displacement of the labial alveolar plate. Intravenous immunoglobulin (Fleibogamma, 1 g/kg body weight  $\times$  2 days) was administered, resulting in the patient's platelet count rising from 15,000/mm<sup>3</sup> to 70,000/mm<sup>3</sup>. Under general anesthesia, the displaced lower labial alveolus and luxated teeth were repositioned and splinted 2 days following trauma. Healing was uneventful. Subsequently, both lower central incisors became nonvital and were endodontically treated. The dental treatment of this patient with ITP is discussed in terms of emergency management, and subsequent care. (*Pediatr Dent.* 2004;26:352-354)

**KEYWORDS:** IDIOPATHIC THROMBOCYTOPENIC PURPURA, PLATELETS, BLEEDING, IMMUNOGLOBULINS, AUTOIMMUNE, DENTAL, TRAUMA

*Received June 9, 2003    Revision Accepted March 30, 2004*

Idiopathic thrombocytopenic purpura (ITP), also known as immune thrombocytopenic purpura and primary immune thrombocytopenic purpura, is a hemorrhagic disorder characterized by abnormally increased destruction of circulating platelets. ITP is accompanied by marrow megakaryocyte hyperplasia. It is the most common cause of thrombocytopenia in childhood, with an incidence of approximately 4:100,000/year.<sup>1-3</sup>

The pathogenesis of acute ITP is often regarded as a consequence of inappropriate immune recovery after an infection. Circulating antigens or antibodies may alter the platelet membrane. Alternatively, immune complexes derived from primary or underlying disease processes may nonspecifically absorb to platelet surfaces, resulting in opsonisation and destruction of young platelets. Chronic ITP can be attributed to autoantibodies directed against platelet constituents such as glycoproteins.<sup>2,4,5</sup>

Complete ITP remission occurs in more than 90% of children after 6 months, independent of treatment.<sup>1,5,6</sup> The 5% to 10% of children who do not remit have chronic ITP. Children who develop chronic ITP are mostly over 7 years of age and rarely have postinfection ITP.

Medical management by a hematologist is indicated in children and adolescents either at risk of or demonstrating overt signs of bleeding.<sup>1,7</sup> The ITP therapy focuses on measures modulating the immune response and includes IV immunoglobulin, anti-Rh (D) immunoglobulin, or immunosuppressive treatment with corticosteroids.<sup>1,2,5,7</sup>

## Dental management of patients with ITP

The main danger in dental treatment of ITP is hemorrhage. Patients with severe thrombocytopenia require hospitalization and special preparation for surgery. The patient's hematologist should be involved with the diagnosis, presurgical evaluation, preparation, and postsurgical management of these patients.<sup>8</sup>

Hemostatic cover may be required prior to surgery and, if needed, should be administered by the hematologist. In ITP patients, the bleeding tendency is sometimes effectively controlled with short-course, high-dose corticosteroids.<sup>7,9</sup>

Intravenous gamma globulin (IVIg) is recommended for children with platelet counts below 20,000/mm<sup>3</sup> prior to surgery. This will increase platelet count to more than 50,000/mm<sup>3</sup> within 48 hours in approximately 90% of cases.<sup>1,8</sup>



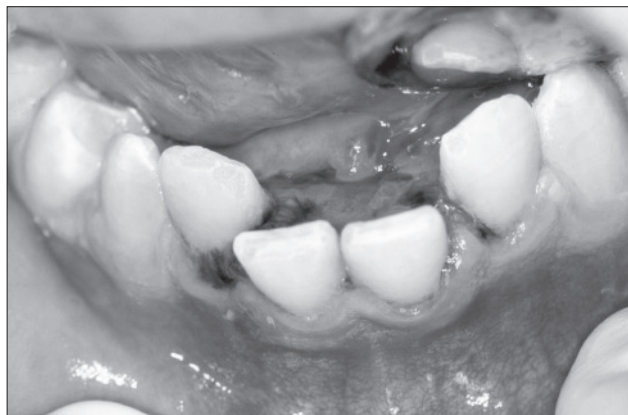


Figure 1. Patient on presentation. Note luxation of permanent lower central incisors and lingual hematoma.

Platelet transfusions play little part in ITP management, as they are rapidly destroyed. Life-threatening hemorrhage is the only extraordinary circumstance where platelets are appropriate.<sup>1</sup>

For thrombocytopenic patients, the platelet count should be at least 50,000/mm<sup>3</sup> before elective surgery is performed. With platelet levels above 50,000/mm<sup>3</sup>, hemorrhage following minor surgery is unlikely. Nonetheless, local hemostatic measures should be employed to enhance clot formation following dental extraction. Such measures may include application of pressure packs, dressings, and sutures and/or application of local hemostatic agents (gelatine sponge, oxidised cellulose, synthetic collagen, microfibrillar collagen).<sup>8-11</sup>

Regional anesthetic block injections are contraindicated if the platelet levels are below 30,000/mm<sup>3</sup>, unless hemostatic cover has been provided, as bleeding in the pterygomandibular region may compromise the airway.<sup>9</sup>

Local infiltration of anaesthetic, intraligamental injections and endodontic therapy of nonvital teeth can usually be performed safely without hemostatic cover, so long as overinstrumentation and overfilling are avoided.

Complex restorative procedures usually require hemostatic cover, and care must be taken to avoid trauma to the tissues when placing wedges, bands, and archwires. Conservative periodontal procedures, including polishing and supragingival scaling, can often be performed without hemostatic cover. Drugs that affect platelet function, particularly aspirin, should be avoided.<sup>8,9,11</sup>

### Case report

A case is presented of a 13-year-old boy with chronic ITP who sustained labial luxation of both permanent lower central incisors—with partial alveolar fracture resulting in displacement of the labial alveolar plate—as a result of a fall (Figures 1, 2). He presented to the emergency room 2 hours later, complaining of oral bleeding, and was seen by a dentist. Bleeding was controlled by pressure with damp gauze. The patient was admitted to a hospital, under the care of the consultant pediatric hematologist, where his condition could be monitored. Emer-

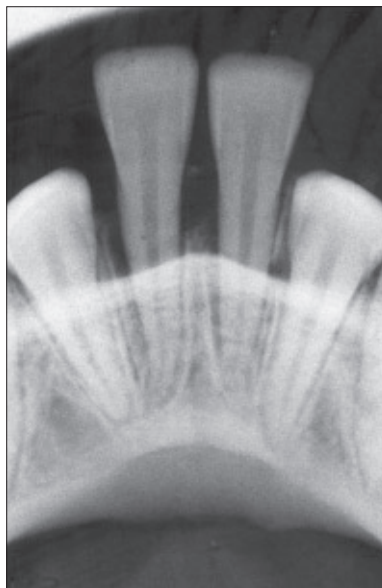

Figure 2. Radiograph showing luxation of permanent lower central incisors.

gency treatment was available in case of serious hemorrhage, which did not occur.

Arrangements were made to reposition the teeth under general anesthesia, following consultation with the hematology team. To avoid the risk of further hemorrhage, the patient's displaced teeth and alveolar plate could not be repositioned until his platelet count had risen above 50,000/mm<sup>3</sup>

(2 days following trauma). By this time, some healing had occurred. It was anticipated that some force might be required to allow optimum repositioning of the injured teeth and alveolus. As the child had been quite distressed by the accident, treatment under general anaesthesia was considered appropriate.

Following intravenous administration of immunoglobulin (Fleibogamma 1 g/kg body weight  $\times$  2 days), the patient's platelet count rose from 15,000/mm<sup>3</sup> to 70,000/mm<sup>3</sup>. Two days following the accident, the displaced alveolus and teeth were repositioned and splinted under general anesthesia, using a composite resin splint bonded to the labial surface of all lower incisors (Figure 3). Healing was uneventful and the splint was removed after 2 weeks.<sup>12-14</sup>

The patient was reviewed every 3 months, as it was considered likely that the repositioned teeth would become nonvital. Eventually, loss of vitality of both permanent lower central incisors was confirmed, by negative response to thermal and electrical vitality tests and

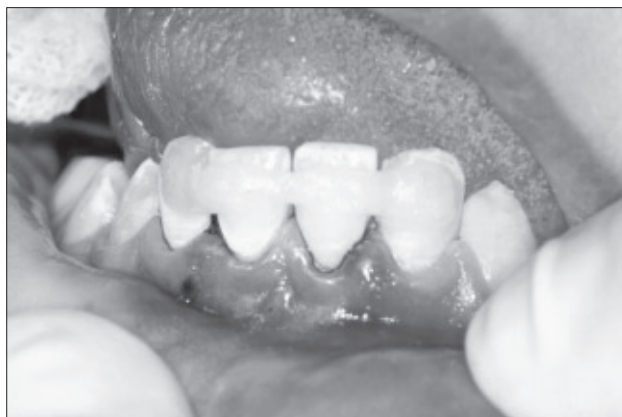

Figure 3. Permanent lower central incisors repositioned and splinted with composite resin.



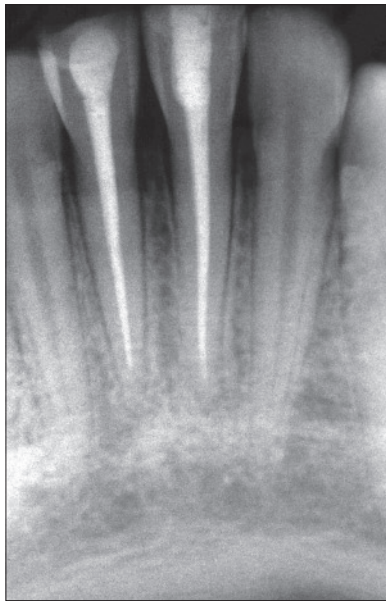


Figure 4. Permanent lower central incisors eventually lost vitality and were endodontically treated.

evidence of apical radiolucency, and endodontic treatment was performed (Figure 4).

### Discussion

In a patient whose platelet count is greater than  $50,000/\text{mm}^3$ , little, if any, clinical bleeding is expected during minimally invasive dental treatment. When the platelet count is below  $30,000/\text{mm}^3$ , however, bleeding following dental procedures may be difficult to control. Regional anesthesia, such as a mandibular

block, is contraindicated unless hemostatic cover with platelet concentrate, immunoglobulin infusion, or both—depending on the etiology of the thrombocytopenia—has been provided.<sup>8-11</sup> In this case, the patient's severe thrombocytopenia ( $15,000/\text{mm}^3$ ) at the time of trauma was felt to be immune mediated. It was necessary, therefore, to delay surgical repositioning of the displaced alveolus and teeth until a platelet rise was achieved following administration of intravenous immunoglobulin (IVIg). By day 2, following IVIg commencement, the platelet count had risen to  $70,000/\text{mm}^3$ , and the surgical procedure was carried out.

Alternatives to the chosen method of repositioning the traumatized teeth would have been to:

1. allow spontaneous repositioning by pressure from the lower lip; or
2. orthodontically reposition the displaced teeth.<sup>15</sup>

As IVIg was administered to control the patient's oral bleeding, it was decided to use the opportunity afforded by the resultant rise in platelets to reposition the teeth, knowing that this could be done without risk of subsequent problems due to hemorrhage.

No intervention from the hematology team was required for the subsequent endodontic treatment of the lower central incisors. Mandibular block anesthesia was not needed because the teeth were preoperatively determined to be nonvital. Rubber dam was placed atraumatically, using rubber Wedgets (Hygienic, Coltène/Whaledent, NJ) rather than clamps to secure it. Treatment was completed without recourse to local anesthesia, care being taken not to instrument beyond the apices. Bleeding was not a problem, as the pulps of both permanent lower central incisors were necrotic.

### Conclusions

A comprehensive care approach is needed when treating traumatic injury in patients with documented bleeding disorders. In an emergency situation, as illustrated here, close cooperation between the patient's dentist and hematologist is needed to deliver care appropriately and safely. This case illustrates the successful outcome of such an approach.

### References

1. Lilleyman JS. Management of childhood idiopathic thrombocytopenic purpura. *Br J Haematol*. 1999;105:871-875.
2. Bolton-Maggs PHB. Idiopathic thrombocytopenic purpura. *Arch Dis Child*. 2000;83:220-222.
3. Hunter ML, Hunter B. Acute idiopathic thrombocytopenic purpura in childhood: Report of a case presenting in general practice. *Br Dent J*. 1997;1:27-29.
4. Ripamonti U, Petit J-C, Penfold G, Lemmer J. Periodontal manifestations of acute immune thrombocytopenic purpura. *J Periodontol*. 1986;57:429-432.
5. Lissauer T, Clayden G, eds. *Illustrated Textbook of Paediatrics*. London: Mosby; 1997:243-244.
6. Dickerhoff R, von Ruecker A. The clinical course of immune thrombocytopenic purpura in children who did not receive intravenous immunoglobulins or sustained prednisone treatment. *J Paediatr*. 2000;137:629-632.
7. George JN, Woolf SH, Raskob GE, et al. Idiopathic thrombocytopenic purpura: A practice guideline developed by explicit methods for the American Society of Hematology. *Blood*. 1996;88:3-40.
8. Little JW, Falace DA, Miller CS, Rhodus NL, eds. *Dental Management of the Medically Compromised Patient*. 6th ed. St Louis: Mosby; 1997:332-364.
9. Scully C, Cawson RA, eds. *Medical Problems in Dentistry*. 4th ed. Oxford: Wright Publ; 2001:82-105.
10. Grundy MC, Shaw L, Hamilton DV, eds. *Illustrated Guide to Dental Care for the Medically Compromised Patient*. London: Wolfe Publ; 1993:30.
11. Johnson WT, Leary JM. Management of dental patients with bleeding disorders: Review and update. *Oral Surg Oral Med Oral Pathol*. 1988;66:297-303.
12. Andreasen JO, Andreasen FM, *Essentials of Traumatic Injuries to the Teeth*. 2nd ed. Copenhagen: Munksgaard; 2000:85-101.
13. American Association of Endodontists. Recommended Guidelines for the Treatment of Traumatic Dental Injuries, 2003;12:4.
14. International Association of Dental Traumatology. Guidelines for the treatment of luxation injuries. *Dent Traumatol*. 2001;17:145-148.
15. Andreasen JO, Andreasen FM, eds. *Textbook and Color Atlas of Traumatic Injuries to the Teeth*. 3rd ed. Copenhagen: Munksgaard; 1994:336,340.



Copyright of Pediatric Dentistry is the property of American Society of Dentistry for Children and its content may not be copied or emailed to multiple sites or posted to a listserv without the copyright holder's express written permission. However, users may print, download, or email articles for individual use.