



Anterior Fiber-reinforced Composite Resin Bridge: A Case Report

Amir Chafaie, DDS Richard Portier, DDS, PhD

*Dr. Chafaie is senior lecturer, and Dr. Portier is senior lecturer and head, Department of Paediatric Dentistry, Marseille, France.
Correspond with Dr. Chafaie at amir.chafaie@wanadoo.fr*

Abstract

A variety of therapeutic modalities, from implants to conventional Maryland bridges, can be used for the replacement of a traumatically missing anterior tooth. The reinforcement of composite resins by fibers improves their fracture toughness and resistance. Fiber-reinforced composite (FRC) bridges can be a good alternative to conventional prosthetic techniques. The purpose of this article was to present a clinical case of a single tooth replacement by means of a polyethylene FRC bridge. A semi-direct technique was used to fabricate a Maryland-like composite bridge for the replacement of a missing central permanent incisor. The bridge fabrication was done in the dental office using a fast-setting polyvinylsiloxane die material and a state-of-art restorative composite resin. This technique offers a conservative, esthetic, and noninvasive treatment. Moreover, this technique is economically more acceptable, nonirritating, and noniatrogenic. Polyethylene FRC bridges can be considered as a permanent treatment or, in the case of implant placement after the end of the growth period, as a long-lasting reversible provisional treatment. (*Pediatr Dent.* 2004;26:530-534)

KEYWORDS: CASE REPORT, COMPOSITE RESIN, POLYETHYLENE, ESTHETICS

Received December 16, 2003 Revision Accepted August 4, 2004

Different therapeutic options can be considered for the replacement of a congenitally or traumatically missing permanent incisor in young children and adolescents.¹

Implants are the treatment of choice and should be considered when general and local conditions are favorable. Their use is generally not intended before the end of the growth period and around the age of 18. Because of their high cost, poor financial condition could also limit their use. More economically acceptable treatments should, therefore, be investigated for the replacement of a missing tooth, as a main treatment or as a long-term provisional treatment before implant therapy.

Partial removable dentures are often recommended for very young patients when adjacent teeth are not in their final vertical and horizontal positions. These dentures could be modified when necessary by adding or grinding the acrylic resin. They are not comfortable, however, and are frequently subjected to fracture. When an orthodontic treatment is indicated, an artificial plastic tooth can be attached to a removable or fixed orthodontic appliance to solve the esthetic concern.

The replacement of a missing tooth can also be made via a conventional porcelain-fused-metal (PFM) bridge or a resin-bonded fixed partial denture (Maryland bridge). The former is the most invasive treatment in terms of tooth reduction and could be aesthetically compromised with gingival contour modifications. The latter is less invasive, but the nonesthetic aspect of the metal framework, necessity of dental reduction or preparation (grooves, etc.), challenging long-lasting bonding of metal to tooth, and lack of longevity could limit its use.

The fiber-reinforced composite (FRC) bridges represent an interesting alternative to conventional metal bridges.² They could be made directly or indirectly using an artificial plastic tooth or the avulsed tooth,^{3,4} or by a direct build up composite resin tooth with^{5,6} or without⁷ porcelain veneering.

Whenever possible, a FRC bridge should be fabricated extraorally to achieve better polish, polymerization conversion rate, and adaptation. The material used for the cast fabrication can be conventional gypsum materials. Two appointments are, therefore, necessary for this indirect technique. Moreover, the separation of the final work from the cast could be delicate if undercuts are filled by composite resin.

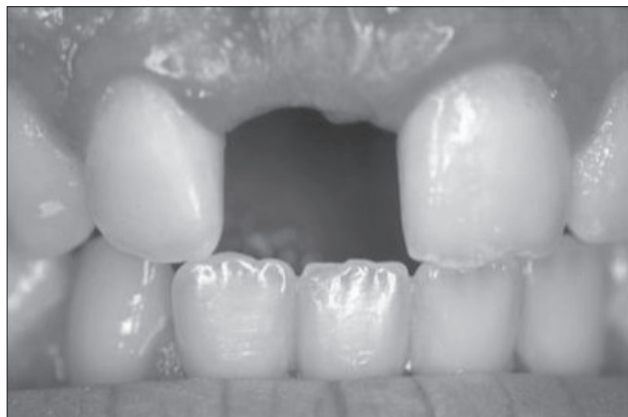

Figure 1. Preoperative frontal view of a 16-year-old boy with a missing right maxillary central incisor.

The use of a fast-setting silicone die material instead of conventional gypsum materials has been proposed for composite inlay and onlay fabrication.^{8,9} The silicone model, obtained in a few minutes, allows a chairside fabrication of indirect composite restorations. Also called semidirect, this technique combines the advantages of an indirect technique with those of a direct technique.

The new generation of composite resins with dentin and enamel shades provides very good aesthetic results by reproducing the natural aspect of the tooth, mainly in the incisal third of anterior teeth.¹⁰

The use of unreinforced composite resins as the structural material for bridges often results in fracture. Composites are brittle materials and contain bubbles, cracks, and other defects causing or facilitating fissure propagation and fracture.¹¹ It has been demonstrated that the reinforcement of a composite resin by fibers increases the fracture toughness and resistance.¹² The combination of an esthetic, wear-resistant composite resin, and tough fiber material gives a new option for short-span composite bridge fabrication.¹³

This article describes a clinical case in which an (FRC) bridge is fabricated according to the semidirect technique for the replacement of a traumatically missing central permanent incisor.

Case report

A 16-year-old boy was referred by his orthodontist to the faculty practice clinic at the Department of Pediatric Dentistry of Marseille University, Marseille, France. His orthodontic treatment had been completed a few months before this visit.

The boy's medical history revealed no specific problem. His dental history indicated a traumatic accident, at the age of 12, responsible for the extraction of the central right maxillary permanent incisor.

The intraoral examination revealed a removable splint appliance with an attached plastic tooth replacing the missing central incisor. The esthetic aspect of this tooth was rated unsatisfactory by the patient, who asked for a more esthetic and comfortable treatment. The removable acrylic

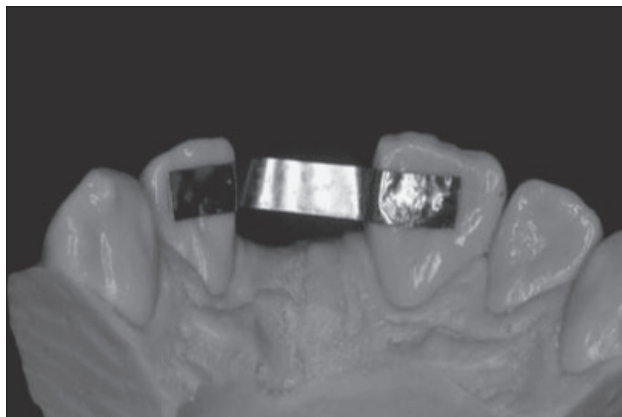


Figure 2. Length measurement with a thin foil on the silicone cast.

splint appliance had been repaired several times, mainly in the middle anterior region (the junction between the tooth and acrylic resin). The orthodontic treatment had been accomplished to manage sufficient height at the lingual side of maxillary abutment teeth (Figure 1). All therapeutic options, from implant to conventional Maryland bridge, were, therefore, possible in this case. This fact underlines the importance of the final prosthetic treatment decision when establishing an orthodontic treatment plan.

After discussing all treatment options with the patient and his parents, the placement of a single implant tooth for the replacement of the missing natural tooth was decided when the boy turned 18. The immediate implant treatment was not possible because of the family's financial situation. It had been decided to place a fiber-reinforced composite Maryland-like bridge until the implant treatment. No tooth reduction was necessary because the anterior overbite was minor.

An impression was made with alginate for the FRC bridge fabrication. In this case, it was not necessary to take a full-arch impression because there was no need to have the opposite model and procedure with an articulating technique. A short-span impression reduces the tension inside the alginate and provides a more accurate result.

The impression was poured with the polyvinylsiloxane die material (Quick Die, Bisco, Schaumburg, Ill). A polyethylene plasma-treated fiber system (Ribbon THM, Ribbon Inc, Seattle, Wash) was used for the bridge framework fabrication.

The length measurement was conducted with thin dead soft foil. This foil was closely adapted to the working cast (Figure 2). The foil extended to the middle thirds of each abutment and crossed the pontic area directly under the incisal edge.

The foil was flattened and used as a pattern, against which the exact length of the ribbon needed was measured. The use of special scissors allowed it to be cut consistently and cleanly. One should avoid touching the ribbon until after it is wetted with bonding resin via the fingers, because any contact can contaminate its reactive surface layer.

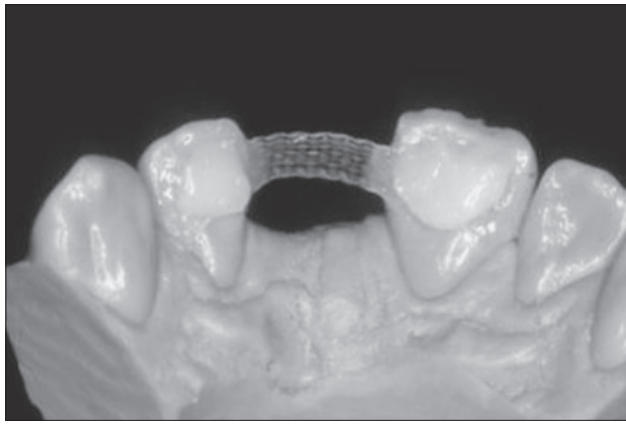


Figure 3. The framework was placed using a microhybrid restorative composite. A new layer of composite resin was used to smooth the outer surface.

The reinforcement material was impregnated with a hydrophobic solvent-free bonding resin (D/E Bonding Resin, Bisco, Schaumburg, Ill). Following the impregnation with the bonding resin, the fiber material became translucent. The excess unfilled bonding resin was blotted with a gauze. The ribbon was kept out of the dental light until used.

A thin layer of a microhybrid restorative material was placed on the lingual side of the abutment teeth. This composite acted as a glue and held the ribbon during its adaptation. The use of flowable composites should be avoided in this stage. Using instruments, the ribbon was pushed through the uncured composite layer until it touched the surface of the die material. Like the foil, the ribbon crossed the pontic area under the incisal edge, going from the labial lingual midline of each abutment.

Once adapted, excess composite was removed before light curing. The thickness of the composite between the teeth and ribbon was kept as thin as possible. The ribbon wings and beam were light cured for 40 seconds to form a strong framework for the FRC bridge fabrication. A second piece of the ribbon was used in the pontic region at this stage. It went to the proximal lingual surface angle of each abutment. A small amount of the same restorative composite was placed to cover the wings of the bridge (Figure 3). If necessary, a drop of solvent-free bonding resin could be used as modeling agent. This helps to dilute the composite. A silicone spatula was used to model the composite and obtain a very thin layer of the covering composite. This technique provided a bubble-free and harder surface in comparison to the use of a flowable composite as the smoothing layer.

The composite pontic was built around the composite laminate framework. To obtain a good natural esthetic result, a composite restorative system (Enamel Plus HFO, Micerium, Avegno, Italy) containing different enamel and dentin shades was used.

Dentin shades, responsible for the opacity, hue, and chroma, were placed internally and then covered by enamel shades. A special opalescent enamel shade was placed between dentin mamelons to reproduce the blue/gray color seen at the incisal third of the adjacent tooth. Enamel

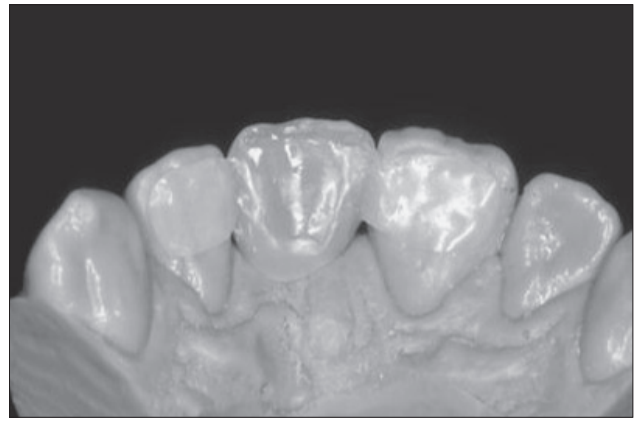


Figure 4. Final view of the finished bridge.

shades, responsible for the tooth's final value were then placed buccally and lingually.

After the last layer's placement and modeling and the final light curing, the bridge was easily removed from the slightly elastic silicone model without any stress or model breakage. The bridge was finished and polished with appropriate instruments (Figure 4).

The bridge was inserted into the mouth to check its fit. It was rinsed with alcohol to remove any traces of polishing pastes, then rinsed with water and air dried. The internal side of the wings was acid-etched (Porcelain Etch, Ultradent, South Jordan, Utah) for 1 minute and then thoroughly rinsed and completely air dried. A porcelain primer (Silane, Ultradent, South Jordan, Utah) was then applied for 30 seconds and air dried. Two layers of a universal 1-bottle adhesive (One Step, Bisco, Schaumburg, Ill) was then applied, thoroughly air dried for 15 seconds, and light cured for 10 seconds.

After proper isolation of the teeth, all dental surfaces to be bonded were cleaned with a slurry of pumice, rinsed, and completely air dried. Enamel surfaces were etched with 32% phosphoric acid (Uni Etch, Bisco, Schaumburg, Ill) for 30 seconds. After rinsing, all surfaces were air dried, visually inspected for proper acid etching and covered by 2 layers of a universal 1-bottle adhesive (One Step, Bisco, Schaumburg, Ill). The adhesive layer was air dried and light cured for 10 seconds.

A thin layer of dual-cured luting composite (Duo-Link, Bisco, Schaumburg, Ill) was placed on the wings' internal surface. The bridge was inserted slowly and continuously. Once in place, it was held firmly in position. Excess cement was removed using a probe and brush. The bridge was then light cured for 2 minutes in different directions.

Occlusion was checked at this time before intraoral finishing and polishing. The final result was a well-adapted bridge with a natural esthetic result (Figures 5 and 6).

Discussion

The replacement of a congenitally or traumatically missing permanent anterior tooth could be performed via different therapeutic options. Fixed FRC bridges represent one of

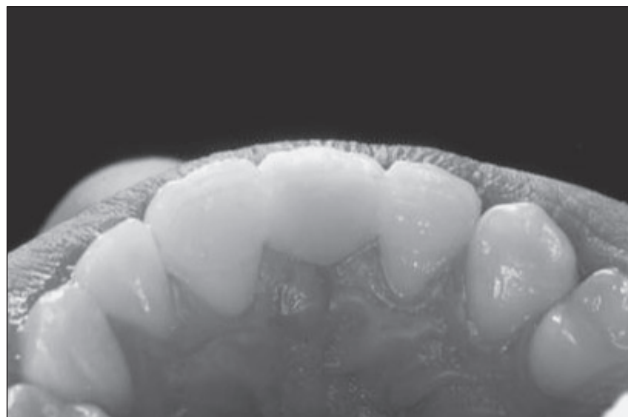


Figure 5. Final lingual view of the bridge after bonding, finishing, and polishing.

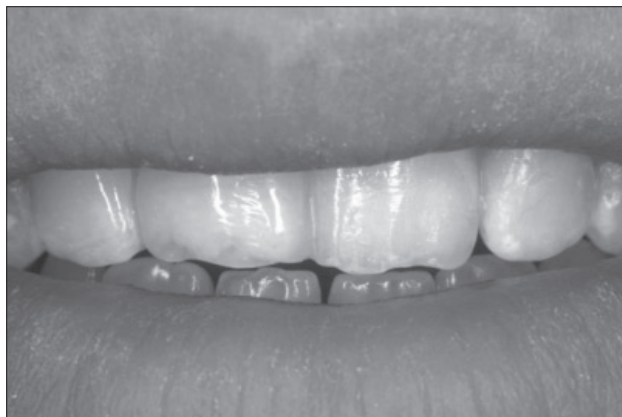

Figure 6. Final facial view of the bridge.

these options, with many advantages including bondability, reparability, ease of fabrication, and relative longevity. This is considered a noninvasive or minimally invasive procedure with very little or no tooth reduction. Compared to traditional prosthetic options, a fiber-reinforced composite bridge is generally less costly and labor intensive.

Compared to direct technique, the indirect technique described in this article provides a better result in terms of adaptation, rate of polymerization, and final smoothness of the bridge. With a direct technique, it is very difficult to control and avoid the composite excess in embrasures and undercuts. After curing, the composite can only be removed by rotary instruments. The use of burs is time consuming, imprecise, and possibly invasive. The lack of visibility and access could lead to fiber exposition during finishing and polishing procedures.

The fabrication of an FRC bridge by using a flexible die model brings many advantages in comparison with traditional indirect technique. The die material is a fast-setting silicone and allows for the obtaining of a cast model in a few minutes. A chairside FRC bridge fabrication could be performed easily, reducing lab fees and time. The elasticity of this model allows for the easy removal of the final work without weakening or breakage of the bridge. Moreover, the FRC bridge fabrication can immediately be undertaken with no required isolation.

Plasma-treated polyethylene fibers reinforce the final structure by being a physical part of the composite. Compared to metal-framed Maryland bridge, an FRC bridge is easier to bond, more esthetically pleasing with no metal shadow, and does not show through the very translucent dental hard tissues in young permanent teeth. A close collaboration with the orthodontist can provide the best local conditions (occlusal relationship) to ensure a long-lasting result.

The use of different dentin and enamel composites to build up the intermediate tooth according to the anatomical layering technique provides a vital final aspect, with natural opalescence, translucency, and opacity. The use of a denture tooth could also be considered instead of direct fabrication of the missing tooth. This method is easier, faster, and, in some

cases, more esthetically acceptable than the direct fabrication of a tooth. The shape and the incisal color of denture teeth are, in some cases, however, difficult to match to the adjacent teeth. Moreover, the interface between the restorative composite covering the beam and artificial tooth could weaken the bridge and lead to fracture in this region.

Conclusions

FRC bridge fabrication technique presented in this article suggests a new treatment option for the replacement of a missing anterior tooth. This technique restores esthetic and function. It is more comfortable than a removable appliance, nonirritating, and hygienic. Generally, it does not require any tooth reduction and could be repaired, modified, or removed from teeth without any iatrogenic problem.¹⁴ It can be considered a permanent treatment or a long-lasting provisional treatment if implant therapy is used at a later date. In this case, the noninvasive characteristic of this treatment render it superior to all other options.¹⁵

References

1. Marinello CP, Meyenberg KH, Zitzmann N, Luthy H, Soom U, Imoberdorf M. Single-tooth replacement: Some clinical aspects. *J Esthet Dent*. 1997;9:169-178.
2. Vallittu PK. Survival rates of resin-bonded, glass fiber-reinforced composite fixed partial dentures with a mean follow-up of 42 months: A pilot study. *J Prosthet Dent*. 2004;3:241-246.
3. Nixon RL, Weinstock A. An immediate-extraction anterior single-tooth replacement utilizing a fiber-reinforced dual-component bridge. *Pract Periodontics Aesthet Dent*. 1998;10:17-26.
4. Belli S, Ozer F. A simple method for single anterior tooth replacement. *J Adhes Dent*. 2000;2:67-70.
5. Feinman RA, Smidt A. A combination porcelain/fiber-reinforced composite bridge: A case report. *Pract Periodontics Aesthet Dent*. 1997;9:925-929.
6. Miller MB. Aesthetic anterior reconstruction using a combined periodontal/restorative approach. *Pract Periodontics Aesthet Dent*. 1993;5:33-40.

7. van Wijlen P. A modified technique for direct, fibre-reinforced, resin-bonded bridges: Clinical case reports. *J Can Dent Assoc.* 2000;66:367-371.
8. Trushkowsky RD. One visit composite onlay utilizing a new flexible model material. *Am J Dent.* 1997;10:55-6.
9. Tay FR, Wei SH. Indirect posterior restorations using a new chairside microhybrid resin composite system. *J Adhes Dent.* 2001;3:89-99.
10. Vanini L. Light and color in anterior composite restorations. *Pract Periodontics Aesthet Dent.* 1996;8:673-682.
11. Rudo DN, Karbhari VM. Physical behaviors of fiber reinforcement as applied to tooth stabilization. *Dent Clin North Am.* 1999;43:7-35.
12. Pfeiffer P, Grube L. In vitro resistance of reinforced interim fixed partial dentures. *J Prosthet Dent.* 2003;89:170-174.
13. Fahl N Jr. Restoration of the maxillary arch utilizing a composite resin buildup and a fiber framework. *Pract Periodontics Aesthet Dent.* 1998;10:363-367.
14. Karaman AI, Kir N, Belli S. Four applications of reinforced polyethylene fiber material in orthodontic practice. *Am J Orthod Dentofacial Orthop.* 2002;121:650-654.
15. Smidt A. Esthetic provisional replacement of a single anterior tooth during the implant healing phase: A clinical report. *J Prosthet Dent.* 2002;6:598-602.

ABSTRACT OF THE SCIENTIFIC LITERATURE



POISON TREATMENT IN THE HOME

Until recently, the American Academy of Pediatrics (AAP) and its Committee on Injury, Violence, and Poison Prevention have recommended that a 1-oz bottle of syrup of ipecac be kept in the home. This “safe” emetic was only to be used on the advice of a physician or poison control center following ingestion of a potentially poisonous substance by a young child. From its inception, this recommendation has been controversial, especially since ipecac was widely accepted and utilized prior to its efficacy and validity having been proven and established. Groups such as the American Academy of Clinical Toxicology and the European Association of Poison Centres and Clinical Toxicologists stated that the routine use of ipecac in the emergency department should be abandoned. Research has shown incomplete removal from the stomach, even when ipecac is administered immediately following the ingestion of a substance and the amount of a substance removed is inversely related to the duration of time from its ingestion to emesis. Aside from ipecac syrup’s adverse effects, which include vomiting, lethargy, and diarrhea, of greater concern is its administration when not indicated. This most often results when a health care professional has not been consulted, which in one case study, involved 61% of the children treated. Intentional misuse by children with eating disorders further complicates the presence of ipecac in the home and increases the risk of inappropriate use. Activated charcoal has been suggested as an alternative to ipecac due to its effectiveness in reducing the bioavailability of ingested substances. This method is poorly accepted by young children, which results in a subtherapeutic dose. Because it is often vomited and very messy, caregiver acceptance is an issue as well. Like ipecac, charcoal may be inappropriately overused. Hence, there should be clear evidence for patient benefit before its implementation as a public health intervention.

After reviewing the evidence, the AAP believes that: (1) ipecac should no longer be used routinely as a home treatment strategy; (2) existing ipecac in the home be disposed of safely; and (3) it is premature to recommend the administration of activated charcoal in the home. The caregiver of a child who may have ingested a toxic substance should first consult immediately with a local poison control center.

Comments: Many practicing pediatric dentists and pediatric dental clinics continue to keep ipecac syrup in their emergency drug kit. Following this policy statement by the AAP, it would appear that “best practice” indicates ipecac’s removal and safe disposal from all pediatric dental offices and clinics’ emergency drug kits. The most important aspect regarding treatment of poisoning is prevention. If the ingestion of a potentially poisonous substance by a young child should occur, however, whether in the dental office or at home, the caregiver’s first action should be to consult immediately with a local poison control center by calling (800) 222-1222. ET

American Academy of Pediatrics, Committee on Injury, Violence, and Poison Prevention. Poison treatment in the home. *Pediatrics.* 2003;112:1182-1185.

29 references

Copyright of Pediatric Dentistry is the property of American Society of Dentistry for Children and its content may not be copied or emailed to multiple sites or posted to a listserv without the copyright holder's express written permission. However, users may print, download, or email articles for individual use.