



Simple Treatment of Ectopic Eruption With a Triangular Wedging Spring

Yong Heon Kim, DDS¹ Ki Tae Park, DDS, MS, PhD²

Abstract

The purpose of this clinical report was to introduce a simple and effective way of performing ectopic eruption treatment utilizing a triangular wedging spring. This consists of 3 helical loops in a triangular shape with 0.018-inch Australian wire. The middle helical loop is made for wedging spring action, while the other 2 helical loops are action arms inserted between the second primary molar and ectopically erupting permanent first molar. In this report, the ectopic eruption case was successfully treated with a triangular wedging spring in 2 months. This clinical report demonstrates that a triangular wedging spring can be utilized as a simple, less irritable, and more effective way of correcting ectopic eruption of the permanent first molar.. (Pediatr Dent 2005;27:143-145)

KEYWORDS: ECTOPIC ERUPTION, PERMANENT FIRST MOLAR, TOOTH ERUPTION

Received May 3, 2004 Revision Accepted November 10, 2004

Ectopic eruption of the permanent first molar is a developmental disturbance in the eruption pattern of the permanent dentition causing premature resorption of the distal root surface of the second primary molar. It can occur in the maxilla or mandible. The permanent maxillary first molar, however, is the most commonly affected tooth—with a prevalence of 2% to 6% of the general population.^{1,4}

Pulver suggested that the etiology of ectopic eruption of the maxillary first molar was a combination of a small maxilla, larger primary and permanent molars, and abnormal angulation of the eruption of the permanent first molar.² Young classified ectopic eruption of the permanent first molar into 2 forms: (1) reversible; and (2) irreversible (called “jump” and “hold”).¹

In the reversible form, the ectopically erupting permanent first molar frees itself spontaneously from a locked position and erupts into occlusion. This reversible pattern occurs in approximately 66% of ectopically erupting permanent maxillary first molars.¹ In the irreversible form, the permanent first molar remains in a locked position until active treatment is provided or premature exfoliation of a primary second molar occurs.³

In cases where the primary second molar exfoliates prematurely, a significant loss of dental arch occurs and the permanent first molar often tips mesially with some rota-

tion.³ Bjerklin and Kurol noted that, by 7 years of age, most permanent molars that will free themselves and erupt normally will have already done so.⁴

Traditionally, several techniques such as elastic separator, brass wire, or Halterman appliance have been used for correcting ectopic eruption of the permanent first molar. In this clinical report, a triangular wedging spring was utilized as a simple and more effective technique.

The triangular wedging spring is composed of 3 helical loops in a triangular shape; a 0.018-inch Australian wire is utilized (Figure 1). The middle helical loop is made for wedging spring action, while the other 2 helical loops are action arms to be inserted between the primary second molar and the ectopically erupting permanent first molar. The sizes of the 2 helical loops as action arms can be adjusted by cutting




Figure 1. Three helical springs formed in a triangular shape.

¹Dr. Kim is a third-year resident, ²Dr. Park is chairman, Department of Pediatric Dentistry, Samsung Medical Center, Sungkyunkwan University School of Medicine, Seoul, Korea. Correspond with Dr. Park at park2426@smc.samsung.co.kr

the outermost wire, according to the sizes of the interproximal spaces made for the insertion of the action arms.

Methods

The clinical technique for the triangular wedging spring includes the following steps. First, an elastic separator is placed between the primary second molar and the ectopically erupting permanent first molar to create adequate interdental space.

In about a week, enough space is created for the triangular wedging spring to be inserted (Figures 2 and 3). According to the space created, the sizes of the 2 terminal helical loops should be adjusted by cutting the outermost wire.

Next, 2 helical arms are bent at a right angle for prevention of occlusal interference, and the middle helical loop is activated for wedging spring action (Figure 4). The middle helical loop is then held with a utility plier directed toward the ectopically erupting first molar. One of the action arms is pressed into the gingival embrasure from the palatal. The triangular wedging spring is rolled across to engage the other action arm into the buccal embrasure (Figure 5).

The band pusher is used for adaptation to avoid dislocation of the triangular wedging spring. Before insertion,

topical anesthetic gel may be applied to the interdental area to relieve the patient's discomfort.

In about every 3 weeks, a newly fabricated or reactivated triangular wedging spring is inserted until enough space is created in the same manner as previously mentioned. After enough interproximal space has been created, a triangular wedging spring is removed. This interproximal space is closed spontaneously by natural mesial drifting of the permanent first molar (Figure 6).

Discussion

Several methods of treating ectopic eruption of the permanent first molar have been attempted, such as elastic separator, brass wire, Halterman type appliance, and so on.⁶⁻¹⁰ In most cases, however, separator or brass wire alone is not effective, since the amount of space that could be created is limited.^{6,7} A Halterman type appliance is effective; however, it is bulky and requires additional lab procedures.⁹

A triangular wedging spring can be easily made while chairside utilizing a 0.018-inch Australian wire. Australian wire is preferred for the triangular wedging spring because it is more resilient than stainless steel wire and provides light and continuous force.

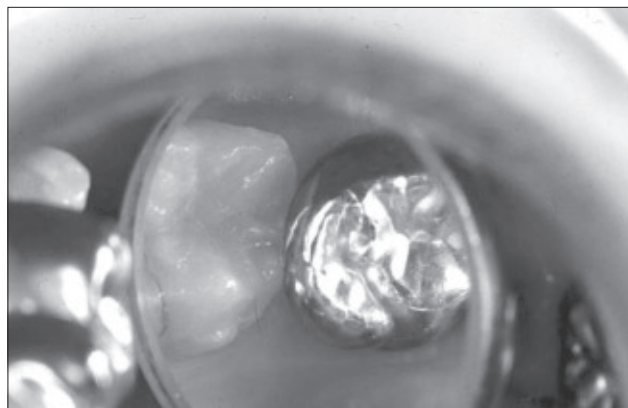


Figure 2. Upper right permanent first molar showing ectopic eruption.

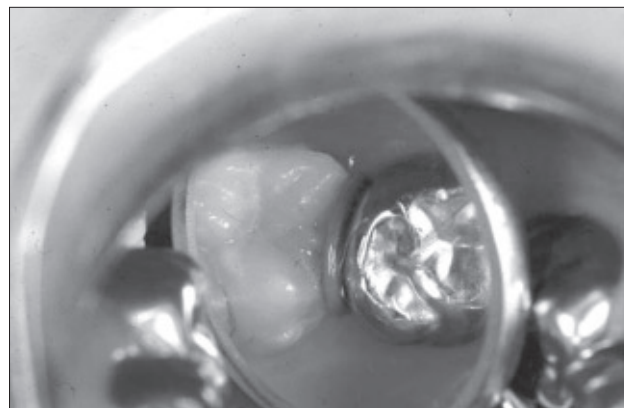


Figure 3. An elastic separator is placed between the second deciduous molar and ectopically erupting permanent first molar.



Figure 4. Bending of helical arms to prevent occlusal interference.

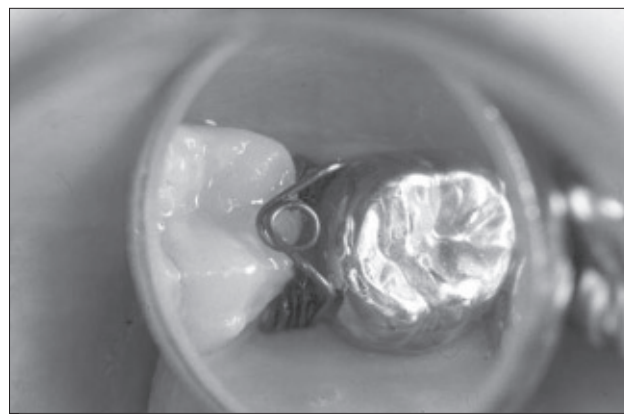


Figure 5. Triangular wedging spring is inserted.

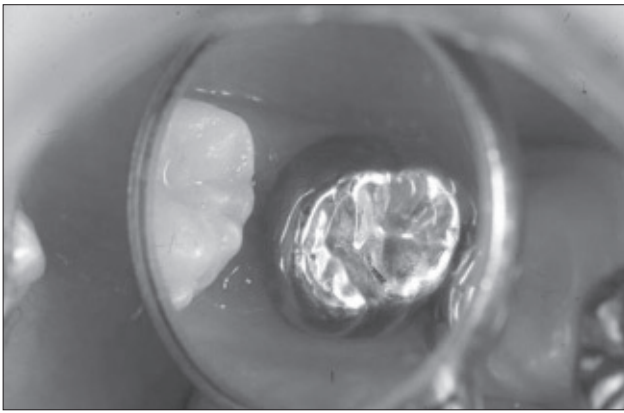


Figure 6. Enough space is created for correcting ectopic eruption of the upper right permanent first molar.

Case selection is an important factor for successful treatment with this type of spring. The primary second molar should remain stable while the interproximal wedging force is applied. Therefore, at least the mesial root of the primary second molar should be intact. Depending on the severity of the ectopic eruption and the primary second molar's stability, a distal tipping technique with a Halterman appliance should be considered.

As a clinical tip, it is recommended that dental floss be tied to the middle helical loop of the triangular wedging spring before insertion to prevent aspiration during the procedure in the mouth.

Conclusions

This clinical report demonstrates that a triangular wedging spring can be utilized as a simple, less irritating, and

more effective way of performing ectopic treatment for the permanent first molar.

References

1. Young DH. Ectopic eruption of the permanent first molar. *J Dent Child* 1957; 24:153-162.
2. Pulver F. The etiology and prevalence of ectopic eruption of the maxillary first molar. *J Dent Child* 1968; 35:138-146.
3. Gehm S, Crespi PV. Management of ectopic eruption of permanent molars. *Compendium* 1997;18:561-569.
4. Bjerklin K, Kurol J. Prevalence of ectopic eruption of the maxillary first molar. *Swed Dent J* 1981;5:29-34.
5. Bjerklin K, Kurol J. Ectopic eruption of maxillary permanent first molars: A review. *J Dent Child* 1986;53:209-214.
6. Huang WJ, Childers NK. Clinical aid in placing brass wires to treat ectopically erupting permanent first molars. *Pediatr Dent* 1995;17:122-123.
7. Kupietzky A. Correction of ectopic eruption of permanent molars utilizing the brass wire technique. *Pediatr Dent* 2000;22:408-412.
8. Humphrey WP. A simple technique for correcting an ectopically erupting permanent first molar. *J Dent Child* 1963;29:176-178.
9. Halterman CW. A simple technique for the treatment of ectopically erupting permanent first molar. *J Am Dent Assoc* 1982;105:1031-1033.
10. Venn RJ. Ectopic eruption of permanent first molars: A clinical technique. *J Pedod* 1985;10:81-88.

ABSTRACT OF THE SCIENTIFIC LITERATURE



EFFECT OF XYLITOL ON MUTANS STREPTOCOCCI AND LACTIC ACID IN ADOLESCENTS AND YOUNG ADULTS UNDERGOING ORTHODONTICS

Xylitol, a natural caloric sugar substitute, has caries-preventive potential. The purpose of this study was to investigate: (1) the effects of 2 different doses of Xylitol on mutans streptococci count in saliva and plaque; and (2) acidogenic potentials in the sample. Saliva and plaque samples were obtained from 56 patients and analyzed. The study demonstrated that a habitual intake of Xylitol-containing tablets could cause a limited but short-term decrease in mutans streptococci in the low-dose group. The mutans streptococci group, however, remained unchanged in the plaque.

Comments: A lot of confusion still exists about the exact or adequate dose needed for Xylitol to be effective. Additionally, the possibility exists that there may be certain Xylitol-resistant strains of mutans streptococcus. **KK**

Address correspondence to Dr. Christina Stecksén-Blicks, Pediatric Dentistry, Department of Odontology, Umea University, SE-901 87 Umea, Sweden.

Stecksén-Blicks, C, Holgerson, PL, Olsson, M, et al. Effect of Xylitol on mutans streptococci and lactic acid formation in saliva and plaque from adolescents and young adults with fixed orthodontic appliances. *Eur J Oral Sci* 2004;112:144-248.

35 references

Copyright of Pediatric Dentistry is the property of American Society of Dentistry for Children and its content may not be copied or emailed to multiple sites or posted to a listserv without the copyright holder's express written permission. However, users may print, download, or email articles for individual use.