



Pathophysiology, Therapy, and Oral Implications of Renal Failure in Children and Adolescents: An Update

Esti Davidovich, DMD, MSC¹ Miriam Davidovits, MD² Eliezer Eidelman, Dr. Odont, MSD³
Zvi Schwarz, DMD, PhD⁴ Enrique Bimstein, CD⁵

Abstract

The objective of this manuscript was to describe the pathophysiology and the systemic and oral implications of chronic renal failure (CRF), end-stage renal failure (ESRF), and renal replacement therapy (RRT) in children and adolescents. Improvement in treatment modalities of CRF, ESRF, and RRT have resulted in an increase in survival, and better health in children and adolescents with renal failure. Therefore, dentists are expected to encounter an increasing number of patients with renal failure needing oral care. Renal failure leads to a state of intoxication known as uremia, which is associated with extra-renal multi-organ involvement. Oral findings frequently include: (1) excessive plaque accumulation; (2) gingivitis; (3) gingival overgrowth; and (4) enamel hypoplasia. Some cases develop periodontitis. It is hoped that the present review will lead to a better understanding of the systemic and oral abnormalities in children and adolescents with renal failure and provide guidance for their treatment and, ultimately, better treatment outcome. (Pediatr Dent 2005;27:98-106)

KEYWORDS: RENAL FAILURE, ORAL IMPLICATIONS, CHILDREN

Received March 5, 2004 Revision Accepted September 10, 2004

The estimated incidence of end-stage renal failure (ESRF) in childhood, either due to a congenital or acquired condition, is 10 to 12 per 1 million children, with a prevalence varying between 39 to 56 million children.¹⁻³ Significant improvement in dialysis modalities, and especially a better outcome of renal transplantation (RTx), has resulted in more children and adolescents living longer with chronic renal failure (CRF), ESRF, or a good functioning renal graft.⁴⁻⁶

Since CRF, ESRF, and RTx are characterized by multi-organ involvement, including the soft and hard tissues of the oral cavity,^{7,8} dental professionals are expected to encounter an increasing number of children and adolescents with oral manifestations related to renal failure. For the

benefit of children and adolescents with renal failure and their dentists, this review presents a concise update of the pathophysiology, side effects of childhood renal failure treatment, and systemic and oral clinical implications. The authors base their experience on years of dental treatment of children affected with CRF or ESRF treated conservatively or with renal replacement therapy (RRT).

Chronic renal failure (CRF)

CRF is characterized by a reduction in glomerular filtration rate (GFR): adult normal is approximately 100 to 120 ml/minute/1.73 m² body surface area (BSA), either due to glomerular or renal interstitial disease. It is accompanied by clinical and laboratory changes mainly related to the kidney's inability to:

1. excrete breakdown products of body metabolism;
2. fulfill their "endocrine functions" with secretion of (among others) active vitamin D and erythropoietin (EPO).⁴⁻⁶

It is actually a state of intoxication or internal poisoning, generally known as uremia, that is also known to be a microinfectious state. It is characterized by an increase in so called acute-phase-proteins, various cytokines, and even macrophages.⁴⁻⁶ Obviously, this toxic state is associated with extra-renal, multi-organ involvement, the most important

¹Dr. Davidovich is resident and ³Dr. Eidelman is professor, Department of Pediatric Dentistry, Hadassah Faculty of Dental Medicine, Jerusalem, Israel; ²Dr. Davidovits is lecturer and head of the Nephrology Clinic and Dialysis Unit, Schneider Children's Medical Center of Israel, Petah Tikva and Sackler School of Medicine, Tel Aviv University, Israel; ⁴Dr. Schwarz is professor, Department of Periodontics, Hadassah Faculty of Dental Medicine, and professor, Department of Biomedical Engineering, Georgia Tech and Emory University, Atlanta, Ga; ⁵Dr. Bimstein is professor, Department of Pediatric Dentistry, University of Florida College of Dentistry, Gainesville, Fla. Correspond with Dr. Bimstein at ebimstein@dental.ufl.edu

of which are the: (1) skeleton (hyperparathyroidism); (2) heart and vessels; (3) lungs; (4) gastrointestinal tract; (5) central and peripheral nervous system; and (6) body's basic endocrine and reproductive function. Hypertension is also often present, at least in advanced uremia.^{4,6} The oral cavity's soft and hard tissues are not spared.^{7,8}

Pathophysiology

After an initial renal injury progression of the lesion is often observed, at a certain point there will be relentless increase in renal damage. With a fall in GFR, ESRF is, consequently, a certain end-point.^{4,5} The precise mechanisms underlying progressive renal damage are not completely clear, but include:

1. glomerular hyperfiltration (increased workload) of the remaining nephrons, which ultimately fail^{4,5};
2. systemic and intrarenal hypertension, which promotes nephrosclerosis^{4,5};
3. progression of immunologic damage, initiated by the basic renal lesion⁹;
4. proteinuria, which is not only a marker of renal disease, but in itself can cause renal tubular/interstitial damage^{9,10};
5. external, dietary, protein load, and fat load.^{11,12}

Most of the aforementioned causative mechanisms respond to antihypertensive agents such as angiotensin-converting enzyme (ACE) inhibitors or angiotensin-receptor blockers (AT1), which will provide reno-protection—irrespective of the basic renal disease.¹³ Additional therapies to reduce proteinuria are nonsteroidal anti-inflammatory drugs. A low protein and fat diet may also be advantageous.^{11,12}

The human organism will activate adaptive mechanisms to counteract the fall in GFR and the associated disturbances in homeostasis. For example, regarding the calcium-phosphate balance,^{4,5} the serum phosphorus level rises in the early stages of uremia—causing a reduction of serum calcium ions (the calculation of calcium-phosphate product is maintained within normal levels in healthy subjects). This, in turn, will cause hyperparathyroidism and, ultimately, bone lesions. Today, this vicious circle can be prevented with new vitamin D compounds combined with phosphorus-binding agents to curb uremic bone disease or renal osteodystrophy (ROD). Various similar mechanisms exist to preserve sodium, potassium, and water homeostasis. All these compensatory mechanisms fail, however, when

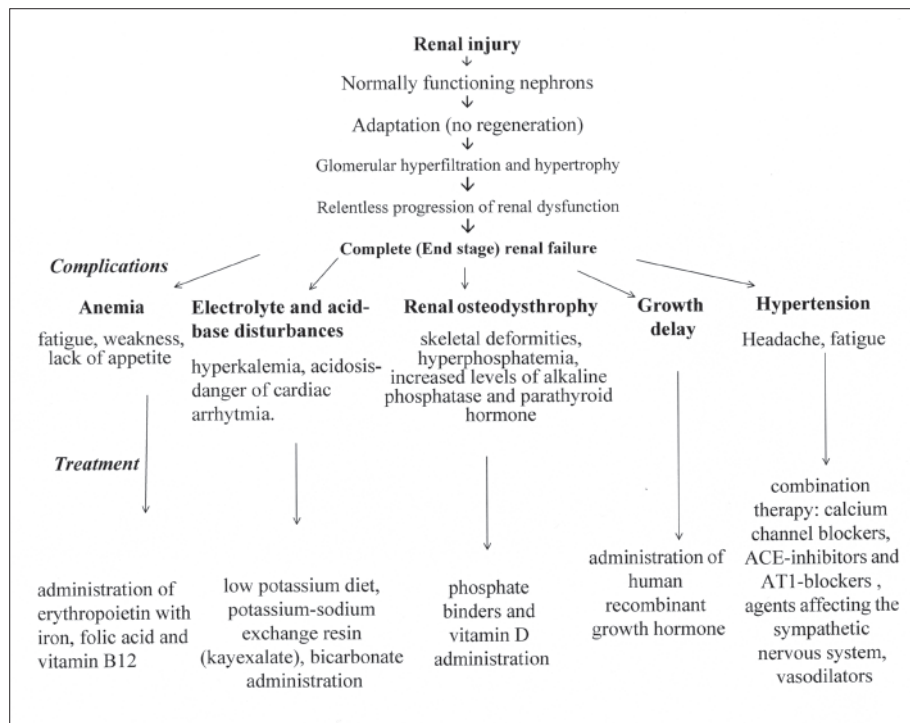


Figure 1. Sequence of events leading to ESRF—complications and treatment.

the GFR falls below 10 to 20 ml/minute/1.73 m² BSA.^{4,5} Figure 1 summarizes the sequence of events leading from a primary renal lesion to ESRF and also illustrates the major complications, dangers, and treatment.

Clinical and laboratory manifestation of CRF

The clinical signs relate to the type of renal or systemic disease and obviously depend also on the speed of the renal function decrease.^{4,6} In the early stages of CRF, the progression towards ESRF is often insidious. When ESRF eventually ensues, the patient usually complains of fatigue, weakness, lack of appetite, nausea, vomiting, diarrhea, headache, and sometimes neurological disturbances. Physical examination usually reveals pallor due to severe anemia, peripheral edema, elevated blood pressure, skeletal deformities, and delayed growth and development (puberty) in children who are not treated early enough.^{4,6}

Severe hyperkalemia is seen in rapid acute renal failure and in the late stages of ESRF, and is extremely dangerous because of its cardiac action, which leads to heart block. The ambulatory treatment of hyperkalemia consists of a low-potassium diet, (slow) correction of acidosis with oral sodium bicarbonate, and the administration of a potassium-sodium or potassium-calcium exchange resin such as Kayexalate (Sanofi Synthelabo Inc, New York, NY).^{4,5} The anemia of CRF/ESRF is due to decreased EPO production, shortened life span of red blood cells, blood loss (especially with patients on hemodialysis), and inadequate intake of iron and folic acid.^{4,5} The treatment of choice is subcutaneous or intravenous (IV) administration of EPO together

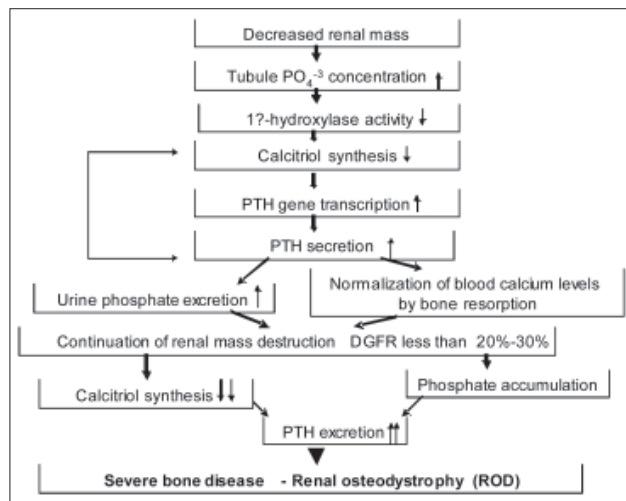


Figure 2. Renal osteodystrophy mechanism.

with oral or IV iron, folic acid, and vitamin B12 needed for rapid formation of new blood cells,¹⁴ with the target hemoglobin level being 11 grams to 12 grams.¹⁴ This obviates repeated blood transfusions, which have many side effects.

The etiology of the skeletal abnormalities of ROD has already been alluded to and can present with delayed growth, skeletal deformities, bone pain, muscle weakness, and disturbances in teeth formation.^{8,15} Laboratory findings are characterized by hyperphosphatemia, hypocalcemia, increased serum levels of alkaline phosphatase, and high parathyroid hormone (PTH) levels. The radiographic findings differ according to the severity of the bone lesions. In childhood, rickets-like findings can be seen.¹⁶ ROD can be prevented by early treatment with oral or IV (hemodialysis) vitamin D preparation and oral phosphate binders with regular and frequent monitoring of the blood abnormalities and the radiographic findings.⁴⁻⁶

Figure 2 presents an insight into the role of vitamin D and its metabolism in ROD. Two invasive but very useful tools are repeated bone biopsies and close follow-up of bone formation markers. ROD treatment should not be too rigorous, since adynamic bone disease may occur, which does not respond to any treatment. Appropriate ROD therapy in children is associated with better growth.⁴⁻⁶

Growth retardation is a hallmark of CRF in children.¹⁷ The most severe growth delay is found in children with early-onset CRF. Many factors contribute to growth retardation, such as reduced food intake and chronic metabolic acidosis. Correction of these factors, however, rarely causes normal growth. Recent studies have shown that the main factor causing growth retardation in CRF children is impairment of the biological activity of insulin-like growth factor (IGF-1), the mediator of growth hormone (GH) action.¹⁷ GH blood levels are generally normal. High-dose administration of exogenous human recombinant GH (hGH) in children with CRF/ESRF, on RRT, and even after RTx, however, causes significant growth velocity ac-

celeration. With early HGH treatment, height can be attained that is normal for age, gender, and race (and height of parents).^{14,17}

The causes for hypertension in CRF are manifold, but of primary importance is a state of volume overload due to sodium and water retention.^{4,6} Blood pressure control is generally achieved by combination therapy, mainly with vasodilators, calcium channel blockers, ACE-inhibitors and AT1-blockers.^{18,19} The main cause of death of patients with CRF/ESRF is cardiovascular events, particularly in adult patients with concomitant diabetes that is not well controlled.^{20,21}

Treatment of ESRF

When conservative measures fail to halt renal damage progression, renal replacement therapy (RRT) may have to be instituted. That point is generally reached when:

1. GFR falls <10 ml/minute/1.73 m² BSA and blood urea nitrogen levels rise to 100 to 150 mg% (normal=10 to 20 mg%); or
2. the clinical status of the child requires a more active course of treatment.⁶

Consequently, the choice of the patient and the treating physician is between:

1. dialysis—either hemodialysis (HD) or peritoneal dialysis (PD)²²; or
2. RTx, which is the preferred method because of ultimately better rehabilitation.

Today, the best solution is probably a so-called pre-emptive transplant, meaning a RTx without prior dialysis therapy. This is generally with an appropriate live kidney donation, unless the patient can be placed on the national waiting list for a cadaver-donor RTx.²³ Unfortunately, the waiting list for a cadaver-donor RTx gets constantly longer without a concomitant rise in the availability of kidneys for RTx. This is a worldwide phenomenon. Generally, children have priority for RTx.

All aspects of RRT in children belong to the realm of the pediatric nephrologists, and only the basics of these treatments are here discussed.^{5,6,22-24} In HD, the blood of the patients is cleansed approximately 3 times per week in a hospital setting by feeding unclotted blood through an extracorporeal artificial kidney.²⁴ The major problems with HD are the:

1. short lifetime of surgically created arteriovenous fistulae that can be punctured to obtain appropriate blood flow rates;
2. intermittent aspect of the dialysis procedure needing strict dietary observance between treatments;
3. decreased blood clotting for several hours after a HD;
4. need for constant hospital visits.²⁴

PD obviates many of these problems and is certainly the preferred dialysis treatment in children.^{22, 24}

In PD, an elastic catheter is surgically placed into the peritoneal cavity for long-term use with intermittent (4 to 6 times daily) infusion and drainage (by gravity) of a sterile electrolyte solution (in a plastic bag) that will clean the

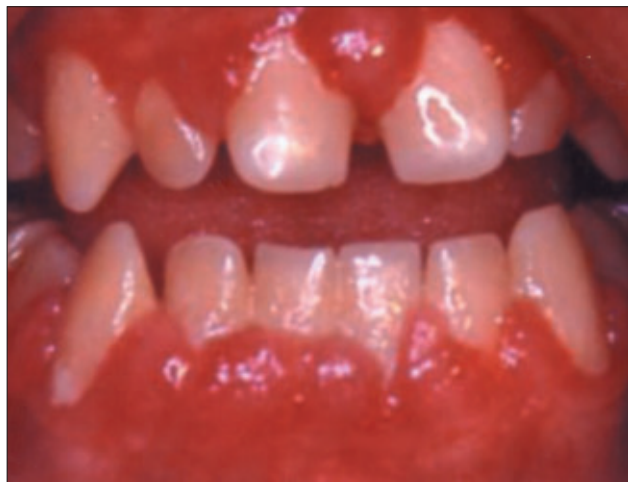

Figure 3. Gingival overgrowth and gingival inflammation in a 16-year-old boy transplanted.

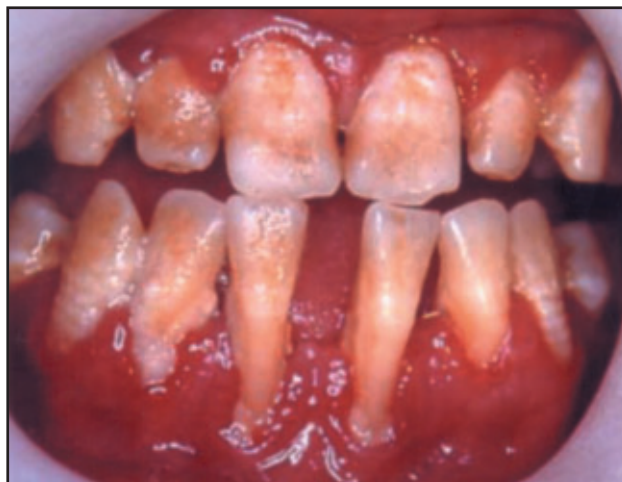

Figure 4. Extensive plaque and calculus accumulation, gingival inflammation, recession, and enamel hypoplasia in a 16-year-old boy undergoing dialysis.

blood by osmosis during the “dwell time” in the belly.²² This can be done by the patient or relatives at home (continuous ambulatory PD) or by a machine at night (continuous cyclic PD). The advantages of PD over HD include^{22,24}:

1. fewer dietary restrictions;
2. better growth;
3. less bone disease and anemia;
4. most important, a relatively normal life with few hospital visits.

The drawbacks of PD are:

1. catheter-associated obstruction;
2. infections with peritonitis requiring repeated aggressive antibiotic treatments.

It should be emphasized that all dialysis modalities will maximally provide approximately 20% of normal 2-kidney renal function, meaning that the dialysis patient remains in severe CRF, although without immediate danger for his/her life. Therefore, RTx is the preferred RRT, certainly in growing children.

Renal transplantation

The first renal transplantation (RTx) between humans (a mother and adult son with an injured single kidney) was performed on Christmas 1952 in Paris. A graft rejection occurred after 10 days, resulting in the patient's death. The first successful long-term RTx was performed 7 years later in Boston between identical twins.²⁵ The surgical procedure in both cases was the same, but the immunologic background was obviously different. The operation in Boston was successful because of the 100% immunological compatibility between the twins.

Since then, there is a far better understanding of the factors underlying graft rejection and better drug treatment to prevent and treat the immune processes responsible for rejection. Therefore, the halftime survival of a renal graft between nonconsanguineous donors and recipients has now reached approximately 20 years.

In general, the RTx results in children (with young adult donors) are even better than in adults. The compatibility of the antigens associated with blood type (ABO system), and human leucocytes antigens (HLA) is the most important factor involved in a successful transplant.²⁶ Before every RTx, the blood or tissues of the donor and the recipient are matched to at least prevent hyperacute rejection due to preformed antibodies between the donor and patient. Immediately before the RTx, and thereafter as long as the graft is functioning, the recipient needs immunosuppressive treatment. This generally consists of a triple therapy, a combination of:

1. corticosteroids;
2. calcineurin inhibitors like cyclosporine (Sandoz, Vienna, Austria) or tacrolimus (Fujisawa, Osaka Japan);
3. lymphocyte-proliferation inhibitors such as azathioprim (generics, Middlesex England) or mycophenolate mofetil (MMF; commercial name: Cellcept; Roche Pharmaceutical, Basel Switzerland), each having different immunologic actions.

The use of the relatively new drugs such as tacrolimus, previously called FK506, and MMF are now preferred because of far more aggressive immunosuppression and more desirable side effects, including less corticosteroid toxicity and gingival overgrowth.²⁷

Renal graft survival after cadaver-donor kidney grafting nowadays reaches 83% after 1 year and 65% after 5 years.²⁶ RTx survival in living donor RTx is approximately 10% to 15% better. The advantages of a RTx are clear, especially with good renal graft function, and include:

1. improved health and quality of life;
2. no diet except for prevention of obesity;
3. better growth;
4. healing of bone disease and other systemic manifestations of CRF, including anemia.²⁶

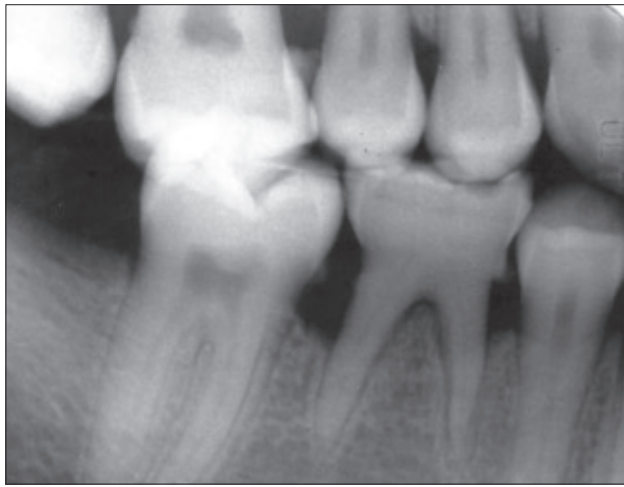


Figure 5. Obliteration of primary mandibular right second molar and alveolar bone loss in a 21-year-old transplanted patient.

Nevertheless, there are also complications of RTx, including:

1. hypertension;
2. opportunistic infections due to aggressive and prolonged immunosuppression;
3. recurrence of the basic disease in a minority of renal diseases;
4. the appearance of a new kidney disease entity called transplant nephropathy.²⁶

When a renal transplant is lost, the patient can be treated with dialysis therapy followed by another RTx. This obviously means that patient survival in RRT is far better than graft survival.²⁶

Oral manifestations and treatment

The major oral disturbances related to CRF or its treatment involve both the soft and hard tissues and include:

1. pallor of the oral mucosa, uremic stomatitis, gingival bleeding, petechiae and echymoses;
2. gingival inflammation;
3. gingival overgrowth;
4. periodontal disease;
5. enamel hypoplasia;
6. pulp obliteration;
7. osseous changes of the jaws;
8. reduced prevalence of dental caries;
9. other disturbances.

The soft tissue pallor has been largely eliminated by preventing anemia with EPO, but uremia may lead to bleeding, petechiae, and echymoses, which may be exacerbated in patients receiving anticoagulants for dialysis purposes.^{8,28}

Gingival inflammation

Gingival inflammation has been reported, due to plaque accumulation and poor oral hygiene habits^{8,28,29} (Figures 3 and 4). Oral hygiene has the potential to reduce the inflammatory component of gingival disease in patients with renal failure.³⁰

Gingival overgrowth

Gingival overgrowth (GO; Figure 3) is believed to be related to:

- a. an alteration of the fibroblast metabolism by cyclosporine and/or its metabolites;
- b. increasing protein synthesis;
- c. collagen;
- d. extra-cellular matrix formation.^{27,30}

The relevance of GO treatment is emphasized by:

- a. its unpleasant appearance, with a subsequent adverse psychological impact;
- b. the interference with the normal oral function;
- c. delayed and/or ectopic eruption;
- d. impaired speech;
- e. gingival sensitivity;
- f. difficulty to maintain oral hygiene.^{8,30}

The prevalence of GO in patients with organ transplantations is extremely variable, since it depends on:

- a. age (children have a higher prevalence than adults);
- b. gender (males have a higher prevalence);
- c. medical condition's underlying severity;
- d. degree of immunosuppression;
- e. pharmacokinetic properties (pharmaceutical preparation, dosage, relation between various medicaments);
- f. presence of gingival inflammation before the transplantation;
- g. individual susceptibility to the medicaments and/or their metabolites;
- h. genetic predisposition.^{7,27,30-39}

Furthermore, it has been indicated that there is a threshold dose for the appearance of GO related to cyclosporine.^{30,36,37}

Several manuscripts indicate that replacement of cyclosporine therapy with tacrolimus therapy may reduce the severity of GO, with minimal risk of graft dysfunction.^{27,34,38} This change is diminished, however, when the patient continues to receive calcium channel blockers.²⁷ In any case, the need for concomitant meticulous oral hygiene is essential to reduce GO's inflammatory component.^{30,38} In fact, a GO reduction in cases with continuous cyclosporine therapy has been related to an improvement in oral hygiene.³⁶

It has been reported that children with GO may have increased plaque accumulation when compared to control patients, and that plaque accumulation and gingival inflammation correlate.³⁹ One must consider, however, that the possibility of exacerbation of gingival growth by bad oral hygiene and the subsequent gingival inflammation may vary according to individual susceptibility to plaque pathogens.³⁹

GO treatment may be conservative with meticulous professional and personal oral hygiene⁴⁰ and/or surgically by laser⁴¹ or traditional scalpel surgery. In general, recurrence is considered inevitable. A delay in surgery for at least 3 years, however, may be beneficial in reducing the recurrence rate.³⁰ Laser surgery's potential advantages include: (1) decreased bleeding and postoperative trauma; (2) no need for sutures;

(3) faster healing; (4) reduced infection risk; and (5) shorter procedure and recovery times.⁴¹

An additional possibility for GO treatment is the use of antibiotics such as azithromycin, metronidazole, and clarithromycin. The mechanism of action has been attributed to:

1. their antibacterial action;
2. reduction in local inflammation;
3. possible suppression of protein synthesis in the fibroblasts before severe GO is established.³⁰

In any case, it is clear that the early establishment of an oral hygiene program for children and adolescents receiving medication such as cyclosporine or calcium channel blockers has the potential to reduce the deleterious effect of these medicaments on the gingiva.

Periodontal disease

Conflicting factors are involved in the manifestation of periodontal diseases (Figure 4) in children with renal failure or after organ renal transplantation. On the one hand, they frequently have:

1. high plaque accumulation;
2. disturbed calcium and phosphate that may cause alveolar bone changes (such as loss of lamina dura)²⁸;
3. secondary hyperparathyroidism;
4. polymorphonuclear-impaired function, and immunosuppressive therapy, which may increase the susceptibility to infections.⁶

On the other hand, the immunosuppression reduces the immune response to periodontal pathogens.⁴² In fact, manuscripts indicate inconsistent findings:

1. Thirty-six percent of patients receiving hemodialysis may have early periodontitis.⁴³
2. There is no difference in periodontal severity between chronic renal transplants and those receiving hemodialysis.⁴⁴
3. Hemodialysis and secondary hyperparathyroidism do not have an appreciable effect on the patient's periodontium.⁴⁵

In any case, if periodontal diseases in renal failure patients and Polymorphonuclear Leukocytes (PMN) impairment are diagnosed early, they may be successfully treated with aggressive periodontal treatment, emphasizing plaque control.⁴² It appears, therefore, that cases of severe periodontitis in patients with renal diseases (such as the one presented in Figure 3), develop only in cases with increased individual susceptibility and lack of adequate early treatment.

Enamel hypoplasia

Disturbed calcium and phosphate metabolism may cause developmental enamel disturbances, including enamel hypoplasia (Figure 4). The age in which the metabolic disturbances take place correlate with the dental developmental disturbances, as reflected by prominent incremental lines.^{8,46-48} The treatment of these defects should be based

on the defect's severity and extent and the patient's dental developmental stage (state of eruption of the affected teeth) and may vary from bonded composite conservative restorations to full-crown coverage.

Pulp obliteration

Pulp obliteration (Figure 5) is most likely related to disturbed calcium and phosphate metabolism.^{49,50} Routine follow-up is required to diagnose at an early stage any complication related to the obliteration.

Osseous changes of the jaws

Classically, the triad of loss of lamina dura, demineralized bone ("ground-glass"), and localized radiolucent jaw lesions is apparent in these patients.²⁸ In addition, bony fractures and bone tumors from secondary hyperparathyroidism may take place.^{4,5}

Reduced prevalence of dental caries

Low caries rates are related to increased pH, resulting from urea hydrolyzation in the saliva, which neutralizes the metabolic end products of bacteria.^{8,51-53}

Other disturbances

The metabolic changes related to renal dysfunction or its treatment have been also related to eruption of rootless teeth⁵⁴ and cysts.⁵⁵ An important finding is that gingival overgrowth may be the site for the development of oral carcinoma.⁸ Cytomegalovirus infection may occur most commonly in the first few months after transplantation, coinciding with the maximal immunosuppression. Its presence has the potential to increase the severity of gingival inflammation and overgrowth.³⁶ Furthermore, it has been reported that the majority of the micro-organisms shown to cause fatal complications in these patients may be found in the oral cavity.⁹ Interestingly, enamel hypoplasia in patients with infancy-onset end-stage renal disease (ESRD) have been also related to delayed or altered eruption.⁴⁶⁻⁴⁸

Oral treatment in ESRF

Consultation with the physician about the appropriate timing and possible medical complications is mandatory. Furthermore, there should be an evaluation of coagulation parameters before the beginning of procedures that may cause possible bleeding.^{28,56,57} The dosage of administered drugs should be adjusted to the kidney's reduced ability for metabolism and secretion. For example, the dose of midazolam widely used for sedation must be reduced to 50% in patients with GFR less than 10 ml/minute/1.73 m².⁵⁸

In any case of renal deficiency, practitioners must take into consideration the metabolism of any administered drugs and the patient's condition. The decision to perform treatment with or without sedation is, as with the general population, based on several factors such as behavior management and amount and type of treatment required.

The alterations in every drug dosage, according to renal function, are published in the *Drug Prescribing in Renal Failure, Dosing Guidelines for Adults*.⁵⁸

Orofacial infections should be treated aggressively, keeping in mind the required antibiotic dosage adjustment. Patients with significant hypertension treated with a combination of antihypertensive drugs should be closely monitored during dental treatment for early detection of alterations in blood pressure caused by administration of adrenaline in local anesthetics and stress from dental treatment. Most significant is to keep in mind that, because of increased bleeding tendency due to uremic state, preparation of local coagulation medications (topical thrombin, microfibrillar is mandatory).²⁸

Oral treatment for patients undergoing hemodialysis

Procedures involving bleeding or requiring antibiotic administration should not be performed on the dialysis session day; other dental treatment can be performed at any time.⁹ In addition to conservative care recommendations, as for ESRF, the concern should be for blood access (atrial-ventricular fistula or central line), due to increased risk for infective endocarditis.⁸ Blood pressure cuff and IV medications should not be administered in the shunt's arm.²⁸ Circulating heparin may also put patients at risk of prolonged bleeding.⁸

Dental preparation before kidney transplantation

All present or potential infection foci should be eliminated to allow for reaching the stage of immunosuppression without any oral infections. Obviously, oral hygiene maintenance is very important to prevent infectious oral diseases.

Oral treatment in transplanted patients

The first step in treating a transplanted child is consultation with the pediatric nephrologist about the graft function and degree of immunosuppression. Administration of different drugs (eg, sedation, antibiotics, etc.) should take into account the degree of renal function.

If the prednisone regimen is an alternate day schedule, stressful dental procedures should include administration of steroids in the stress dose. The dentist should introduce a recall program every 3 to 6 months for maintaining effective oral hygiene procedures.²⁸ In patients receiving cyclosporine, the change to tacrolimus should be discussed with the nephrologist.

Conclusions

CRF patients present a complex clinical problem with multi-system involvement, including several oral disturbances. Pediatric and general dentists should be aware of the severity of clinical manifestations related to CRF as well as the modern treatment possibilities and their repercussions on the lives of these children. Since the number of CRF children is constantly increasing, the need for dental treatment as an integral part in managing the CRF child is also rising. It is important for dentists to be familiar with

this complex clinical problem, and its effect on the dental treatment, for provision of optimal dental care.

References

1. Trivedi HS, Pang MM. Discrepancy in the epidemiology of nondiabetic chronic renal insufficiency and end-stage renal disease in black and white Americans: The third National Health and Nutrition Examination Survey and United States Renal Data System. *Am J Nephrol* 2003;23:448-457.
2. Esbjorner E, Berg U, Hansson S. Epidemiology of chronic renal failure in children: A report from Sweden 1986-1994. *Pediatr Nephrol* 1997;11:438-442.
3. Report of a working party of the British Association of Pediatric Nephrology. *The Provision of Services in the United Kingdom for Children and Adolescents with Renal Disease*. London: British Pediatric Association; 1995.
4. Fogo A, Kon W. Pathophysiology of progressive chronic renal disease. In: Avner ED, Harmon WE, Niaudet P, eds. *Textbook of Pediatric Nephrology*. 5th ed. Philadelphia, Pa: Lippincott, Williams & Wilkins; 2004:1267-1480.
5. Davidovits M, Sinai-Treiman L. Diseases of kidney and urinary tract. In: Shohat M, Ashkenazi S, eds. *Textbook of Pediatrics*. 5th ed. Tel Aviv, Israel: Dyonon; 1998:433-474.
6. Riegden S. The management of chronic and end-stage renal failure. In: Webb N, Postlethwaite R, eds. *Textbook of Clinical Pediatric Nephrology*. 3rd ed. Oxford Great Britain: Oxford Medical Publications; 2003:427-445.
7. Wolff A, Stark H, Sarnat H, Binderman I, Eisenstein B, Drukker A. The dental status of children with chronic renal failure. *Int J Pediatr Nephrol* 1985;6:127-132.
8. Nunn JH, Sharp J, Lambert HJ. Oral health in children with renal disease. *Pediatr Nephrol* 2000;14:997-1001.
9. Hostetter TH, Olson JL, Rennke HG, Venkatachalam MA, Brenner BM. Hyperfiltration in remnant nephrons: A potentially adverse response to renal ablation. *Am J Physiol* 1981;241:F85-F93.
10. Aros C, Remuzzi G. The renin-angiotensin system in progression, remission, and regression of chronic nephropathies. *J Hypertens* 2002;20(suppl 3):S45-53.
11. Klahr S, Levey AS, Begg GJ, et al. The effects of dietary protein restriction and blood-pressure control on the progression of chronic renal disease. *N Eng J Med* 1994;330:877-884.
12. Keane WI. Lipids and the kidney. *Kidney Int* 1994;46:910-920.
13. Kakinuma Y, Kawamura T, Bills T, Yoshioka T, Ichikawa I, Fogo A. Blood pressure-independent effect of angiotensin inhibition on vascular lesions of chronic renal failure. *Kidney Int* 1992;42:46-55.

14. Warady BA, Jabs K. New hormones in the therapeutic arsenal of chronic renal failure. Growth hormone and erythropoietin. *Pediatr Clin North Am* 1995;42:1551-1578.
15. Salusky I. Bone and mineral metabolism in childhood end-stage renal failure. *Pediatr Clin North Am* 1995;42:1531-1550.
16. Pereira CM, de Andrade CR, Vargas PA, Colleta RD, de Almeida OP, Lopes MA. Dental alterations associated with X-linked hypophosphatemic rickets. *J Endod* 2004;30:241-245.
17. Fine RN. Growth hormone treatment of children with chronic renal insufficiency, end-stage renal disease and following renal transplantation-update 1997. *J Pediatr Endocrinol Metab* 1997;10:361-370.
18. Sinaiko AR. Hypertension in children. *N Engl J Med* 1996;335:1968-1973.
19. Palmer BF. Managing hyperkalemia caused by inhibitors of the renin-angiotensin-aldosterone system. *N Engl J Med* 2004;351:585-592.
20. Paparello J, Kshirsagar A, Batlle D. Comorbidity and cardiovascular risk factors in patients with chronic kidney disease. *Semin Nephrol* 2002;22:494-506.
21. McDonald SP, Craig JC. Long-term survival of children with end-stage renal disease. *N Engl J Med* 2004;350:2654-2662.
22. Flynn JT, Warady BA. Peritoneal dialysis in children: Challenges for the new millennium. *Adv Ren Replace Ther* 2000;7:347-354.
23. Benfield MR. Current status of kidney transplant: Update 2003. *Pediatr Clin North Am* 2003;50:1301-1334.
24. Goldstein SL. Hemodialysis in the pediatric patient: State of the art. *Adv Ren Replace Ther* 2001;8:173-179.
25. Richet G. Hamburger's achievement with early renal transplants. *Am J Nephrol* 1997;17:315-317.
26. Seikaly M, Ho PL, Emmet L, Tejani A. The 12th annual report of the North American pediatric renal transplant cooperative study: Renal transplantation from 1987 through 1998. *Pediatr Transplant* 2001;5:215-231.
27. Ellis JS, Seymour RA, Taylor JJ, Thomason JM. Prevalence of gingival overgrowth in transplant patients immunosuppressed with tacrolimus. *J Clin Periodontol* 2004;31:126-131.
28. Little J, Falace D, Miller C, Rhodus N. Chronic renal failure and dialysis. In: Little J, Falace D, Miller C, Rhodus N, eds. *Dental Management of the Medically Compromised Patient*. 6th ed. St. Louis, Mo: Mosby Co; 2002:147-160.
29. Tollefsen T, Johansen R. Periodontal status in patients before and after renal allotransplantation. *J Periodont Res* 1985;20:227-236.
30. Chabria D, Weintraub RG, Kilpatrick NM. Mechanisms and management of gingival overgrowth in paediatric transplant recipients: A review. *Int J Paediatr Dent* 2003;13:220-229.
31. Karpinia K, Matt M, Fennel R, Hefti A. Factors affecting cyclosporine-induced gingival overgrowth in pediatric renal transplant recipient. *Pediatr Dent* 1996;18:450-455.
32. Wilson R, Morel A, Smith D, et al. Contribution of individual drugs to gingival overgrowth in adult and juvenile renal transplant patients treated with multiple therapy. *J Clin Periodontol* 1998;25:457-464.
33. Thomason J, Seymour R, Rice N. The prevalence and severity of cyclosporin and nifedipine-induced gingival overgrowth. *J Clin Periodontol* 1993;20:37-40.
34. Radwan-Oczo M, Boratynska M, Klinger M, Ziletec M. Risk factors of gingival overgrowth in kidney transplant recipients treated with cyclosporine A. *Ann Transplant* 2003;8:57-62.
35. Bartoli F, Castrovo G, Stabile A. Risk factors conditioning the incidence and severity of cyclosporine A-induced gingival overgrowth and methods of prevention. *Minerva Stomatol* 2004;53:165-170.
36. Hosey M-T, Davison SM, Gordon G, Shaw L, Kelly DA. Cytomegalovirus and cyclosporin-induced gingival overgrowth in children with liver grafts. *Int J Pediatr Dent* 2002;12:236-243.
37. Boratynska M, Radwan-Oczko M, Falkiewicz K, Klinger M, Szyber P. Gingival overgrowth in kidney transplant recipients treated with cyclosporine and its relationship with chronic graft nephropathy. *Transplant Proc* 2003;35:2238-2240.
38. Hernandez G, Arriba L, Fraix MC, de la Machorra JC, et al. Conversion from cyclosporin A to tacrolimus as a non-surgical alternative to reduce gingival enlargement: A preliminary case series. *J Periodontol* 2003;74:1816-1823.
39. Alfonso M, Bello V de O, Civil JA, Spoto MR. Cyclosporin A-induced gingival overgrowth in renal transplant patients. *J Periodontol* 2003;74:51-56.
40. Irshied E, Bimstein E. Oral diagnosis of Behcet disease in an 11-year old girl and the nonsurgical treatment of her gingival overgrowth caused by cyclosporine. *J Clin Pediatr Dent* 2001;26:93-98.
41. Guelmann M, Britto LR, Katz J. Cyclosporin-induced gingival overgrowth in a child treated with CO2 laser surgery: A case report. *J Clin Pediatr Dent* 2003;27:123-126.
42. Khocht A. Periodontitis associated with chronic renal failure: a case report. *J Periodontol* 1996;67:1206-1209.
43. Naugle K, Darby ML, Bauman DB, Lineberger LY, Powers R. The oral health status of individuals on renal dialysis. *Ann Periodontol* 1998;3:197-205.
44. Rahman MM, Caglayan F, Rahman B. Periodontal health parameters in patients with chronic renal failure and renal transplants receiving immunosuppressive therapy. *J Nihon Univ Sch Dent* 1992;34:265-272.
45. Frankenthal S, Nakhoul F, Machtei EE, et al. The effect of secondary hyperparathyroidism and hemodialysis therapy on alveolar bone and periodontium. *J Clin Periodontol* 2002;29:479-483.

46. Woodhead J, Nowak A, Crall J, Robillard J. Dental abnormalities in children with chronic renal failure. *Pediatr Dent* 1998;24:281-285.
47. Seow W. Enamel hypoplasia in the primary dentition: A review. *J Dent Child* 1991;58:441-452.
48. Koch M, Buhner R, Pioch T, Scharer K. Enamel hypoplasia of primary teeth in chronic renal failure. *Pediatr Nephrol* 1999;13:68-72.
49. Nassotrom K, Forsberg B, Petersson A, Westesson G. Narrowing of the dental pulp chamber in patients with renal diseases. *Oral Surg* 1985;59:242-246.
50. Galili D, Berger E, Kaufman E. Pulp narrowing in renal end-stage and transplanted patients. *J Endod* 1991;17:442-443.
51. Obry F, Belcourt Frank R. Biochemical study of whole saliva from children with chronic renal failure. *J Dent Child* 1987;54:429-432.
52. Gavalada C, Bagan J, Scully C, Silvestre F, Milian M, Jimenez Y. Renal hemodialysis patients: Oral, salivary, dental, and periodontal findings in 105 adult cases. *Oral Dis* 1999;5:299-302.
53. Stoppelaar J. Urea and ammonia in saliva of caries inactive children with renal disease. *J Dent Res* 1982;61:3-225.
54. Brin I, Zilberman Y, Galili D, Fuks A. Eruption of rootless teeth in congenital renal disease. *Oral Surg Oral Med Oral Pathol* 1985;1:61-64.
55. Kuczek A, Beilker T, Herbst H, Flemming TF. Eruption cyst formation associated with cyclosporin A. *J Clin Periodontol* 2003;30:462-466.
56. Ertugrul F, Elbek-Cubukcu C, Sabah E, Mir S. The oral health status of children undergoing hemodialysis treatment. *Turk J Pediatr* 2003;45:108-113.
57. Chow M, Peterson D. Dental management of children with chronic renal failure undergoing hemodialysis therapy. *Oral Surg* 1979;48:18-34.
58. Bennet WM, Aronoff GR, Gloper TA, Brater C, Singer I. In: Bennet WM, Aronoff GR, Gloper TA, Brater C, Singer I, eds. *Drug Prescribing in Renal Failure, Dosing Guidelines for Adults*. 3th ed. Majors Co. Dallas Tex: American Journal of Physicians; 1994:19-99.

ABSTRACT OF THE SCIENTIFIC LITERATURE



EFFECT ON DENTIN BOND STRENGTH BY VARYING ETCH TIME USING ONE-STEP BONDING SYSTEMS

It has been suggested that a "weak zone" could exist between intact dentin and the hybrid layer of a composite resin as well as within the hybrid layer itself. Acid etching of dentin demineralizes dentin to different depths, depending on acid type, concentration, and etch time. The purpose of this study was to evaluate whether reducing the etch time to 5 seconds from the recommended 15 seconds or increasing up to 30 seconds has any effect on dentin bonding.

In this study, 3 one-step bonding agents (Single Bond, One Step, and Syntac) were tested on 108 extracted human molar teeth. Three evenly divided groups were assigned each bonding agent, and then each group was subdivided into 3 subgroups based on etching time (5, 15, or 30 seconds.) All groups were bonded with Z-100 composite resin, as per the manufacturer's instructions. After thermocycling, all specimens were tested in the shear mode until failure. Significant differences only exist for the different etch times with the Syntac bonding agent, and not the others tested. In all cases, however, etch times of less than 15 seconds do not seem to adversely affect bonding to dentin.

Comments: The dentin-to-composite bond interface is a very complex structure, and this study was narrow in scope by not taking into account other factors which could affect the fracture site. Etch time is one variable under the clinician's direct control. In a pediatric setting, dentists do not always enjoy the advantage of an "ideal clinical condition." Hence, the results published here can give some consolation if dentists are not able to maintain prescribed etch times. **GM**

Address correspondence to Dr. Amer Abu-Hanna, University of Florida, College of Dentistry, Department of Operative Dentistry, Health Sciences Center, PO Box 100415, Gainesville, Fla.

Abu-Hanna A, Gordan VV. Evaluation of etching time on dentin bond strength using single bottle bonding systems. *J Adhes Dent* 2004;2:105-110.

36 references

Copyright of Pediatric Dentistry is the property of American Society of Dentistry for Children and its content may not be copied or emailed to multiple sites or posted to a listserv without the copyright holder's express written permission. However, users may print, download, or email articles for individual use.