



Dentigerous Cysts in Primary Dentition: Report of 2 Cases

Alberto Carlos Botazzo Delbem¹ Robson Frederico Cunha¹ Rebeca Lima Afonso² Karina Gerhardt Bianco² Ana Paula Idem³

Abstract

Dentigerous cysts are benign odontogenic cysts associated with the crowns of permanent teeth. They are usually single in occurrence and located in the mandible. The purpose of this case report was to describe the management of 2 dentigerous cysts in children. The treatments instituted were the extraction of the deciduous tooth involved followed by marsupialization in the first case and enucleation in the second one. Both treatments allowed rapid healing of the lesion and eruption of the permanent teeth without the need for orthodontic treatment. (*Pediatr Dent* 2006;28:269-272)

KEYWORDS: DECIDUOUS DENTITION, DENTIGEROUS CYST, ODONTOGENIC CYSTS, ORAL SURGERY

Received April 13, 2005 Revisions Accepted January 10, 2006

Dentigerous cysts are the second most common type of odontogenic cysts, accounting for 49% of all cystic lesions.¹ They are generally associated with the crowns of impacted or unerupted permanent teeth. Dentigerous cysts are more common in male patients and frequently occur during the second and third decade of life.

Patients with dentigerous cysts have no painful symptoms unless there is acute inflammatory exacerbation, thus explaining the fact that these lesions are often detected only during routine radiographic examination.²

If the cyst reaches a large size (>2 cm in diameter),³ swelling, mild sensitivity, tooth mobility, and displacement may be observed. The radiographic pattern is characterized by a symmetric, well-defined, unilocular radiolucent lesion surrounding the crown of an unerupted tooth.⁴

Histologically, dentigerous cysts consist of a fibrous wall containing variable amounts of myxoid tissue and odontogenic remnants. The cyst is lined with nonkeratinized stratified squamous epithelium consisting of mucosebaceous, ciliated and, rarely, sebaceous cells. The epithelial-connective tissue interface is typically flattened, but becomes highly irregular when associated with inflammation.⁵

Possible complications resulting from dentigerous cysts include:

1. permanent bone deformation or pathologic bone fracture;
2. expansive bone destruction;
3. loss of permanent teeth; and
4. development of squamous cell carcinoma, mucoepidermoid carcinoma, and ameloblastoma.⁶

Among the treatments proposed for dentigerous cysts, 2 techniques can be emphasized:

1. total enucleation for small lesions and marsupialization for decompression of large volume cysts; or
2. a combination of both.⁷⁻⁹

The purpose of this case report was to present the management of 2 dentigerous cysts in children.

Case 1

A 10-year-old boy was referred to the Department of Pediatric Dentistry, School of Dentistry, São Paulo State University (UNESP), Araçatuba, São Paulo, Brazil, with the main complaint of "a swelling on the left side of his jaw." Intraoral examination revealed swelling, which produced bulging of the cortical bone of firm consistency (Figure 1). Radiographic examination showed a unilocular, radiolucent area:

1. extending to the mandible's lower border from the mandibular left first bicuspid on the distal side to the permanent mandibular left first molar; and
2. associated with the dental crown of the bud of the permanent mandibular left second molar.

¹Drs. Delbem and Cunha are assistant professor of Pediatric Dentistry,

²Drs. Afonso and Bianco are postgraduate students in Pediatric

Dentistry, and ³Dr. Idem is a specialist in Pediatric Dentistry, all at the School of Dentistry, São Paulo State University, Araçatuba, São Paulo, Brazil.

Correspond with Dr. Delbem at adelbem@foa.unesp.br

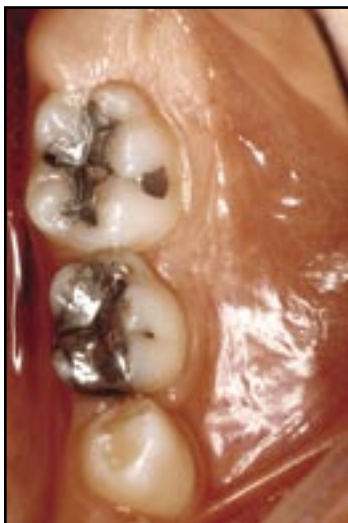

Figure 1. Case 1: Clinical appearance of cystic lesion showing a large swelling in the region of the primary mandibular second molar.

It showed clear limits and caused displacement of the latter (Figure 2). Cytopathologic examination of an aspiration biopsy showed compatibility with a cystic lesion, and the differential diagnosis suggested a dentigerous cyst.

Marsupialization was chosen as treatment. A space-maintaining appliance with a resin extension was used, penetrating inside the cystic pouch to help decompress the lesion. Prior to surgery, an alginate impression of the mandibular arch was made.

The primary mandibular left second molar was then extracted and the part of the cystic wall next to the extracted teeth was removed for decompression of the lesion. Surgical intervention was performed under local anesthesia. The appliance was then immediately installed, adapting the resin projection to the orifice obtained by surgery. The extent of penetration was sufficient to: (1) prevent the formation of a fibrous scar; and (2) permit decompression of the cystic pouch (Figure 3). Starting on the first postoperative day, the mother was instructed to:

1. irrigate inside the lesion with Listerine solution (Pfizer, São Paulo, Brazil) after each meal; and
2. clean the appliance.

Only analgesic medication was prescribed.

The removed surgical specimen was fixed in 10% formalin and decalcified in a solution with equal parts of 50% formic acid and 20% sodium citrate. Longitudinal paraffin sections were cut at 6 µm and stained with hematoxylin and eosin. The histopathologic examination confirmed the diagnostic hypothesis of a dentigerous cyst. The patient returned once a week for:

1. periodic clinical and radiographic examination; and
2. verification of the wear of the resin projection based on the eruption of the mandibular left first premolar, which started after 4 months of follow-up.

After this, the recall was monthly. At 13 months, the permanent premolar was erupted in the oral cavity (Figure 4).

Case 2

An 8-year-old boy was seen at the same institution, with the main complaint being prolonged retention of a primary tooth.

Intraoral clinical examination revealed a volumetric increase of the lingual cortical plate in the region of the primary mandibular right lateral incisor which showed prolonged retention. The patient did not complain of pain.

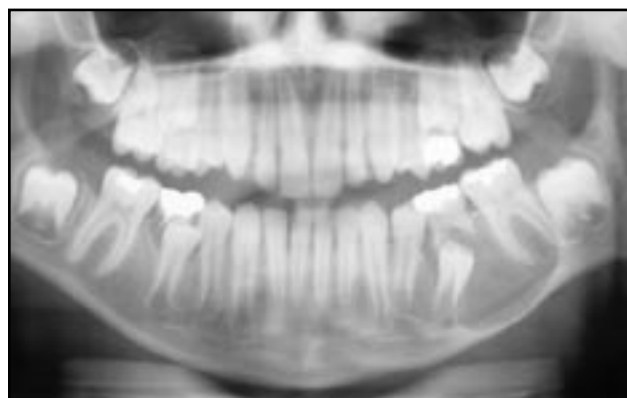


Figure 2. Case 1: Panoramic radiograph showing a large radiolucent area with displacement of the second premolar.

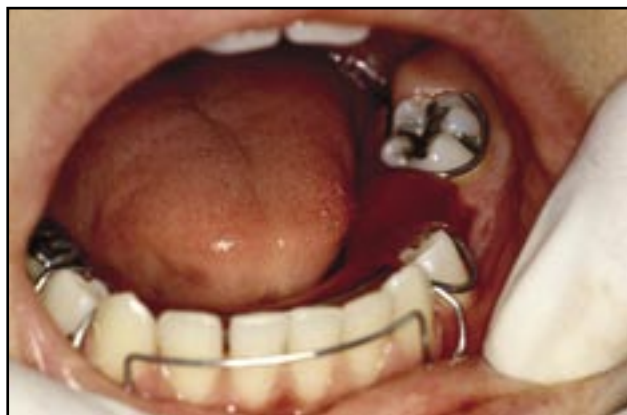

Figure 3. Case 1: Placement of a removable appliance with acrylic extension penetrating into the cystic cavity.

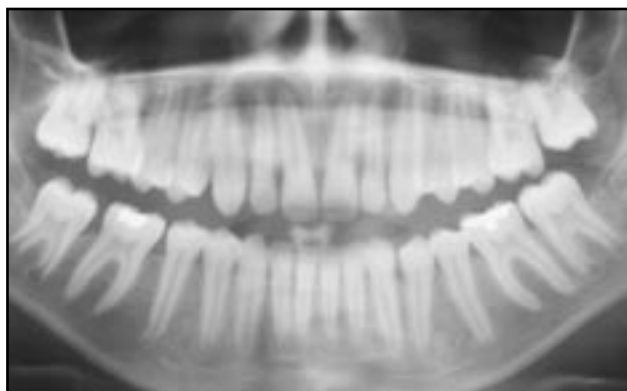

Figure 4. Case 1: Radiographic view 13 months postoperatively showing normal features and eruption of mandibular second premolar.

Radiographic examination showed a well-defined, unilocular, radiolucent area surrounding the crown of the bud of the permanent mandibular right lateral incisor, associated with root resorption of the primary lateral incisor and canine (Figure 5). Based on the clinical and radiographic aspects, the working diagnosis was a dentigerous cyst.

Treatment consisted of extraction of the primary mandibular right lateral incisor and primary mandibular right canine and, due to the small size of the lesion, total enucle-

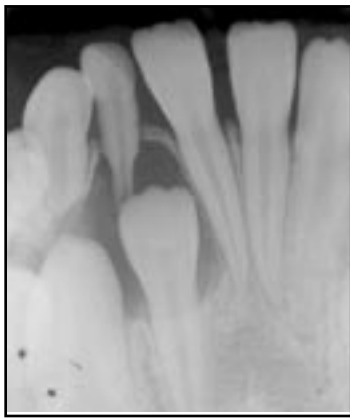
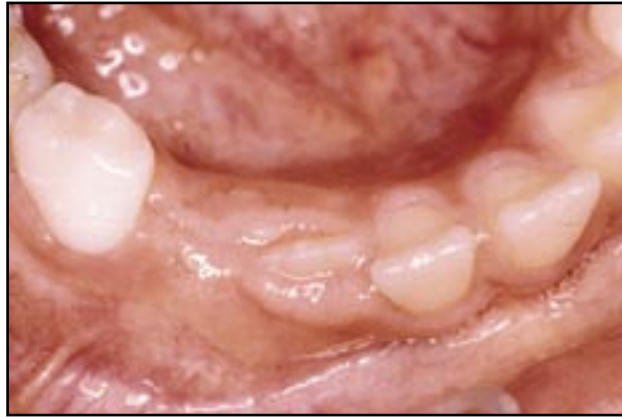
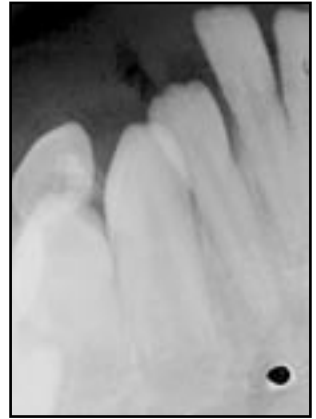
Figure 5. Case 2: Radiograph showing a radiolucent unilocular area circumscribing the crown of permanent incisor tooth.



Figures 6 and 7. Case 2: Clinical and radiographic view 7 months postoperatively showing normal features, new bone formation, and eruption of the permanent incisor.



ation was performed. A silk suture 4-0 (Ethicon, Somerville, NJ) was used and an analgesic (acetaminophen) was prescribed for postoperative treatment. The specimen was prepared and sent to histologic examination following the same steps as described in case 1.

The stitches were removed after 7 days, and a removable space-maintaining appliance was installed, which was fabricated on the basis of an impression obtained before surgery. The patient returned for clinical and radiographic follow-up once a month. After 7 months, eruptive movement of the permanent mandibular right lateral incisor was observed as well as new bone neoformation in the region (Figures 6 and 7).

Discussion

Although evidence in the literature suggests that dentigerous cysts occur more frequently during the second decade of life,^{10,11} these lesions can also be found in children and adolescents. The incidence of dentigerous cysts is twice as high in male patients.^{11,12} Although these cysts can be found throughout the oral cavity, Ustuner et al¹³ emphasized the posterior mandible as the most commonly affected region.

Marsupialization or decompression is a technique that attempts to relieve intracystic pressure through the creation of an accessory cavity.³ This technique was selected since it is a more conservative intervention for the treatment of large cysts, especially in pediatric dentistry, considering the frequent proximity of these lesions to the bud of developing permanent teeth, as observed here in the first patient.

After marsupialization, a removable space-maintaining appliance with a resin projection was used, which permitted decompression and prevented the entry of food into the cystic pouch. This procedure has successfully been applied by Delbem et al⁷ for the treatment of radicular cysts in children. The technique prevented the formation of fibrous scars, which can impair eruption of the permanent tooth. Cooperation of the parents was fundamental for treatment success. It is important to emphasize that the use of the

marsupialization technique for treating cysts involving developing buds requires follow-up of the case until the permanent teeth erupt.

In case 2, treatment was performed using the enucleation technique, as it is indicated for small size lesions.¹⁴ The patients with dentigerous cysts usually present no painful symptoms, which explains the detection of such lesions often during routine radiographic examination. The importance of this procedure as a diagnostic auxiliary should be emphasized.

In conclusion, a precise indication of the surgical technique in both cases led to a conservative and safe intervention.

References

1. Sands TC. Multiple dentigerous cysts in a child. *Oral Health* 1998;88:27-29.
2. Daley TD, Wysocki GP. The small dentigerous cyst: A diagnostic dilemma. *Oral Surg Oral Med Oral Pathol Oral Radiol Endod* 1995;79:77-81.
3. Bodner L, Woldenberg Y, Bar-Ziv J. Radiographic features of large cysts lesions of the jaws in children. *Pediatr Radiol* 2003;33:3-6.
4. Scholl RJ, Kellett HM, Neumann DP, Lurie AG. Cysts and cystic lesions of the mandible: Clinical and radiologic histopathologic review. *Radiographics* 1999;19:1107-1107.
5. Tuzum MS. Marsupialization of a cyst lesion to allow tooth eruption: A case report. *Quintessence Int* 1997;28:283-284.
6. Chakraborty A, Sarkar S, Dutta BB. Localized disturbances associated with primary teeth eruption. *J Indian Soc Pedod Prev Dent* 1994;12: 25-28.
7. Delbem AC, Cunha RF, Vieira AE, Pugliesi DM. Conservative treatment of radicular cyst in a 5-year-old child: A case report. *Int J Paediatr Dent* 2003;13:447-450.
8. Perez DM, Molare MV. Conservative treatment of dentigerous cysts in children. A report of 4 cases. *J Indian Soc Pedod Prev Dent* 1996;14:49-51.
9. Fortin T, Coudert JL, Francois B, Huet A, Niogret F, Jourlin M, et. al. Marsupialization of dentigerous cyst associated with foreign body using 3D CT images: A case report. *J Clin Pediatr Dent* 1997;22:29-33.

10. Arotiba JT, Lawoyin JO, Obiechina AE. Pattern of occurrence of odontogenic cysts in Nigerians. *East Afr Med J* 1998;75:664-666.
11. Ziccardi VB, Eggleston TI, Schneider RE. Using fenestration technique to treat a large dentigerous cyst. *J Am Dent Assoc* 1997;128:201-205.
12. Benn A, Altini M. Dentigerous cysts of inflammatory origin. A clinicopathologic study. *Oral Surg Oral Med Oral Pathol Oral Radiol Endod* 1996;81:203-209.
13. Ustuner E, Fitoz S, Atasoy C, Erden I, Akyar S. Bilateral maxillary dentigerous cysts: A case report. *Oral Surg Oral Med Oral Pathol Oral Radiol Endod* 2003;95:632-635.
14. Singh S, Singh M, Chhabra N, Nagar Y. Dentigerous cyst: A case report. *J Indian Soc Pedod Prev Dent* 2001;19:123-126.

Abstract of the Scientific Literature



A New Method to Test for Malignant Hyperthermia

Malignant hyperthermia (MH) is an inheritable disorder that causes a life-threatening hyperthermia and hypermetabolism when a susceptible individual is exposed to general anesthetic triggering agents. Clinical signs include unexplained elevation of end-tidal carbon dioxide, muscle rigidity (masseter spasm), acidosis, tachycardia, hyperthermia, and evidence of rhabdomyolysis. Because of improved monitoring standards that allow for early detection of hypercarbia during general anesthesia and the availability of dantrolene, the mortality from MH is now estimated to be less than 5%. This clinical report provides a review of the pathophysiology and clinical update of new tests available for gene mapping.

An MH crisis is precipitated by an abnormal release of calcium from the sarcoplasmic reticulum (SR), which is often caused by an inherited mutation in the gene for the ryanodine receptor (RYR1) that resides in the membrane of the SR. Two susceptible genes have been identified, and 4 have been mapped to specific chromosomes. Dantrolene sodium binds to RYR1, reversing the uninhibited flow of calcium into the sarcoplasm. The gold standard test for determining MH susceptibility is the caffeine-halothane contracture test (CHCT) using skeletal muscle biopsy. This invasive test can cost more than \$6,000 and is often not covered by third-party payers.

Researchers have now begun to map mutations within the ryanodine receptor gene (chromosome 19q13.1) responsible for conferring MH susceptibility. More than 60 mutations in RYR1 have been associated with the abnormal contracture test. The RYR1 screening is approximately \$800, and a simple DNA sample for this test can be obtained from buccal cells, white blood cells, muscle cells, or other tissues. The North American mutation analysis protocol currently screens for 17 of the most common RYR1 mutations, and is expected to detect up to 25% of patients with MH susceptibility.

Comments: Many of us have decreased the amount of in-office sedation and increased utilization of ambulatory hospital operating room time. Malignant hyperthermia is an important pharmacogenetic clinical syndrome that we all should be familiar with. This article provides a good review of the pathophysiology and useful application of gene mapping, which will undoubtedly become commonplace for future susceptibility testing. **SU**

Address correspondence to Dr. Ronald S. Litman, Department of Anesthesiology & Critical Care Medicine, The Children's Hospital of Philadelphia, 34th Street & Civic Center Boulevard, Philadelphia, PA 19104.

Litman RS, Rosenberg H. Malignant hyperthermia update on susceptibility testing. *JAMA* 2005;293:2918-2924.

52 references

Copyright of Pediatric Dentistry is the property of American Society of Dentistry for Children and its content may not be copied or emailed to multiple sites or posted to a listserv without the copyright holder's express written permission. However, users may print, download, or email articles for individual use.