



# Comparison of Conventional, Rotary, and Ultrasonic Preparation, Different Final Irrigation Regimens, and 2 Sealers in Primary Molar Root Canal Therapy

Harun Canoglu, DDS, PhD<sup>1</sup> Meryem U. Tekcicek, DDS, PhD<sup>2</sup> Zafer C. Cehreli, DDS, PhD<sup>3</sup>

## Abstract

**Purpose:** The aim of this study was to compare the shaping effectiveness rotary nickel-titanium (Profile .04 ISO), ultrasonic (K-Type/Satelec), and stainless-steel hand file (K-file/Maillefer) instrumentation and to assess tubular penetration of 2 gutta percha sealers (AH Plus and Sealite-Ultra) following 4 different final irrigation regimens in primary molar roots.

**Methods:** Distal roots of extracted human primary second molars were prepared with 1 of the 3 instrumentation techniques. Direct digital radiographs were obtained on a custom-made platform before and after instrumentations. The amount of dentin removal, canal transportation, centering of preparation, changes in root curvature and working length, and zip formation were evaluated using image analysis.

**Results:** While no significant differences were found between the 3 preparation techniques in regards to dentin removal ( $P > .05$ ), ultrasonic instrumentation significantly increased the incidence of zip formation ( $P < .05$ ) and decreased working length ( $P < .05$ ). Following final irrigation with 2.5% sodium hypochlorite (NaOCL), 10% ethylenediaminetetraacetic acid (EDTA), 17% EDTA, or distilled water (control), tubular penetration of the tested sealers were investigated under scanning electron microscope. Use of AH Plus after 17% EDTA irrigation exhibited the best tubular penetration.

**Conclusions:** Root canal preparation with Profile .04 ISO nickel titanium instruments can be a viable alternative to manual instrumentation in primary teeth. When used as a gutta percha sealer, AH Plus exhibits good tubular penetration when 17% EDTA is used for final flush. (Pediatr Dent 2006;28:518-523)

**KEYWORDS:** PRIMARY TOOTH, ROOT CANAL PREPARATION, ROOT CANAL IRRIGANTS, ROOT CANAL SEALANTS, IMAGE ANALYSIS

Received February 22, 2006 Revision Accepted June 14, 2006

Pulpectomy is indicated in a primary tooth with irreversible pulpitis in a tooth treatment planned for pulpotomy in which the radicular pulp exhibits clinical signs of pulp necrosis such as excessive hemorrhage.<sup>1,2</sup> Traditionally, roots of such teeth have been shaped mechanically using endodontic broaches and hand files,<sup>3</sup> utilizing various irrigants that include: (1) saline solution; (2) sterile water; (3) chlorhexidine; and (4) sodium hypochlorite (NaOCL).<sup>3-6</sup> The roots are then obturated with a resorbable paste.<sup>7</sup>

Pulpally involved retained primary molars with missing permanent successors present a unique clinical challenge. In such teeth, root canal therapy with a sealer and nonresorbable obturation material (gutta percha) and an appropriate

final restoration are viable treatment options to maintain occlusal function and arch integrity.<sup>5,8</sup> Nevertheless, effective root canal therapy using routine "adult" endodontic techniques may be difficult to attain in retained primary molars. This is due to:

1. the inherent limitations in the preparation of widely divergent, curved, and fragile primary molar roots<sup>9</sup>;
2. at least 3 parameters that have not been studied in detail or have remained uninvestigated to date:
  - a. preparation techniques;
  - b. irrigation regimes; and
  - c. use of root canal sealers.

The possibility of utilizing nickel-titanium (Ni-Ti) rotary files and ultrasonics in primary root canals has been proposed<sup>3</sup> and studied<sup>4</sup> compared to manual instrumentation techniques. The scope of those studies, however, have been limited to assessment of their cleaning capacity by dye removal<sup>4</sup> or by the ability to remove labelled bacteria.<sup>6</sup>

<sup>1</sup>Dr. Canoglu is research assistant, and Drs. <sup>2</sup>Tekcicek and <sup>3</sup>Cehreli are associate professors, all in the Department of Pediatric Dentistry, Faculty of Dentistry, Hacettepe University, Ankara, Turkey. Correspond with Dr. Cehreli at zcehrel@yahoo.com



Moreover, only one previous study has investigated the effect of various irrigation solutions on the adaptation of a resorbable sealer paste in primary roots.<sup>7</sup>

Consequently, the aim of the present study was to investigate several parameters of primary molar root canal preparation using: (1) manual techniques; (2) rotary techniques; and (3) ultrasonic techniques. Using direct digital radiography and image analysis, the parameters evaluated were: (1) amount of dentin removal; (2) canal transportation; (3) centering of root canal preparation; (4) changes in root curvature and working length; and (5) incidence of zip formation. Additionally, the effects of 4 final irrigation regimes on the adaptation and tubular penetration of 2 different root canal sealers were evaluated morphologically under scanning electron microscope (SEM).

## Methods

### Specimen preparation

Human primary mandibular second molars, extracted because of pulpal abscesses or for orthodontic reasons, were stored in distilled water at 4°C until experiments were conducted. The teeth were gathered following informed consent, approved by the Institutional Review Board of Hacettepe University, Ankara, Turkey. Inclusion criteria stipulated that the teeth had a nonresorbed, curved distal root, with the curvature angle ranging from 20° to 30°. Distal roots of primary mandibular second molars were preferred, since they generally have a curved, large, single root canal with a uniform canal outline and relatively less intracanal ramifications compared to their mesial roots. Moreover, a pilot study showed that, in mesial roots, images of buccal and lingual canals tend to superimpose on each other, complicating the measurement procedures.

The mesial roots were removed and the distal roots were embedded into standardized autopolymerizing acrylic resin blocks. Thereafter, endodontic access was gained and radiographs were taken from the distal canal with size 10 K Files (Dentsply/Maillefer, Ballaigues, Switzerland) to determine the curvature angles as described by Schneider<sup>10</sup> (Figure 1). Working length was set at 1 mm short of the apical foramen. Then, teeth with similar mean curvature angles were assigned into 3 separate groups (N=14/group):

1. Group 1: Mechanical hand filing was performed in a step-back manner with K-files up to size no. 30. Irrigation was performed with 10 ml of 2.5% NaOCL after each instrument. The file was discarded after preparation of each canal.
2. Group 2: Root canal preparation was performed crown down with nickel titanium rotary Profile .04 ISO (Dentsply/Tulsa Dental, Tulsa, Okla) instruments up to .04 /30 file in strict accordance with the manufacturer's recommendations. The files were activated by a Novag TCM Endo motor (Goldach, Switzerland) at 250 rpm. Irrigation was performed as it was with group 1.

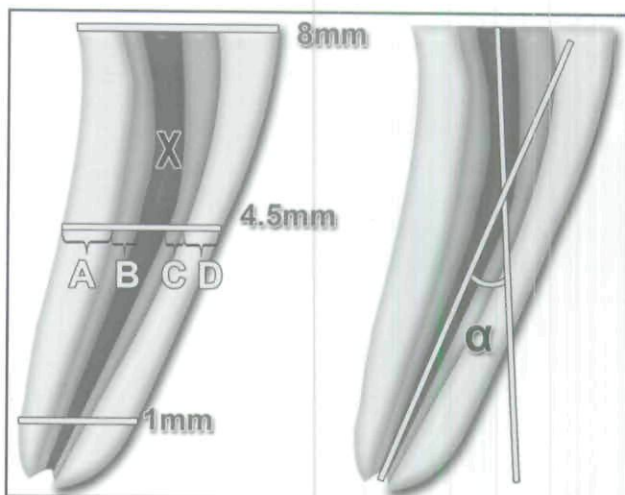


Figure 1. A schematic view of the references used for calculations. Left: Postinstrumentation thickness of dentin at the inner curvature (A); amount of dentin removed at the inner curvature (B); amount of dentin removed at the outer curvature (C); postinstrumentation thickness of dentin at the outer curvature (D); preinstrumentation thickness of the root canal (X). Right: Measurement of root canal curvature, according to Schneider's technique<sup>10</sup>.

3. Group 3: Root canals were prepared using a piezzo-ultrasonic system (Suprasson P5 Booster, Satelec, France) utilizing ultrasonic K files (21 mm) up to size no. 30. For each size (K10/21, K15/21, K25/21, and K/30/21), the file tip was placed into the canal at the predetermined working length and was operated for 60 seconds at medium frequency, with a light filing action around the circumference of the root canals. Irrigation was performed with 10 ml 2.5% NaOCL after each instrument.

### Image analysis and assessment of canal instrumentation

Digital radiographs of the specimens were obtained with a parallel technique (at 70 kVp and 0.1 seconds exposure) using a radiovisiography (RVG) unit (IRIX 70, Trophy, Croissy-Beaubourg, France) before and after instrumentation. During both procedures, the specimens were placed in a custom-made precision platform mounted on the cone of the X ray tube. This enabled the exact repositioning of the sample used for the initial RVG and the standardized alignment of the RVG sensor and radiographic beam. The images were magnified and analyzed in ImageJ<sup>11</sup> open-source image analysis software (V.1.34, National Institutes of Health, Bethesda, Md) so that pre- and postoperative images of the canals could be outlined and superimposed. The reference for exact superimposition and calibration of the scale of ImageJ for measurements was provided by a 2-m stainless steel orthodontic wire fixed to the platform and radiographed with all teeth.

For each root, the removed dentin was measured at 3 standardized reference points (1 mm/apical, 4.5 mm/mid-root, and 8 mm/coronal), determined in a pilot study.



At each reference point, the measurements were performed on both the inner and outer sides of the curvature (Figure 1),<sup>12,13</sup> and canal transportation (expressed as an absolute value) was assessed by subtracting the amount of dentin removed from the inner side from that removed from the outer side.<sup>12,13</sup> The ability of the tested instruments to remain centered in the canal was determined by calculating a centering ratio of the greater amount of removed dentin over that of the lesser value.<sup>13</sup> Changes in working length and root canal curvature were determined by subtracting the respective pre- and postoperative values.<sup>12</sup> Zipping (eliptication) is the transportation of the outer wall of the apical foramen due to an overextended file<sup>14</sup> (Figure 2). Zip formation was assessed on postoperative images by 2 separate investigators who were blinded to treatment allocations and to each other. First, each investigator rated incidence of zip formation as "present" (score 1) or "absent" (score 2). Next, a consensus evaluation was made between the investigators. When differences arose, score 2 was given.

One-way analysis of variance (ANOVA) and the Duncan multiple comparison test (at  $P=.05$ ) were used to compare: (1) dentin removal; (2) canal transportation; (3) centering ability; and (4) changes in working length and root canal curvature. The presence of zip was evaluated statistically using the chi-square test ( $P=.05$ ).

#### Assessment of tubular penetration of 2 sealers after different irrigation regimes

Distal roots of 56 extracted human primary mandibular second molars were selected as with preparation experiments. Mechanical hand filing was performed using K-files up to size no. 30. Irrigation was performed with 10 ml 2.5% NaOCL after each instrument. The roots were then randomly distributed into 4 groups ( $N=14$ /group) to receive the following final irrigations: (1) group 1=10 ml 2.5% NaOCL; (2) group 2=10 ml 10% ethylenediaminetetraacetic acid (EDTA; pH=7.4); (3) group 3=10 ml 17% EDTA (pH=7.4); and (4) group 4=10 ml distilled water. In groups 1, 2, and 3, the canals were subsequently irrigated with 10 ml distilled water to neutralize the effect of final irrigants.

Samples in each irrigation group were further randomly assigned into 2 subgroups ( $N=7$  each), in which either AH Plus (Dentsply/DeTrey, Konstanz, Germany) or ZOE-based Sealite-Ultra (Produits Dentaires Pierre Roland, Cedex, France) were used as root canal sealers, utilizing a lentulo spiral technique. Final obturation was achieved using gutta percha with a cold lateral compaction technique, and the

**Table 1. Dentin Removal Along the Canal at 3 Measurement Points (1 mm, 4.5 mm, and 8 mm)\***

	Inner canal wall			Outer canal wall		
	1 mm Mean±(SD)	4.5 mm Mean±(SD)	8 mm Mean±(SD)	1 mm Mean±(SD)	4.5 mm Mean±(SD)	8 mm Mean±(SD)
Group 1 K files	0.04±0.04	0.08±0.05	0.1±0.09	0.1±0.11	0.02±0.17	0.11±0.04
Group 2 Profile ISO .04	0.05±0.09	0.1±0.06	0.13±0.06	0.06±0.08	0.08±0.11	0.08±0.05
Group 3 Ultrasonics	0.03±0.02	0.08±0.05	0.2±0.12	0.12±0.08	0.11±0.06	0.11±0.09

\*One-way ANOVA and Duncan multiple comparison tests; no significant differences (all  $P>.05$ )

**Table 2. Changes in Working Length (mm), Curvature Angle (°), and Incidence of Zip Formation (%) After Preparation With the Tested Methods\***

	Working length Mean±(SD)	Curvature angle Mean±(SD)	Zip formation (%)
Group 1 K files	0.07±0.52	1.96±0.78	33
Group 2 Profile ISO .04	0.11±0.12	1.61±1.18	17
Group 3 Ultra- sonics	0.27±0.16†	2.07±1.46	67†

\*One-way ANOVA and Duncan multiple comparison tests were used for comparing working length and curvature angle at  $P=.05$ . Incidence of zip formation was compared statistically with chi-square test ( $P=.05$ ).

†Significantly different than groups 1 and 2 at  $P=.05$ .

excess gutta percha was removed to 1 mm below the cemento-enamel junction. Completed teeth were wrapped in moist gauze and stored in separate vials in a 37°C incubator for 1 week to ensure proper setting of the sealer cement. Thereafter, the roots were split longitudinally into 2 parts, sputter-coated with 20 Å gold, and investigated qualitatively under an SEM for surface adaptation and tubular penetration.

## Results

### Preparation techniques and canal form

The mean amounts of dentin removal on the inner and outer side of curvature are presented in Table 1. At all measurement points, mean canal widths were quite regular after instrumentation and no significant differences were found between the 3 preparation techniques ( $P>.05$ ). Only a numeric comparison of data could show that preparation with ultrasonic files resulted in the greatest amount of dentin removal in the inner and outer wall combined at all levels (Table 1).

Compared to groups 1 and 2, preparation with ultrasonic



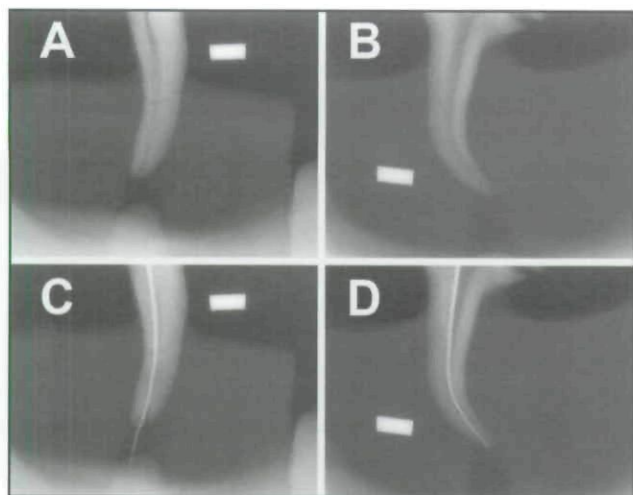


Figure 2. Two representative examples from the present study showing zip formation. Preoperative radiographs (A and B). Post-instrumentation radiographs of A and B (C and D, respectively). A precurved gutta-percha cone has been used to enhance contrast along the canal wall.

files significantly decreased the working length ( $P < .05$ ; Table 2). Additionally, the incidence of zip formation was significantly greater in group 3 (ultrasonic files) than that in groups 1 and 2 ( $P < .05$ ; Table 2, Figure 2). Although no significant differences were found ( $P > .05$ ), all tested preparation techniques exhibited a decrease in root canal curvature, with Profile instrumentation maintaining the relatively best curvature in terms of numerical comparison of data (Table 2).

There were no significant differences in canal transportation and canal centering values combined at all levels (Table 3;  $P > .05$ ). Again, numeric comparison of data showed that the greatest amount of canal transportation at reference points 1 mm and 4.5 mm were obtained with the ultrasonic files ( $0.1 \pm 0.15$  mm,  $0.09 \pm 0.04$  mm, respectively).

Table 3. Transport and Centering Values at 3 Measurement Points (1 mm, 4.5 mm, and 6 mm)\*

	Transport			Centering		
	1 mm	4.5 mm	8 mm	1 mm	4.5 mm	8 mm
Group 1 K files	$0.096 \pm 0.07$	$0.06 \pm 0.04$	$0.21 \pm 0.29$	$0.35 \pm 0.18$	$0.20 \pm 0.19$	$0.46 \pm 0.36$
Group 2 Profile ISO .04	$0.095 \pm 0.08$	$0.08 \pm 0.04$	$0.06 \pm 0.05$	$0.16 \pm 0.19$	$0.33 \pm 0.038$	$0.57 \pm 0.31$
Group 3 Ultrason- ics	$0.10 \pm 0.15$	$0.09 \pm 0.04$	$0.17 \pm 0.12$	$0.17 \pm 0.39$	$0.34 \pm 0.25$	$0.34 \pm 0.34$

\*No significant differences at  $P = .05$  (Duncan multiple comparison test).

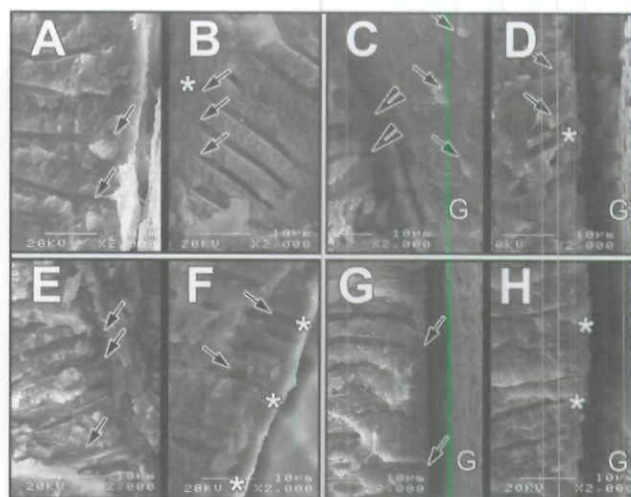


Figure 3. Representative scanning electron micrographs of sealer-dentin interfaces. NaOCL+AH Plus (A); smear plugs are evident (arrows). NaOCL+Sealite-Ultra (B); a distinct smear layer (asterisk) and smear plugs (arrows) is seen. 10% EDTA+AH Plus (C); despite opened tubule orifices, the sealer has failed to show signs of penetration (arrowheads). 10% EDTA+Sealite-Ultra (D); tubular penetrations (arrows) and empty tubules (asterisk) are evident. 17% EDTA+AH Plus (E); the sealer has successfully penetrated the majority of dentinal tubules (arrows). 17% EDTA+Sealite Ultra (F); despite a uniform surface seal (asterisks), tubular penetration is extremely poor (arrows). Slight tubular projections of the sealer (arrows) have remained attached on the gutta percha (G). Final irrigation with distilled water has failed to remove smear (arrows and asterisks) in both groups (G and H).

#### Irrigation regimes and tubular penetration by 2 sealers

Representative SEM images of the sealer-dentin interface in regards to irrigation regimes are presented in Figure 3. As expected, final irrigation with NaOCL (group 1) and distilled water (group 4) failed to remove smear, resulting in a poorly adapted sealer-dentin interface with no signs of tubular penetration (Figures 3a, 3b, 3g, and 3h, respectively). Removal of smear plugs with 10% EDTA solution (group 2) enhanced partial tubular penetration of Sealite-Ultra (Figure 3d), while AH Plus failed to penetrate dentinal tubules (Figure 3c). The best tubular penetration was observed in group 3 (17% EDTA), when AH plus was used as a sealer (Figure 3e).

#### Discussion

Several methods have been used to investigate the effect of preparation techniques in root canals.<sup>15-18</sup> Direct digital radiography was used in the present study, since it allows



a relatively easy and repeatable comparison and analysis of several parameters of pre- and postinstrumentation root canal anatomy.<sup>19,20</sup> Compared to microcomputed tomography—the gold standard of nondestructive techniques,<sup>21</sup>—the limiting aspects of direct digital radiography are: (1) relatively inferior resolution<sup>21,22</sup>; and (2) being only 2-dimensional.<sup>12</sup> Also worth considering is the use of extracted teeth herein, which provides greater reliability of the results compared with artificial resin canals.<sup>12</sup> Preparing a tooth for root canal treatment in vivo and in vitro, however, can be substantially different. Thus, the results obtained herein must be interpreted with caution. Differences in the temperature and humidity of the root canal, morphological variations, pooling of irrigation media at the apical level (in mandibular teeth), and the direction of force applied during instrumentation (which may affect transport and centering) are some of the many clinical variables that may result in a different outcome.

While the analysis of pre- and postinstrumentation data showed that the overall efficiency of preparation provided by the tested systems were not significantly different, comparison of numerical data revealed that Profile .04 ISO instrumentation maintained the root canal curvature with:

1. relatively less canal transport at the apical (1 mm) and coronal (8 mm) levels of the primary root canals; and
2. better centering at the apical level (Table 3).

Employing a dye removal methodology, Silva et al<sup>6</sup> reported that there was no statistical difference between manual instrumentation with K files and rotary preparation with Profile 0.4 ISO instruments in terms of cleaning in primary root canals. In the same study<sup>6</sup> and in another report,<sup>2</sup> root canal preparation with Profile 0.4 ISO instruments were also shown to reduce preparation time significantly compared to manual instrumentation. Yoshimine et al<sup>23</sup> compared the shaping effectiveness of 3 different rotary instruments (ProTaper, K3 and RaCe) on resin blocks. They reported that ProTaper files removed more radicular dentin than K3 and RaCe systems, with a tendency toward ledge and zip formation at the apical level. They concluded that nickel titanium files, including less-tapered and more flexible instruments (eg, K3 and RaCe), should be used in the apical preparation of canals with a complicated curvature, since the relative rigidity of the ProTaper system resulted in: (1) reduced canal curvature; (2) increased apical transportation; and (3) apical irregularities (ledge and zip). Unlike ISO .04 files, the manufacturers of those rotary systems do not indicate the possible use of their files in primary molars. Due to their specific design and flexibility, however, further in vitro studies should include these systems to determine the optimal rotary system in primary teeth.

Although not significantly different from group 1 (K files), preparation with Profile instruments resulted in relatively less incidence of zip formation and a slightly greater loss of working length in the present study (Table 2). Overall, the results obtained within this study's experimental

limitations suggest that preparation with Profile .04 ISO nickel-titanium instruments could be a viable alternative to manual instrumentation in primary teeth, provided that concerns regarding cost-effectiveness is excluded.

Previous work by Seow<sup>4</sup> has shown that ultrasonication of primary root canals significantly reduces the number of residual bacteria compared to conventional filing. While this appears to be a desirable effect concerning the high prevalence of accessory canals and intricate root canal systems in primary teeth,<sup>24,25</sup> it has not possible to recommend use of the tested ultrasonic system herein; due to the significantly higher incidence of zip formation and loss of working length (Table 2). Definitely, more research into other ultrasonic systems is indicated before routine use of this method can be advocated in primary teeth. It is, however, possible that a combination of shaping with rotary instruments and using ultrasonics only to irrigate after shaping may prove to be superior.

Penetration of root canal sealers into dentinal tubules can improve the sealing of the root canal system by increasing the interface between the filling material and dentin.<sup>26</sup> It is, thus, necessary to remove smear to facilitate tubular penetration of root canal sealers.<sup>27,28</sup> In the present study, the best tubular penetration was achieved with AH Plus, with sealer tags occasionally extending 50  $\mu$ m to 70  $\mu$ m into dentin, following a final irrigation with 17% EDTA. While irrigation with 10% EDTA was also effective at removing smear, AH Plus failed to exhibit penetration into the dentinal tubules. This finding can be explained by the insufficient opening of tubule orifices by 10% EDTA to permit effective penetration of AH Plus, as observed after irrigation with 17% EDTA.<sup>28</sup> Insufficient and non-homogenous tubular penetration of the ZOE-based sealer following irrigation with 10% EDTA is in line with previous work<sup>4</sup> which employed 10% EDTA followed by ZOE paste in primary roots. It is difficult, however, to explain why this relatively homogenous sealer failed to exhibit good tubular penetration after irrigation with 17% EDTA. Overall, these findings indicate that Sealite-Ultra cannot be recommended as a gutta percha sealer in retained primary molars.

Due to the scarcity of published data, this study was conducted to investigate several parameters of root canal therapy in retained primary molars. Many vital primary teeth without a permanent successor can undergo physiologic root resorption. If this would occur in a primary molar that had a gutta percha pulpectomy, treatment options would include endodontic retreatment or extraction.. It should be emphasized that the findings obtained herein cannot be entirely extrapolated to a physiologically resorbing primary molar root with succedaneous premolars. This is due to several factors, including:

1. complex anatomy of the resorbing root apex;
2. potential toxic effects of EDTA on the underlying tooth germ; and
3. low resorption/absorption potential of gutta percha sealers such as AH Plus.

More research is needed utilizing different rotary and ultrasonic systems, irrigation regimes, and sealers.



## Conclusions

Within the experimental conditions of the present study, the following conclusions can be made:

1. Root canal preparation with Profile .04 ISO nickel-titanium instruments can be a viable alternative to mechanical hand filing in primary molars, but ultrasonics can increase incidence of apical zip.
2. When used as a gutta-percha sealer, AH Plus exhibits good tubular penetration in conjunction with 2.5% NaOCL irrigation and 17% EDTA as final flush.

## References

1. Guideline on pulp therapy for primary and young permanent teeth. American Association of Pediatric Dentistry Reference Manual 2004-2005. *Pediatr Dent* 2004;7:115-16.
2. Primosch RE, Glomb TA, Jerrell RG. Primary tooth pulp therapy as taught in predoctoral pediatric dental programs in the United States. *Pediatr Dent* 1997;19:118-22.
3. Barr SE, Kleier DJ, Barr NV. Use of nickel-titanium rotary files for root canal preparation in primary teeth. *Pediatr Dent* 2000;22:77-8.
4. Seow WK. Comparison of ultrasonic and mechanical cleaning of primary root canals using a novel radiometric method. *Pediatr Dent* 1991;13:136-41.
5. Sullivan SM, Hartwell GR. Obturation of a retained primary mandibular second molar using mineral trioxide aggregate: A case report. *J Endod* 2001;27:703-05.
6. Silva LAB, Leonardo MR, Nelson-Filho P, Tanomaru JMG. Comparison of rotary and manual instrumentation techniques on cleaning capacity and instrumentation time in deciduous molars. *J Dent Child* 2004;71:45-7.
7. Alacam A. The effect of various irrigants on the adaptation of paste filling in primary teeth. *J Clin Pediatr Dent* 1992;16:243-46.
8. Cohen S, Burns RC. *Pathways of the Pulp*. 7<sup>th</sup> ed. St. Louis, Mo: Mosby Co; 1994:659-61.
9. Goerig AC, Camp JH. Root canal treatment in primary teeth: A review. *Pediatr Dent* 1983;5:33-7.
10. Schneider SW. A comparison of canal preparations in straight and curved canals. *Oral Surg Oral Med Oral Pathol* 1971;32:271-75.
11. Abramoff MD, Magelhaes PJ, Ram SJ. Image processing with ImageJ. *Biophotonics Int* 2004;11:36-42.
12. Veltri M, Mollo A, Pini PP, Ghelli LF, Balleri P. In vitro comparison of shaping abilities of ProTaper and GT rotary files. *J Endod* 2004;30:163-66.
13. Gambill JM, Alder M, Del Rio CE. Comparison of nickel-titanium and stainless steel hand-file instrumentation using computed tomography. *J Endod* 1996;22:369-75.
14. Vertucci FJ, Haddix JE, Britto LR. Tooth morphology and access cavity preparation. In: Cohen S, Hargreaves KM, eds. *Pathways of the Pulp*. 9<sup>th</sup> ed. St Louis, Mo: Mosby Co; 2006:148-232.
15. Bramante CM, Berbert A, Borges RP. A methodology for evaluation of root canal instrumentation. *J Endod* 1987;13:243-45.
16. Tachibana H, Matsumoto K. Applicability of X ray computerized tomography in endodontics. *Endod Dent Traumatol* 1990;6:16-20.
17. Nielsen RB, Alyassin AM, Peters DD, Carnes DL, Lancaster JL. Microcomputed tomography: An advanced system for detailed endodontic research. *J Endod* 1995;21:561-68.
18. Rhodes JS, Pitt Ford TR, Lynch JA, Liepins PJ, Curtis RV. Microcomputed tomography: A new tool for experimental endodontology. *Int Endod J* 1999;32:165-70.
19. Sydney GB, Batista A, de Melo LL. The radiographic platform: A new method to evaluate root canal preparation in vitro. *J Endod* 1991;17:570-72.
20. Southard DW, Oswald RJ, Natkin E. Instrumentation of curved molar root canals with the Roane technique. *J Endod* 1987;13:479-89.
21. Stamm T, Kaup M, Hohoff A, Meier T, Meyer U. Validity of a three-dimensional public-domain system for contemporary endodontic research. *J Endod* 2003;29:801-05.
22. Peters OA, Peters CI, Schöninger K, Barbakow F. ProTaper rotary root canal preparation: Effects of canal anatomy on final shape analyzed by micro CT. *Int Endod J* 2003;36:86-92.
23. Yoshimine Y, Ono M, Akamine A. The shaping effects of three nickel-titanium rotary instruments in simulated S-shaped canals. *J Endod* 2005;31:373-75.
24. Ringlestein D, Seow WK. The prevalence of furcation foramina in primary molars. *Pediatr Dent* 1989;11:189-202.
25. Hibbard EP, Ireland RL. Morphology of the root canals of the primary molar teeth. *J Dent Child* 1957;24:250-57.
26. White RR, Goldman M, Lin PS. The influence of the smeared layer upon dentinal tubule penetration by endodontic filling materials. Part II. *J Endod* 1987;13:369-74.
27. Economides N, Liolios E, Kolokuris I, Beltes P. Long-term evaluation of the influence of smear layer removal on the sealing ability of different sealers. *J Endod* 1999;25:123-25.
28. Kokkas AB, Boutsoukis AC, Vassiliadis LP, Stavrianos CK. The influence of the smear layer in dentinal tubule penetration depth by three different root canal sealers: An in vitro study. *J Endod* 2004;30:100-02.

Copyright of Pediatric Dentistry is the property of American Society of Dentistry for Children and its content may not be copied or emailed to multiple sites or posted to a listserv without the copyright holder's express written permission. However, users may print, download, or email articles for individual use.