

# Case Report

## Dental Management of a Child with Congenital Sideroblastic Anemia: A Case Report

Rochelle G. Lindemeyer, DMD<sup>1</sup> • Erick Goldberg, DMD<sup>2</sup> • Andres Pinto, DMD, MPH<sup>3</sup>

**Abstract:** *The sideroblastic anemias comprise a heterogeneous group of acquired and congenital disorders which that have in common: (1) anemia; (2) the presence of ring sideroblasts in the bone marrow; and (3) impaired heme biosynthesis. Elevation in iron levels is secondary to a deficiency in mitochondrial physiology. Patients exhibit mild to moderate hemolysis due to peripheral red blood cell destruction, and often require regular blood transfusions. The purpose of this case report was to describe the dental management of a child with congenital sideroblastic anemia—a rare hematologic disorder—and to emphasize how important it is for pediatric dentists to be cognizant of a patient's hematologic profile before attempting to perform any dental procedure. The timing of the patient's transfusions regarding the scheduling of dental care is crucial for successful management and anticipation of possible complications. Preventive dentistry should be a hallmark of dental management for these children. (Pediatr Dent 2007;29:315-9)*

KEYWORDS: SIDEROBLASTIC, ANEMIA, CONGENITAL DISEASE, DENTAL MANAGEMENT, HEMOLYSIS

Sideroblastic anemias are a unique group of disorders that can rise from primary or secondary defects of mitochondrial metabolism and are characterized by ring sideroblasts in the bone marrow and impaired heme biosynthesis. These ring sideroblasts consist of erythroblasts containing excessive iron levels in the mitochondria.<sup>1</sup> This characteristic feature appears as Prussian blue-positive iron granules.<sup>2</sup> The high iron levels are the result of the mitochondria's inability to utilize it in hemoglobin synthesis, producing hypochromic-microcytic erythrocytes.<sup>3</sup>

Clinical manifestations of sideroblastic anemias present in a myriad of forms. The patient commonly suffers from: (1) fatigue; (2) dizziness; and (3) decreased tolerance to activity. Hemoglobin levels range from 4 g/dl to 10 g/dl.<sup>1</sup> Patients exhibit mild to moderate hepatosplenomegaly<sup>4</sup> and hemolysis due to peripheral erythrocyte destruction. This disease's morbidity and mortality is due in large part to iron overload rather than deficiency.<sup>5</sup> High iron levels may interfere with

growth and development. In addition, iron overload leads to cardiac arrhythmias and congestive heart failure.<sup>4</sup> Thus, serum ferritin levels and transferrin saturation should be routinely monitored to detect iron overload.<sup>1</sup> Sideroblastic anemia patients present unique challenges for the dental practitioner managing their care due to their constantly changing hematologic profile.

The purpose of this case report was to describe the first known documented case of the dental management of a pediatric patient diagnosed with sideroblastic anemia.

### Case report

The dental division of the Children's Hospital of Philadelphia, Philadelphia, Pa, was originally consulted in 2002 regarding a 3-year-old female with a history of congenital sideroblastic anemia and intermittent neutropenia. She was born via a normal spontaneous vaginal delivery with no familial history of bleeding disorders. At day 9, she presented with a fever and emesis and was admitted to the hospital to rule out sepsis. Thereafter, she had no regular medical care except for emergency room visits for flu-like symptoms. Her growth and development were found to be normal.

At age 21 months, the child was brought by the mother to the hospital again for pallor and decreased activity. At this time, she was found to have a hemoglobin level of 2 g/dL, a white cell count of  $6.2 \times 10^3/\mu\text{L}$ , and a platelet count of  $324 \times 10^3/\mu\text{L}$ . She received blood transfusions, and her hemoglobin

<sup>1</sup>Dr. Lindemeyer is Assistant Professor and Director, Pediatric Dental Residency Program, School of Dental Medicine, The University of Pennsylvania; <sup>2</sup>Dr. Goldberg is a pediatric dental resident at Stony Brook University School of Dental Medicine (at time of writing was a fourth year dental student at School of Dental Medicine, The University of Pennsylvania); and <sup>3</sup>Dr. Pinto is Assistant Professor and Director, Oral Medicine Clinic, Department of Oral Medicine, Department of Oral Medicine, School of Dental Medicine, The University of Pennsylvania, Philadelphia, Pa. Correspond with Dr. Lindemeyer at lindemeyer@email.chop.edu



rose to 10 g/dL. A viral respiratory panel was negative, and her urinalysis was normal. An initial bone marrow biopsy showed dyserythropoiesis and ringed sideroblasts. She was, at that time, an inpatient receiving transfusions, as her hemoglobin was found to drop about 1 g/dL/week. At the time of consultation, the patient received red blood cell transfusions every 4 weeks. Her dental examination revealed a full primary dentition with the primary maxillary incisors abscessed and nonrestorable. Because her hemoglobin, platelet levels, and white blood cell counts were all within normal limits post transfusion, it was decided, in conjunction with the hematology department, to take the patient to the operating room for extraction of the 4 maxillary incisors under general anesthesia.

The patient had been placed on a course of clindamycin for her history of intermittent neutropenia in spite of the fact that her current absolute neutrophil count (ANC) at the time was within normal limits. The patient was intubated, and the mouth was swabbed with 0.12% chlorhexidine gluconate to reduce bacterial load. Resorbable cellulose and chromic sutures were used to ensure hemostasis. Her clinical recovery was uneventful, and she was scheduled for routine follow-up care in the dental clinic. Compliance with follow-up dental visits was extremely poor, and the patient did not return until 3 years later.

to any medications. She had a liver and muscle biopsy as well as a lumbar puncture the previous year under general anesthesia. No cardiovascular problems were reported.

The dental examination revealed an early mixed dentition with extremely poor oral hygiene with calculus accumulation. Bitewing radiographs (Figure 1) were taken, and caries lesions were noted on several teeth. She had a Class I occlusion on both sides. The permanent maxillary anterior teeth were unerupted. The management of this patient proved to be challenging due to the patient's: (1) level of cooperation in the dental setting; (2) severe dental needs; (3) poor compliance with dental care; and (4) hematological status.

After consulting with the hematology department, a plan was formulated to complete the patient's care under general anesthesia in the operating room. Her hematologist recommended that she receive a blood transfusion no more than 1 week prior to the scheduled dental rehabilitation so that she would not be too anemic. Unfortunately, the first scheduled operating room date had to be cancelled, as the patient missed her appointment for the required transfusion. The case was rescheduled to coincide with the week following her next transfusion.

Blood values prior to the planned oral rehabilitation are reported in Table 1. As noted, the hematocrit, hemoglobin and red blood cell values were all below normal levels. The

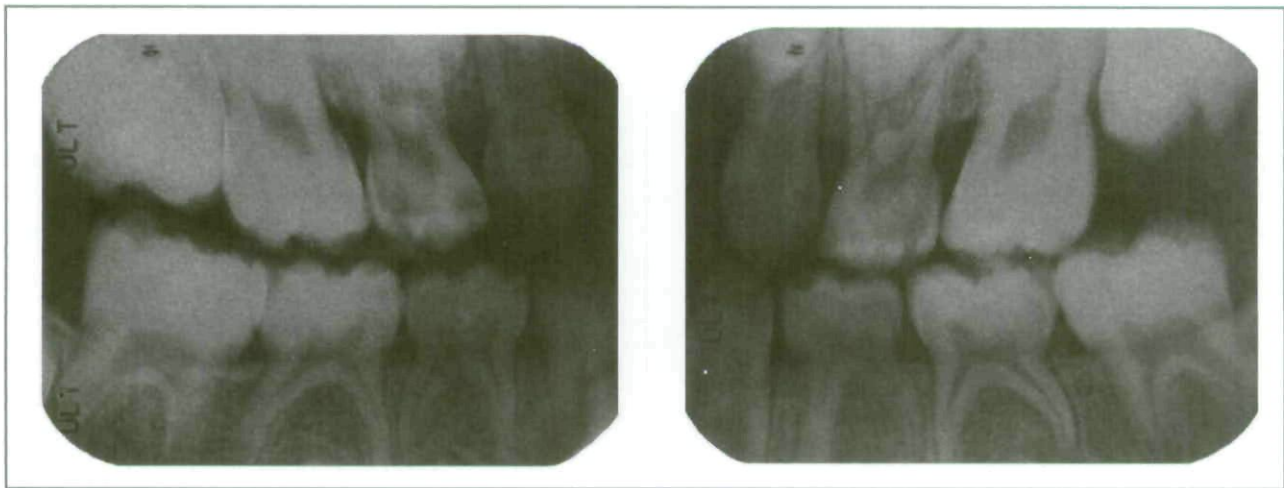


Figure 1. Pretreatment bitewing radiographs of a 7-year-old patient with sideroblastic anemia.

At age 7, the patient was again brought to the dental clinic. The mother reported that the patient was being seen in the hematology clinic and receiving blood transfusions every 3 weeks. Her last transfusion had been 4 days previous to this visit. Because of the frequent transfusions, the patient had significant iron overload, for which she took 1 g of deferoxamine (Desferal) daily. She was also taking folic acid on a daily basis. Previous trials of pyroxidine and thiamine had both proven unsuccessful. There were no reported allergies

child received a blood transfusion the following day. Her blood values returned to within normal range, and 6 days later the patient was taken to the operating room. She was: (1) nasally intubated; (2) given 1 g ampicillin; and (3) swabbed in the mouth with 0.12% chlorhexidine gluconate prior to the dental procedure.

A full series of radiographs was made at this time, including periapical and occlusal films. After a thorough scaling and prophylaxis, a treatment plan was generated and all



carious primary teeth were restored with either reinforced glass ionomer resins or stainless steel crowns. The 4 permanent first molars received sealants. There was no excessive bleeding, and the patient was discharged the same day. A postoperative appointment was scheduled for 3 weeks following surgery, which the family failed to keep.

**Table 1. BLOOD PROFILE PRETRANSFUSION AND POST-TRANSFUSION FOR A 7-YEAR-OLD PATIENT WITH SIDEROBLASTIC ANEMIA\***

	PRETRANSFUSION (6 DAYS PRIOR TO DENTAL REHABILITATION IN OR†)	POST-TRANSFUSION (DAY OF DENTAL REHABILITATION IN OR†)
RBC ( $\times 10^6/\mu\text{L}$ )	↓ 3.42 (4.0-5.2) ‡	4.1
WBC ( $\times 10^3/\mu\text{L}$ )	10.3 (5-14.5) ‡	7.4
Hemoglobin(g/dL)	↓ 9.7 (11.5-15.5) ‡	11.8
Hematocrit (%)	↓ 28.9 (35.0-45.0) ‡	35.8
Platelets ( $\times 10^3/\mu\text{L}$ )	278 (150-400) ‡	271

\* At the time of dental rehabilitation under general anesthesia.

† OR=operating room

‡ normal range

## Discussion

Sideroblastic anemia is classified based on its mechanism of transmission.<sup>1</sup> The acquired form is the most common, and it occurs as the result of medications and toxins. The hereditary form follows primarily by way of X-linked mutations and generally occurs in males. Sideroblastic anemia can also be of an idiopathic origin or associated with myelodysplastic syndromes, malignancy, or other systemic disorders.<sup>6</sup>

Advances in molecular medicine have proven useful in the search for the etiology of sideroblastic anemia. Investigation into hereditary or X-linked sideroblastic anemia has concluded that the disease's etiology may be a mutation in the gene found on the X chromosome encoding for erythroid specific 5-aminolevulinic acid synthase (ALAS-2).<sup>4-7</sup> ALAS-2 is the first and rate-controlling enzyme of heme synthesis in erythroid cells. This defect results in the excessive iron levels that typify sideroblastic anemias. The mutation commonly follows an X-linked pattern of transmission, but has also been found in other forms.<sup>8</sup>

A second group of hereditary X-

linked sideroblastic anemia results from defects in another gene that encodes an ATP-binding cassette protein.<sup>9</sup> Other types of sideroblastic anemia involve primary mitochondrial defects, including 2.7 kb to 7.767 kb deletion lesions of mitochondrial DNA.<sup>6</sup> Nuclear DNA mutations have been found in both autosomal dominant and recessive forms. Attempts have been made to improve the classification of subjects with sideroblastic anemia.<sup>10</sup> Nevertheless, an improved classification is challenged by the lack of quantitative information and considerable variability between the types and within the reported literature.

Sideroblastic anemia can present as a component of several syndromes characterized by partial deletion of mitochondrial DNA<sup>11,12</sup> (Table 2). Pearson's syndrome has been identified as a 4977 bp deletion in mitochondrial DNA, responsible for oxidative phosphorylation. Clinical presentation is similar to the clinical expression of sideroblastic anemia, though there is a less marked genetic transmission; the anemia is diagnosed as macrocytic and hyperchromic.<sup>13</sup> Diagnosis is also made earlier in life, and up to a quarter of affected infants are diagnosed prior to their first month of life.

The mitochondrial myopathy and sideroblastic anemia (MSA) syndrome was initially described by Rawles and Weller in 1974. MSA is a rare autosomal recessive disorder of oxidative phosphorylation and iron metabolism.<sup>14</sup> Although no specific gene has been identified as being responsible for the disease, an area of chromosome 12q24.33, and the PUS1 gene have been identified as candidate loci.<sup>15,16</sup>

Case reports have linked the Kearns Sayre syndrome to diabetes and Addison's disease.<sup>17-19</sup> The onset of symptoms is prior to age 20, and it has been proposed that this condition is the late stage representation of Pearson's syndrome.

**Table 2. SYNDROMES OF MITOCHONDRIAL METABOLISM LINKED TO SIDEROBLASTIC ANEMIA**

PEARSON'S SYNDROME (PEARSON'S MARROW PAN- CREAS SYNDROME)	MITOCHONDRIAL MYOPATHY AND SIDEROBLASTIC ANEMIA (MSA) SYNDROME	KEARNS-SAYRE SYNDROME
Refractory sideroblastic anemia	Severe muscle weakness	External ophthalmoplegia
Pancreatic dysfunction	Anemia in middle to late childhood	Pigmentary retinopathy
Vacuolization of marrow cells		Cardiac conduction
Hyperparathyroidism		abnormalities
Metabolic acidosis		Endocrine dysfunction
Pancytopenia		Muscular abnormalities
Failure to thrive		



Current research deals with the molecular characteristics of mitochondrial DNA deletion present in these syndromes and their influence in their phenotypic expression.

Treatment of severely anemic individuals suffering from sideroblastic anemias generally involves routine blood transfusions to: (1) maintain hemoglobin levels; (2) manage symptoms; and (3) allow normal growth and development.<sup>1-4</sup> A potential risk of these interventions is the development of autoimmunity to recurring transfusions, particularly if initiated at a young age. These patients are often on deferoxamine which is the current standard therapy for elimination of excess iron. Pursuit of a curative treatment for sideroblastic anemia has led to investigation of hematopoietic stem cell transplantation (HSCT) and nonmyeloablative allogeneic hematopoietic stem cell transplantation (NST). A successful case of HSCT treatment of a 34-month old boy with congenital sideroblastic anemia was reported in 1992,<sup>20</sup> and a recent case report highlighted one such incidence of NST.<sup>21</sup> NST, along with transfusion, was used to deplete iron stores on a 22-year-old patient when all other treatment options had failed. This case report showed that: (1) complete chimerism was present at 131 days; and (2) the patient was transfusion independent. Unfortunately, the patient would later succumb to fatal cardiovascular collapse as a result of refractory lactic acidosis. Three successful allogeneic stem cell transplants have been carried out on younger patients. All 3 patients survived and are transfusion independent.<sup>22</sup> Thus, these treatments reveal great potential and require further research.

The management of children with blood dyscrasias from a dental perspective can present a significant challenge. The pediatric dentist must always be cognizant of the patient's hematological profile before attempting to perform any dental procedures. The pediatric dentist must work in conjunction with the hematologist to coordinate the most optimal time for treatment. In this patient, due to her history of intermittent neutropenia and slightly decreased white blood cell count, the use of antimicrobial rinses and antibiotics before rendering care in the operating room was deemed advisable. Preventive dentistry should be the hallmark of dental management for these children. Unfortunately, psychosocial problems such as fear of health care and a low priority for dentistry can sometimes interfere, as in this case, and make compliance poor.

## References

- Alcindor T, Bridges KR. Sideroblastic anaemias. *Br J Haematol* 2002;116:733-43.
- Fleming MD. The genetics of inherited sideroblastic anemias. *Semin Hematol* 2002;39:270-81.
- Fontenay M, Cathelin S, Amiot M, Gyan E, Solary E. Mitochondria in hematopoiesis and hematological diseases. *Oncogene* 2006;25:4757-67.
- Bottomley SS. Congenital sideroblastic anemias. *Curr Hematol Rep* 2006;5:41-9.
- Beutler E, Felitti V, Gelbart T, Ho N. Genetics of iron storage and hemochromatosis. *Drug Metab Dispos* 2001;29:495-9.
- Lanzkowsky P. *Pediatric Hematology and Oncology*. 4th ed. London, England: Elsevier Academic Press; 2005.
- Bottomley SS, Healy HM, Brandenburg MA, May BK. 5-Aminolevulinic synthase in sideroblastic anemias: mRNA and enzyme activity levels in bone marrow cells. *Am J Hematol* 1992;41:76-83.
- Cox TC, Bawden MJ, Abraham NG, et al. Erythroid 5-aminolevulinic synthase is located on the X chromosome. *Am J Hum Genet* 1990;46:107-11.
- Shimada Y, Okuno S, Kawai A, Shinomiya H, Saito A, Suzuki M, et al. Cloning and chromosomal mapping of a novel ABC transporter gene (hABC7), a candidate for X-linked sideroblastic anemia with spinocerebellar ataxia. *J Hum Genet* 1998;43:115-22.
- Koc S, Harris JW. Sideroblastic anemias: Variations on imprecision in diagnostic criteria, proposal for an extended classification of sideroblastic anemias. *Am J Hematol* 1998;57:1-6.
- Zaffanello M, Zamboni G. Therapeutic approach in a case of Pearson's syndrome. *Minerva Pediatr* 2005;57:143-6.
- Mayes C, Sweeney C, Savage JM, Loughrey CM. Pearson's syndrome: A multisystem disorder. *Acta Paediatr* 2001;90:235-7.
- Alter BP. Bone marrow failure syndromes in children. *Pediatr Clin North Am* 2002;49:973-88.
- Naviaux RK. Mitochondrial DNA disorders. *Eur J Pediatr* 2000;159:S(3) 219-26.
- Zeharia A, Fischel-Ghodsian N, Casas K, Bykhovskaya Y, Tamari H, Lev D, et al. Mitochondrial myopathy, sideroblastic anemia, and lactic acidosis: An autosomal recessive syndrome in Persian Jews caused by a mutation in the PUS1 gene. *J Child Neurol* 2005;20:449-52.
- Wong LJ. Recognition of mitochondrial DNA deletion syndrome with non-neuromuscular multisystemic manifestation. *Genet Med* 2001;3:399-404.
- Karanikis P, Korantzopoulos P, Kountouris E, Dimitroula V, Patsouras D, Pappa E, et al. Kearns-Sayre syndrome associated with trifascicular block and QT prolongation. *Int J Cardiol* 2005;101:147-50.
- Laloi-Michelin M, Virally M, Jardel C, Meas T, Ingster-Moati I, Lomès A, et al. Kearns Sayre syndrome: An unusual form of mitochondrial diabetes. *Diabetes Metab* 2006;32:182-6.
- Boles RG, Roe T, Senadheera D, Mahnovski V, Wong LJ. Mitochondrial DNA deletion with Kearns Sayre syndrome in a child with Addison disease. *Eur J Pediatr* 1998;157:643-7.

20. Urban C, Binder B, Hauer C, Lanzer G. Congenital sideroblastic anemia successfully treated by allogeneic bone marrow transplantation. *Bone Marrow Transplant* 1992;10:373-5.
21. Medeiros BC, Kolhouse JF, Cagnoni PJ, Ryder J, Nieto Y, Rabinovitch R, et al. Nonmyeloablative allogeneic hematopoietic stem cell transplantation for congenital sideroblastic anemia. *Bone Marrow Transplant* 2003;31:1053-5.
22. Ayas M, Al-Jefri A, Mustafa MM, Al-Mahr M, Shalaby L, Solh H. Congenital sideroblastic anaemia successfully treated using allogeneic stem cell transplantation. *Br J Haematol* 2001;113:938-9.

## Abstract of Scientific Literature

### Cortisol levels and dental anxiety in ADHD

*This study tested the hypotheses that children with attention deficit hyperactivity disorder (ADHD), particularly those exhibiting severe hyperactivity and impulsivity, have a different stress reaction (measured by salivary cortisol) during a dental recall visit and are more dentally anxious than children in a control group. Eighteen children with ADHD and a control group of 71 children, all 13 yr of age, underwent a clinical dental examination and completed the Corah Dental Anxiety Scale (CDAS). Four saliva samples were gathered for analysis of cortisol: one prior to dental examination, one after, and two the following morning. There was a significant correlation between CDAS scores and cortisol concentrations prior to the dental examination within both the ADHD and the control groups. The subgroup ADHD with hyperactivity/impulsivity had significantly higher CDAS score, though paradoxically it always had lower cortisol concentrations than children in the control group. Behavioral expressions of anxiety in children with ADHD may be different from those in other children, not only due to the characteristics of their disorder, but also because of lower stress reactivity.*

**Comments:** ADHD with hyperactivity/impulsivity children have higher dental anxiety. These children need more behavior management to reduce anxiety for pediatric dental treatment. The level of salivary cortisol is not useful to indicate the dental anxiety in ADHD children since this population showed a blunted cortisol reaction in the present study. **YHW**

Address correspondence to Dr. My Blomqvist, Department of Pediatric Dentistry, Karolinska Institutet, PO Box 4064, SE-141 04 Huddinge, Sweden; email: My.Blomqvist@ki.se.

Blomqvist M, Holmberg K, Lindblad F, Fernell E, Ek U, Dahllöf G. Salivary cortisol levels and dental anxiety in children with attention deficit hyperactivity disorder. *Eur J Oral Sci* 2007; 115:1-6.

43 references

Copyright of Pediatric Dentistry is the property of American Society of Dentistry for Children and its content may not be copied or emailed to multiple sites or posted to a listserv without the copyright holder's express written permission. However, users may print, download, or email articles for individual use.