

# Scientific Article

## Primary Tooth Length Determination in Direct Digital Radiography: An In Vivo Study

Lourdes Santos-Pinto, DDS, MS, PhD<sup>1</sup> • Rita de Cássia Loiola Cordeiro, DDS, MS, PhD<sup>2</sup> • Angela Cristina Cilense Zuanon, DDS, MS, PhD<sup>3</sup>  
 Maria Daniela Basso, DDS, MS<sup>4</sup> • Marcela Almeida Gonçalves, DDS, MS<sup>5</sup>

**Abstract:** **Purpose:** The purpose of this in vivo study was to compare the accuracy of primary incisor length determined by direct digital radiography (straight-line measurement and grid superimposition) and measurement of the actual tooth length. **Methods:** Twenty-two primary maxillary incisors that required extractions were selected from 3- to 5-year-old children. The teeth were radiographed with an intraoral sensor using the long cone technique and a sensor holder (30-cm focus-to-sensor distance). The exposure time was 0.3 seconds. Tooth length was estimated by using straight-line and grid measurements provided by the distance measurement feature of the Computed Dental Radiography digital dental imaging system. The actual tooth length was obtained by measuring the extracted tooth with a digital caliper. Data were analyzed statistically by Pearson's correlation coefficient and a paired t test. **Results:** There were statistically significant differences ( $P=.007$ ) between the 2 measurement techniques and between the actual tooth lengths and grid measurements. There was no statistically significant difference ( $P=.38$ ) between straight-line measurements and actual tooth lengths, showing that the straight-line measurements were more accurate. Underestimation of the actual tooth length, however, occurred in 45% of the straight-line measurements and in 73% of the grid measurements. **Conclusion:** It is possible to determine primary tooth length in digital radiographs using onscreen measurements with a reasonable degree of accuracy. (*Pediatr Dent* 2007;29:470-4) Received November 20, 2006 / Revision Accepted March 8, 2007.

**KEYWORDS:** COMPUTER-ASSISTED IMAGING PROCESSING, DIAGNOSTIC IMAGING, DIGITAL RADIOGRAPHY, PRIMARY TOOTH, TOOTH LENGTH

Despite the preventive efforts of the dental community, dental caries is still prevalent in primary teeth and, if neglected, will lead to pulp necrosis. Pulpectomy is a common treatment for primary teeth with pulps undergoing irreversible pathological degeneration.<sup>1,2</sup>

One of the main challenges in root canal treatment is to determine how far working instruments should be advanced within the root canal. Working length determination is an important step of root canal therapy in the primary dentition because overinstrumentation of the root canals of a primary tooth may damage the permanent tooth germ.<sup>3</sup>

Root resorption of primary teeth usually starts close to the succedaneous tooth. The resorptive process is not continuous, but rather alternates between periods of root

resorption and repair much of the time.<sup>4,5</sup> Consequently, dimensional and morphologic characteristics of the tooth should be evaluated by the operator prior to the insertion of files into the root canals. Such information can only be derived from preoperative radiographic images.

Currently, conventional intraoral radiographs are commonly used to determine the working length in endodontic therapy. New imaging systems have been developed, however, and the direct digital radiography systems are being advocated as an alternative method.<sup>5</sup> Direct digital radiography systems are based on digital image capture by using a charge-coupled device. The advantages of these systems include: (1) reduction in radiation dosage; (2) speed of image acquisition; and (3) the possibility of editing images and details with similar quality to that afforded by conventional radiology.<sup>6-9</sup>

Most studies evaluating the onscreen measurement function of digital radiographs for endodontic length determination are in vitro investigations involving permanent teeth.<sup>10-16</sup> Authors who compared different radiographic techniques advocate that the reliability of digital radiography is equal or superior to that of the conventional radiography.<sup>17,18</sup> Nevertheless, the findings of a previous study<sup>15</sup> showed significant difference between the onscreen mea-

<sup>1</sup>Drs. Santos-Pinto, <sup>2</sup>Cordeiro and <sup>3</sup>Zuanon are associate professors, all in the Department of Pediatric Dentistry, School of Dentistry of Araraquara, São Paulo State University (UNESP), São Paulo, Brazil; <sup>4</sup>Dr. Basso is professor, Department of Pediatric Dentistry, School of Dentistry of Cascavel, West Paraná University (UNIOEST), Paraná, Brazil; and <sup>5</sup>Dr. Gonçalves is professor, Department of Pediatric Dentistry, School of Dentistry of Franca, University of Franca (UNIFRAN), Franca, São Paulo, Brazil.

Correspond with Dr. Santos-Pinto at [ls Pinto@foar.unesp.br](mailto:ls Pinto@foar.unesp.br)

surement tool of a digital radiography system and the actual canal length.

The purpose of this *in vivo* study was to compare primary incisor lengths, determined by onscreen measurements on direct digital radiographs (straight-line and grid superimposition), to the measurements of the extracted teeth (actual tooth length).

## Methods

After approval of the research protocol by the Ethics in Human Research Committee of Araraquara School of Dentistry, children from Pediatric Dentistry clinic with anterior teeth with extensive carious lesions and diagnosis of irreversible pulpitis based on symptomatology and clinical findings were invited to participate in this study. Informed consent was obtained from all parents/legal guardians. One preoperative periapical digital radiograph was made of each selected tooth to confirm the need of extraction. Only one tooth per child was selected to allow its accurate positioning in the center of the sensor.

Direct digital images were obtained from 22 3- to 5-year-old patients using a Schick CDR no. 2 sensor (Computed Dental Radiography system, v. 2.0, Schick Technologies Co, Long Island City, NY) and a Gnatus XR 6010 X ray unit (Gnatus, Ribeirão Preto, São Paulo, Brazil) operating at 60 kVp and 7mA. Optimal exposure time (0.3 seconds) was established in previous evaluations in which radiographs were made from human cadaver maxillas with exposure settings ranging from 0.1 to 0.5 seconds. Two experienced radiologists examined the images and chose those with the most appropriate radiographic density for tooth length determination under clinical conditions.

In all patients, direct digital imaging was undertaken by a single investigator. Exposures were made using a sensor holder using a paralleling technique with a focus-receptor distance of 30 cm. The digital images were saved in TIFF format. After completion of the imaging phase, the teeth were extracted and stored in 10% formalin solution. The receptacles were identified with codes related to: (1) patient name; (2) age; and (3) tooth number.

Two examiners—1 pediatric dentist and 1 radiologist who were familiar with the digital radiographic technique—participated in a training session to become acquainted with the nature of the study and to calibrate distance-measuring methods. They examined the onscreen images independently in a random order on a 17-inch computer monitor with screen resolution set at 1024 x 768 pixels and 100%

zoom magnification under subdued ambient light. The radiographic tooth length was estimated by 2 methods:

1. a 2-click measurement using the program's straight-line measurement feature, which determined the distance between one click at the incisal reference point and a second click at the root apex (Figure 1); and
2. superpositioning of a 1-mm grid over the image (Figure 2).

In the grid system, the tooth measurement was calculated by the sum of the grid cells. The examiners were instructed to attribute values (0.25, 0.5, and 0.75) when the root end was positioned between the grid lines. The actual tooth length was measured with a digital caliper. Each

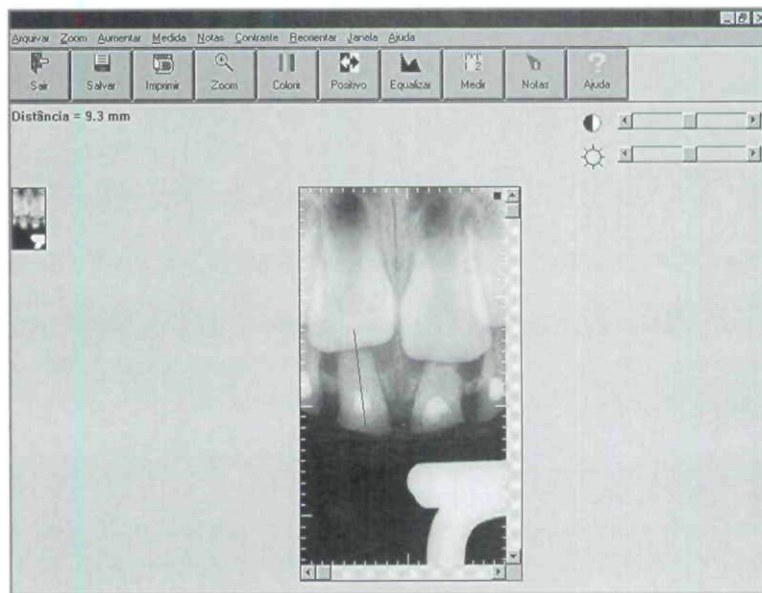


Figure 1. Schick Technologies straight-line measurement feature.

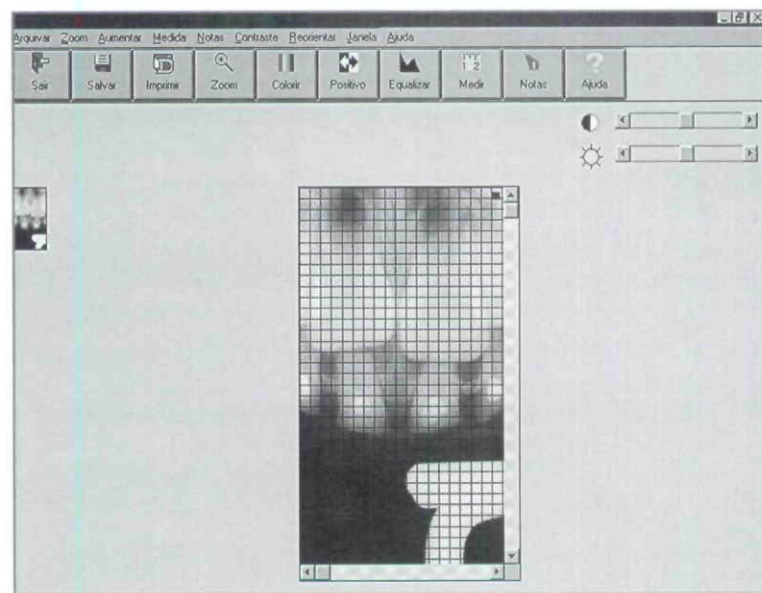


Figure 2. Schick Technologies 1-mm grid over the image.

examiner was blinded to the actual lengths of the teeth and to radiographic measurements obtained by the other examiner.

All measurements were performed twice by each examiner with a 2-week interval. Data were analyzed statistically by Pearson's correlation coefficient and paired *t* test. The null hypothesis that there is no difference among actual tooth length, straight-line measurement, and grid superimposition measurement was rejected at  $P < .05$ .

## Results

The correlation between the first and second measurements obtained with a 2-week interval was excellent for the pediatric dentist ( $r = 0.91$  for straight-line and grid measurements) and the radiologist ( $r = 0.91$  for straight-line measurement and  $r = 0.80$  for grid measurement). Interexaminer agreements were also excellent for both the straight-line ( $r = 0.88$ ) and for grid ( $r = 0.86$ ) measurements. As the interexaminer agreement was excellent, the means of the radiographic measurements were calculated and compared to the actual tooth lengths ( $r = 0.77$  for both measurement methods).

The means and standard deviations for the 2 onscreen measurement methods and the actual tooth lengths are given in Table 1.

Table 1. MEANS, STANDARD DEVIATIONS, AND MINIMUM AND MAXIMUM VALUES OF TOOTH LENGTHS DETERMINED BY DIRECT DIGITAL RADIOGRAPHS: LINEAR DISTANCE (DR-L), GRID (DR-G), AND ACTUAL TOOTH LENGTH (ATL)

Distance measurement	Means mm $\pm$ SD	Minimum (mm)	Maximum (mm)	Mean difference from ATL (mm)
DR-l	10.73 <sup>a</sup> $\pm$ 1.52	7.98	13.25	-0.19
DR-g	10.10 <sup>b</sup> $\pm$ 1.13	7.88	13.94	-0.82
ATL	10.91 <sup>a</sup> $\pm$ 1.39	8.00	13.40	

\* Different letters indicate statistically significant difference.

The correlation between the straight-line and grid measurements was  $r = 0.94$ . The difference between the actual tooth length and the estimated values showed that both radiographic methods of measurement underestimated the true tooth length. Underestimation of the true length of the teeth occurred in 45% of the straight-line measurements and in 73% of the grid measurements (Table 2).

Table 2. PERCENTAGE AND MEAN VALUES (MM) OF ERROR IN ESTIMATION OF THE RADIOGRAPHIC TOOTH LENGTH

Distance measurement	Overestimated (%)	Underestimated (%)	Minimum (mm)	Maximum (mm)	Means (mm)
DR-l	55	45	-1.28	2.05	0.19
DR-g	27	73	-0.34	2.39	0.82

\*DR-l=linear distance; DR-g=grid.

There were statistically significant differences ( $P = .007$ ) between the linear and grid measurement techniques, as well as between the actual tooth lengths and grid measurements. The difference between the straight-line measurements and the actual tooth length was not statistically significant, showing that the straight-line measurements were more accurate ( $P = .38$ ).

## Discussion

A critical factor in achieving success in endodontic therapy is the accurate determination of the tooth length before root canal preparation. Under clinical conditions, however, it is difficult to determine the extent to which the root canal system will be cleaned, especially in primary teeth with physiologic resorption.<sup>19</sup>

The usual method to determine the working length utilizes a combination of:

1. the knowledge of root canal anatomy;
2. a preoperative diagnostic radiograph to guide the introduction of the instrument into the root canal;
3. tactile sense; and
4. radiograph assessment with a file of adequate size placed in the root canal to estimate the length.

The intraexaminer agreement was excellent—similar to previous studies that evaluated the length of curved canals of extracted permanent teeth by digital radiography<sup>15</sup> and maxillary permanent root lengths in cadaver sections.<sup>9,21</sup> A high interexaminer agreement was observed in this study and has been also demonstrated in the identification of endodontic file tips in root canal length determination in vivo and in vitro using digital radiographic techniques.<sup>13,22</sup>

Despite the high correlation between the digital radiographic measurements and the actual tooth length, both radiographic methods underestimated the tooth length (Table 2). A possible explanation is that, in most radiographic images (81%), the primary tooth presented physiological resorption and an underlying permanent tooth germ that caused image superimposition. Consequently, the root apex was not clearly identified. Underestimation of both the permanent tooth canal and file length in digital radiographic examinations have been reported.<sup>23,24</sup> Likewise, overestimation of the true canal length in radiographic determination of curved canal length has also been demonstrated.<sup>15,25</sup>

In the present study, tooth length estimated by grid superimposition over digital radiographs showed the highest mean variation compared to the actual tooth length (Table 1). When the grid was superimposed over the tooth image, the black grid lines masked the root apex and apical contour detection could not be identified precisely. Comparing the accuracy of measurement algorithms

for digital radiographic systems, Scarfe et al<sup>26</sup> reported that grid-based techniques were inconsistent and unreliable in determining length. Ong and Pitt Ford,<sup>14</sup> however, found similar results for root length estimated from either radiographic films or grid superimposition on digital images.

Estimated tooth length in conventional radiography has been reported as similar ( $\pm 1$  mm range) to actual tooth length.<sup>27</sup> In the present study, a 1-mm difference between the actual tooth length and the radiographically estimated tooth length was considered a clinically acceptable discrepancy because this difference would not allow the file to extend beyond the actual tooth length and past the apical foramen. Therefore, for an acceptable difference range of 1 mm, 64% of the digital images measured by the straight-line or grid methods was similar to the actual tooth length.

Our findings suggested that the tooth length obtained with straight-line measurement on direct digital radiographs—using only a starting and end point to estimate the tooth length—was similar to the actual tooth length. An electronic ruler was the best measurement instrument in an endodontic length study developed by Vandrey et al,<sup>28</sup> and no significant difference was found between canal length estimates using multiple measurements points or a 2-click measurement technique.<sup>15,28</sup>

This study showed that an onscreen straight-line measurement was effective in the radiographic assessment of tooth length. Nevertheless, further research should be conducted, especially with primary molars, because only anterior teeth were used in the present study. It is likely that the discrepancy between the actual canal length and the estimated radiographic length will increase significantly as the degree of curvature increases.<sup>29</sup>

One should also consider that digital radiography has several potential benefits in pediatric endodontics. Computer-assisted radiographs allow the dentist to:

1. produce image enhancements such as:
  - a. contrast;
  - b. density; and
  - c. brightness;
2. decrease the radiation dose per image; and
3. reduce the time between exposure and interpretation.<sup>18</sup>

All of these factors are relevant in minimizing children's exposure to radiation and clinical chairtime.

## Conclusion

Based on the outcomes of this study, the following conclusions can be drawn:

1. Primary tooth length estimated from digital radiographs using the grid-based method differed from the actual tooth length.

2. The length of primary teeth estimated by using straight-line measurement on digital radiographs was similar to the actual tooth length and, hence, considered to be a more accurate onscreen measurement technique.

## Acknowledgements

This study was supported by a grant-in-aid from The São Paulo State Research Foundation (FAPESP), São Paulo, Brazil.

## References

1. Fuks AB, Eidelman E. Pulp therapy in primary dentition. *Curr Opin Dent* 1991;1:556-63.
2. Rodd HD, Waterhouse PJ, Fuks AB, Fayle, SA, Moffar, MA. Pulp therapy for primary molars. *Int J Paediatr Dent* 2006;16:15-23.
3. Troutman KC, Reisbick MH. Pulp therapy. In: Stewart RE, Barber TK, Troutman KC, Wei SHY, ed. *Pediatric Dentistry: Scientific Foundations and Clinical Practice*. Toronto, Ontario, Canada: Mosby Co; 1982:908-17.
4. Kronfeld L The resorption of the roots of deciduous teeth. *Dental Cosmos* 1932;74:103-20.
5. Ten Cate AR Physiologic tooth movement: Eruption and shedding. In: Ten Cate AR ed. *Oral Histology. Development, Structure and Function*. 5th ed. St Louis, Mo: Mosby Co; 1998:289-314.
6. Loushine RJ, Weller N, Kimbrough WF, Potter BJ. Measurement of endodontic file lengths: Calibrated versus uncalibrated digital images. *J Endod* 2001;27:779-81.
7. Horner K, Shearer AC, Walker A, Wilson NHF. RadioVisioGraphy: An initial evolution. *Br Dent J* 1990;168:244-8.
8. Lim KF, Loh EEM, Hong YH. Intraoral computed radiography: An in vitro evaluation. *J Dent* 1996;24:359-64.
9. Leddy BJ, Miles DA, Newton CW, Brown CE. Interpretation of endodontic file lengths using RadioVisioGraphy. *J Endod* 1994;20:542-5.
10. Borg E, Gröndahl HG. Endodontic measurement in digital radiographs acquired by a photostimulable, storage phosphor system. *Endod Dent Traumatol* 1996;12:20-4.
11. Shearer AC, Horner K, Wilson NHF. RadioVisioGraphy for imaging root canals: An in vitro comparison with conventional radiography. *Quintessence Int* 1990;21:789-94.
12. Shearer AC, Horner K, Wilson NHF. RadioVisioGraphy for length estimation in root canal treatment: An in vitro comparison with conventional radiography. *Int Endod J* 1991;24:233-9.
13. Ellingsen MA, Harrington GW, Hollender LG. RadioVisioGraphy versus conventional radiography for detection of small instruments in endodontic length determination part I: In vitro evaluation. *J Endod* 1995;21:326-31.

14. Ong EY, Pitt Ford TR. Comparison of RadioVisioGraphy with radiographic film in root length determination. *Int Endod J* 1995;28:25-9.
15. Burger CL, Mork TO, Hutter JW, Nicoll B. Direct digital radiography versus conventional radiography for estimation of canal length in curved canals. *J Endod* 1999;25:260-3.
16. Lozano A, Forner L, Llena C. In vitro comparison of root-canal measurements with conventional and digital radiology. *Int Endod J* 2002;35:542-50.
17. Martinez-Lozano MA, Forner-Navarro L, Sanchez-Cortez JL, Llena-Puy C. Methodological considerations in the determination of working length. *Int Endod J* 2001;34:371-6.
18. Subramaniam P, Konde S, Mandanna DK. An in vitro comparison of root canal measurement in primary teeth. *J Indian Soc Pedod Prev Dent* 2005;23:124-5.
19. Coll JA, Sadrian R. Predicting pulpectomy success and its relationship to exfoliation and succedaneous dentition. *Pediatr Dent* 1996;18:57-63.
20. Woolhiser GA, Brand JW, Hoen MM, Geist JR, Pikula AA, Pink FE. Accuracy of film-based, digital, and enhanced digital images for endodontic length determination. *Oral Surg Oral Med Oral Pathol Oral Radiol Endod* 2005;99:499-504.
21. Sheaffer JC, Eleazer PD, Schetz JP, Clark SJ, Farman AG. Endodontic measurement accuracy and perceived radiograph quality: Effects of film speed and density. *Oral Surg Oral Med Oral Pathol Oral Radiol Endod* 2003;4:441-8.
22. Ellingsen MA, Hollender LG, Harrington GW. RadioVisioGraphy versus conventional radiography for detection of small instruments in endodontic length determination part II: In vivo evaluation. *J Endod* 1995;10:516-20.
23. Rushton VE, Shearer AC, Horner K, Czajka J. An in vitro comparison of 10 radiographic methods for working length estimation. *Int Endod J* 1995;28:149-53.
24. Versteeg KH, Sanderink GCH, van Ginkel FC, van der Stelt PF. Estimating distances on direct digital images and conventional radiographs. *J Am Dent Assoc* 1997;128:439-43.
25. Montes A, Gencoglu N. Canal length evaluation of curved canals by direct digital or conventional radiography. *Oral Surg Oral Med Oral Pathol Oral Radiol Endod* 2002;93:88-91.
26. Scarfe WC, Norton S, Farman AG. Measurement accuracy: A comparison of two intraoral digital radiographic systems, RadioVisioGraphy-S and FlashDent, with analog film. *Dentomaxillofac Radiol* 1995;24:215-20.
27. Larheim TA, Eggen S. Determination of tooth length with a standardized paralleling technique and calibrated radiographic measuring film. *Oral Surg Oral Med Oral Pathol Oral Radiol Endod* 1997;48:374-8.
28. Vandre RH, Cruz CA, Pajak JC. Comparison of four direct digital radiographic systems with film for endodontic length determination [abstract]. *Dentomaxillofac Radiol* 1995;24:92.
29. Kim-Park MA, Baughan IW, Hartwell GR. Working length determination in palatal roots of maxillary molars. *J Endod* 2003;29:58-61.

Copyright of Pediatric Dentistry is the property of American Society of Dentistry for Children and its content may not be copied or emailed to multiple sites or posted to a listserv without the copyright holder's express written permission. However, users may print, download, or email articles for individual use.