

Clinical Article



Management of Avulsed Permanent Incisors: A Comprehensive Update

Judy D. McIntyre, DMD, MS¹ • Jessica Y. Lee, DDS, MPH, PhD² • Martin Trope, DMD³ • William F. Vann Jr., DMD, PhD⁴

Abstract: An avulsion injury is a challenge to manage, and there are many factors to consider to obtain the best prognosis in each scenario. In 2001, Lee and colleagues published decision analysis paradigms for the management of avulsed permanent teeth for the purpose of providing busy clinicians with user-friendly, reference-based flow-charts to facilitate the best possible outcomes for managing these teeth in children and adolescents. The purpose of this article was to update the 2001 flow-charts and decision analyses with: (1) current concepts; (2) recent literature-based findings; and (3) new philosophies. (*Pediatr Dent* 2007;29:56-63)

KEYWORDS: DENTAL TRAUMA, AVULSION, REPLANTATION

In 2001, Lee and colleagues¹ published decision analysis paradigms for the management of avulsed permanent teeth to provide busy clinicians with user-friendly, reference-based flow-charts to facilitate the best possible outcomes for managing these teeth in children and adolescents. The goal of this paper was to update these 2001 flow-charts and decision analyses with: (1) current concepts; (2) recent literature-based findings; and (3) new philosophies.

Avulsions occur most commonly in the permanent dentition of 8- to 12-year-old children ages at a time when there is loosely structured periodontal ligament surrounding erupting teeth that often exhibit short, incompletely formed roots. The reported incidence of tooth avulsions ranges from 1% to 16% of all traumatic injuries of the permanent dentition. The maxillary central incisor is the most commonly avulsed tooth.² Treatment of avulsions is directed at avoiding or minimizing the effects of the 2 primary complications: (1) pulpal infection; and (2) attachment damage.

Minimizing attachment damage

Attachment damage secondary to avulsion cannot be avoided; nevertheless, considerable additional damage can occur to the periodontal membrane during the time the tooth is out of the oral cavity. Treatment is directed at minimizing this

damage so that the fewest number of complications result. When severe additional damage has occurred and ankylosis (osseous replacement resorption) is considered certain, steps can be taken to slow this irreversible resorptive process to maintain the tooth in the oral cavity for as long as possible.

Reducing the chances of pulpal infection

When a tooth is avulsed, the apical blood supply is severed and the periodontal ligament (PDL) is severely damaged. While pulp necrosis is certain, under specific circumstances it is possible for the pulp space of the replanted tooth to revascularize. Hence, when the avulsed tooth is immature with an open apex, efforts should be made to promote revascularization. When an apex is closed or nearly closed (<1 mm), revascularization is highly unlikely. Therefore, treatment for the closed apex tooth should be aimed at prevention or elimination of potential bacterial toxins from the root canal space by endodontic therapy.

Most US dentists follow the guidelines promulgated by the American Association of Endodontists.³ The International Association of Dental Traumatology (IADT) guidelines are similar.⁴ The authors' decision trees build on the original ones presented by Lee and colleagues¹ while relying upon the AAE and IADT guidelines as points of departure and incorporating newer paradigms and changing concepts.

Clinical management: First steps first

Immediate replantation: Best prognosis. If the avulsed tooth can be located, it is best to immediately and atraumatically replant it at the accident site. The authors recommend a quick and gentle rinse under tap water or sterile saline if available. Immediate replantation as soon as possible pro-

¹Dr. McIntyre is an endodontist in private practice in Burlington, NC and is a former resident in endodontics. ²Dr. Lee is assistant professor, Departments of Pediatric Dentistry and Health Policy; ³Dr. Trope was the former Chair, Department of Endodontics, and ⁴Dr. Vann Jr. is Distinguished Professor, Department of Pediatric Dentistry, all at the University of North Carolina at Chapel Hill, Chapel Hill, NC.
Correspond with Dr. Lee at jessica_lee@dentistry.unc.edu

vides the best prognosis to minimize attachment damage and the highest likelihood for revascularization for teeth with open apices. For closed apex teeth, immediate replantation will greatly reduce attachment damage, consequently abating or delaying osseous replacement resorption (ORR) or inflammatory root resorption (IRR). Endodontic therapy for closed apex teeth, however, will still be required. Nevertheless, it is important to note that resorption is the primary reason for loss of replanted teeth. As many as 68% of teeth may develop resorptions.⁹

Emergency dental visit: PDL management. At the emergency visit, dentists must concentrate on minimizing attachment damage and the resultant inflammation from the PDL. The second visit will address the pulp space with endodontic treatment. Critical factors to consider are:

1. drytime (<or> 60 minutes); 20 minutes or less is ideal, but partial success in the growing patient may still be enough to save alveolar bone so that, until the tooth is lost, the additional time the tooth remains in the mouth beyond the traumatic injury is time that should be viewed as successful; and
2. closed or open apex—a tooth with an open apex (≥ 1 mm) may revascularize, while teeth with closed apices will need endodontic treatment to prevent or treat endodontic infection, status post avulsion injury, and, and, hence, the severing of the vasculature to the tooth's pulp.

When faced with an avulsion injury, the dentist should obtain a thorough history, including the precise time interval between injury and replantation as well as the conditions under which the tooth has been stored and transported. When the decision has been made to replant, the avulsed tooth should be examined for obvious contamination. If visibly contaminated, the root surface should be rinsed gently with either tap water or a sterile saline¹⁰ until visible contaminants have been removed,¹¹ followed by immediate replantation. Great care must be taken to ensure that the plug to sink is in place so that the tooth is not lost down the drain. Root surface debris should not be scraped off because this may destroy viable PDL cells. It is preferable to replant a tooth with minor debris on the root surface than to risk removal or injury to PDL cells.⁹ No effort should be made to sterilize the tooth surface because this may damage periodontal tissue and cementum.

Regarding PDL management in cases of extended dry times (ie, >60 minutes), recent animal studies have reported that roots treated with the intracanal medicament Ledermix (Lederle Pharmaceuticals, Wolfratschausen, Germany) have significantly more favorable healing and less resorption than in those treated with the intracanal medicament Ca(OH)₂.¹² Ledermix paste, however, is not available currently in the

United States. Because time dry time is greater than 60 minutes and time is not as big a factor, this can be done in hand or inside the mouth after replantation. Furthermore, it has been demonstrated that when dogs' teeth with cemental defects (duplicated to mimic trauma injuries) are extracted, kept dry for 40 to 60 minutes, and soaked in alendronate or Hank's Balanced Salt Solution (HBSS), cemental healing occurs in both media.¹³ Additionally, the alendronate-soaked roots exhibit more healing and less root resorption than those soaked in HBSS.¹³ Alendronate is in a class of medications used to strengthen bone. Bone is in a constant state of remodeling, whereby old bone is removed by cells called osteoclasts and new bone is laid down by cells called osteoblasts. Alendronate inhibits bone removal by the osteoclasts. As long as the extracted tooth is stored in a physiologic media, however, storage time has not been found to be a significant factor. The apparent critical limit for dry time has been found to be no more than 20 minutes.⁵

Socket treatment. The alveolar socket should be examined and rinsed with a flow of saline to remove the contaminated coagulum if needed. If there is evidence of socket collapse or fracture, the socket should be recontoured as gently as possible using a blunt instrument such as a mirror handle to remodel the bony socket.

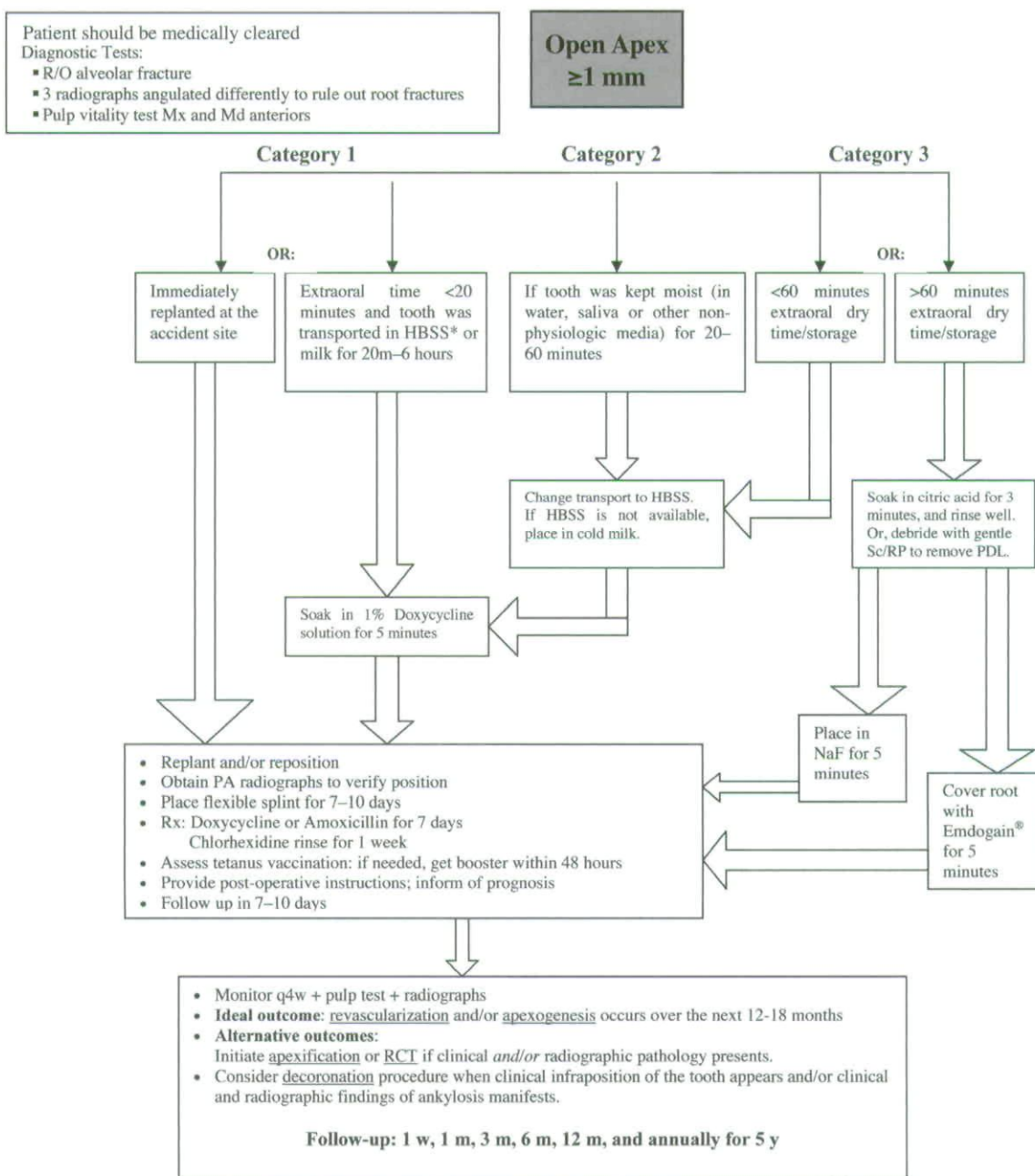
Splinting the replanted tooth. Replanted teeth should be splinted for a minimal amount of 7 to 10 days^{6,14,15} with a flexible wire (eg, a nonrigid titanium splint⁴ or orthodontic wire with or without orthodontic brackets¹⁵) or bonded into place with flowable resin¹⁶⁻²¹ or fishing line (monofilament). The ideal splint allows for physiologic movement and is easy for the patient to clean with a toothbrush.

Success of replanted teeth. In the past, replantation of teeth was considered a temporary measure because these teeth often would be lost secondarily to root resorption. Many cases have been reported, however, wherein teeth have survived successfully for 20 to 40 years with a normal periodontium. These reports demonstrate that, under ideal conditions, replanted teeth can maintain their integrity and function. With respect to pulpal healing, the revascularization success rate of replanted teeth has been reported to range from 8% in mature teeth to 25% to 34% in immature teeth.^{8,20,21} Relative to periodontal ligament healing, success has been reported to range from 24% to 57%.^{4,21} Recent evidence suggests that success of replantation is dependent upon many factors, some of which the clinician can manipulate in a manner that favors more successful outcomes. The authors' decision trees in Figures 1 and 2 offer the clinician the most up-to-date information in an easy-to-use flow-chart format.

It is important to understand that avulsions most commonly affect growing children. The definition of success of an avulsed tooth should also include retention of the tooth until craniofacial growth and development are completed, usually about 18 years of age. After growth is completed, the clinician can consider other treatment options, such as a dental implant or a bridge. Therefore, an avulsed tooth that is

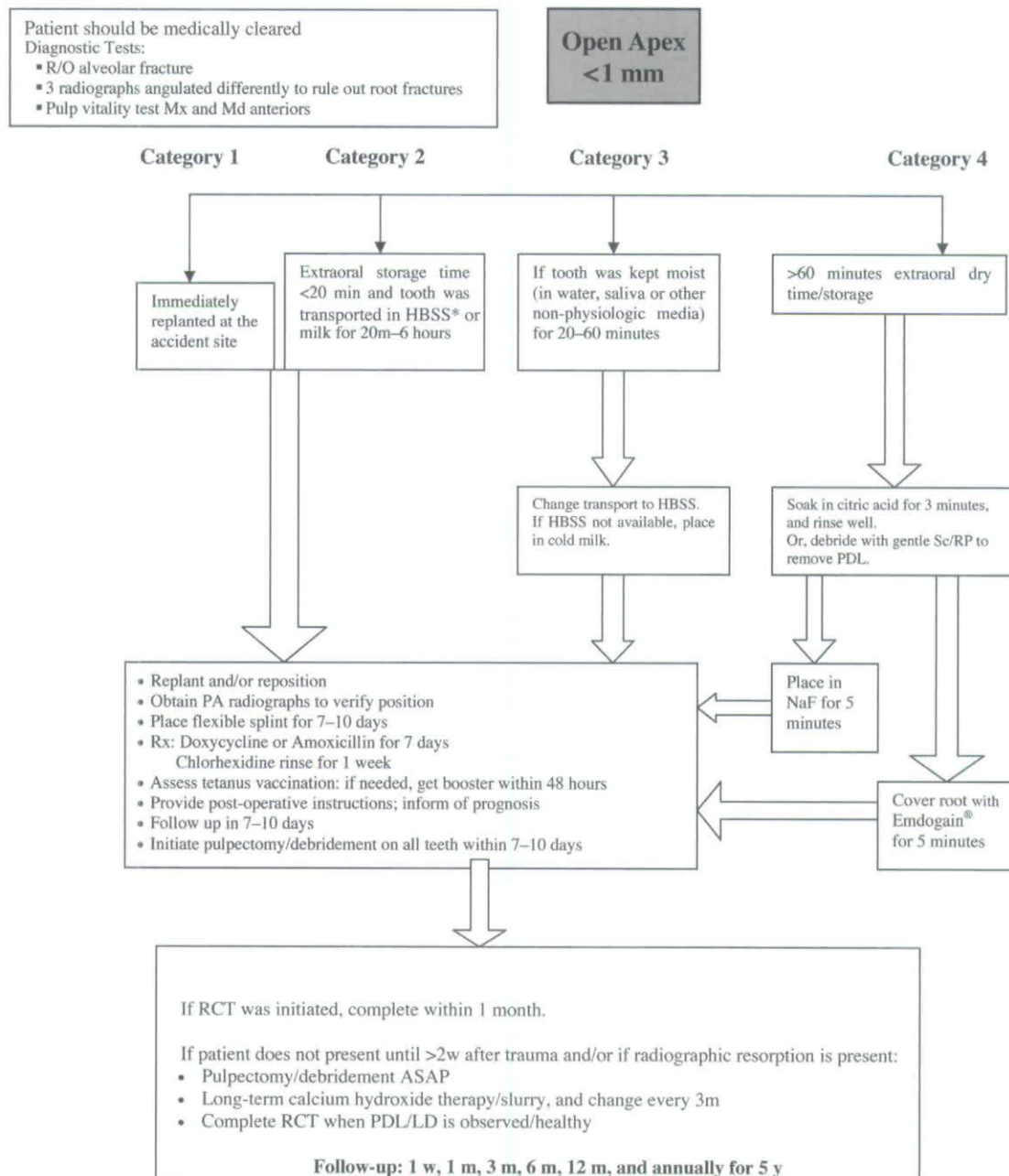
maintained until growth is completed should be considered a successful outcome because tooth loss before this time often includes loss of the alveolar bone as well as further resorption of the bone in the site. This latter circumstance greatly compromises options for the missing tooth or teeth and may involve extensive and costly procedures such as bone augmentation and grafting.

Fig 1: Clinical Management of Avulsed Permanent Incisors with an Open Apex



* Hank's Balanced Salt Solution

Fig 2: Clinical Management of Avulsed Permanent Incisors with a Closed Apex



* Hank's Balanced Salt Solution

New treatment regimens

Enhancing revascularization: The use of topical antibiotics for immature teeth. The authors' decision analysis and management protocol differ for immature vs mature teeth. Because patient age is a poor predictor of tooth maturation,

the clinician should rely upon apical closure as an indication of tooth maturation. An immature or open apex tooth has the potential to establish revascularization when there is a minimum of a 1 mm apical opening. Complete pulpal revascularization has been shown to occur at a rate of 18% among im-

mature teeth.²⁴ Furthermore, when extraoral time is limited to no more than 5 minutes, revascularization among teeth with open apices in dogs has been found to be as high as 91% with topical minocycline and 73% with topical doxycycline.²⁵ Antibiotic treatment appears to reduce contamination of the root surface²⁶ and/or pulp space,¹⁵ thereby creating a biological environment that aids revascularization. On the other hand, a mature tooth or closed apex tooth (apex opening <1 mm) has little or no chance of revascularization.

Cvek and colleagues²⁶ demonstrated that immature teeth soaked in doxycycline solution have a greater rate of pulpal revascularization, a finding corroborated by Yanpiset and Trope in animal studies.²⁷ Based on the available evidence, the authors recommend that immature teeth be soaked in a 1% doxycycline solution for five minutes before replantation. This solution can be prepared with 1 mg doxycycline/20 mL sterile liquid (distilled water or HBSS).

Preserving the PDL

Immediate replantation is the best option for the preservation of the PDL attachment apparatus because this prevents desiccation/death of the PDL cells. The sooner the tooth is replanted, the better. The majority of teeth that are immediately replanted should have their PDL restored within a few weeks.²⁸ The time limit for immediate replantation varies, ranging from 5 to 30 minutes^{6,11,28,29}; the authors' recommended time limit is 20 minutes or less. Because immediate replantation is often not undertaken, however, tooth transport is common. There is good evidence that HBSS is the most suitable transport medium.³⁰ HBSS is a pH-preserving fluid, a trauma-reducing suspension apparatus, and an organ preserving medium. Several studies have reported pH-balanced cell-reconstituting media to be effective at reducing replacement root resorption by maintenance of a normal PDL.³¹⁻³² Save-A-Tooth (Phoenix-Lazerus, Inc, Pottstown, Pa) is an HBSS-type product marketed specifically for the preservation and transportation of avulsed teeth.

The authors recommend that HBSS be readily available in: (1) hospital emergency rooms; (2) athletic coach trainer kits; (3) school nurses' stations; and (4) private dental offices that cater to children and adolescents. If an avulsed tooth is transported in a nonphysiologic medium, it should be placed in HBSS immediately upon arrival of the child in the emergency room or dental office so that the tooth can be soaking while the child is receiving medical attention and/or clearance or during the clinical examination and radiographs.

If HBSS is unavailable as a transport medium, milk has been shown to be the next best alternative. Because of milk's osmolality and pH, it is a reasonable alternative to HBSS. Studies confirm that milk will preserve PDL cells for up to 8 hours.³³⁻³⁴ It has also been proven that cold storage is pre-

ferred.⁵⁹ In contrast, tap water is a poor alternative because it causes PDL cell death within a few minutes due to its hypo-osmolality vs that of the PDL cells. In short, water causes PDL cell lysis and death.

The condemned PDL: Transitional therapy. Revascularization is not essential for the long-term success of the replanted avulsed tooth because root canal treatment can offer a predictable, long-term, successful outcome. Maintenance of the PDL, however, is essential for the long-term success. Without a healthy PDL, the tooth will ultimately be lost secondarily to IRR or ORR. The authors' decision trees focus on extraoral time and storage conditions, both of which have been shown to be critical for replantation success.

When a tooth has been out of the oral cavity and in a dry environment for greater than 60 minutes, the PDL has no chance of survival.³⁵ If such a tooth is replanted, it is likely to undergo ORR.⁴ Over time, the tooth will become ankylosed and ultimately be lost. For this reason, the AAE does not recommend replantation, but pediatric dentists need to consider the growth and development of the child patient. Consequently, the goal for a tooth that has been avulsed for greater than 60 minutes with dry storage is to delay the osseous replacement and, hence, ankylosis process as long as possible. To slow this process, the remaining PDL should be removed to prevent it from becoming a stimulus for inflammation that accelerates infection-related resorption.³⁶ The remaining PDL can be removed by gentle scaling and root planing and/or by soaking the tooth in citric acid,³⁷⁻³⁹ followed by fluoride treatment. A 3-minute soak in citric acid is an excellent noninvasive approach for PDL removal. After PDL removal, the tooth should be soaked in fluoride (acidulated phosphate fluoride or sodium fluoride) for a minimum of 5 and up to 20 minutes.³⁸⁻⁴⁰ The rationale for this fluoride soak is based on evidence that this procedure will delay but not prevent ankylosis.³⁶ Despite this recommendation, teeth that have been out of the oral cavity for greater than 60 minutes with dry storage have a poor prognosis and will not survive long-term. When teeth are soaked in fluoride before replantation, however, it has been shown to significantly reduce the rate of resorption after a follow-up of 5 years.⁴¹ When a decision has been made that the replanted tooth will undergo replacement root resorption, the tooth should be decoronated or the clinician should proceed with a permanent restoration, such as a fixed partial bridge or an implant. These 5 transitional years may have provided sufficient time needed for a growing child to have achieved further valuable, 3-dimensional alveolar growth, if not maintenance of the child's bone.

Recent literature has shown that soaking avulsed teeth in topical tetracycline⁶ or topical doxycycline not only significantly increases the rate of complete revascularization, but

also decreases the frequencies of both ankylosis/osseous replacement and IRR.²⁶ Furthermore, topical minocycline has been found to:

1. increase complete (PDL) healing without either replacement or inflammatory pathologic root resorption⁴²; and
2. aid in revascularization.²⁵

Future studies should help illuminate the reported benefits of Emdogain, an enamel matrix derivative (Biora AB, Malmo, Sweden) extracted from developing embryonal enamel of porcine origin. Emdogain has been used to coat the entire root surface of the avulsed tooth prior to replantation. Emdogain contains proteins of the amelogenin family⁴³ and is presently thought to aid in the migration, attachment, proliferative capacity, and biosynthetic activity of PDL cells.⁴⁴ Emdogain has also been shown to enhance PDL cell proliferation and protein production, and it may act as a matrix for cells responsible for regenerating PDL at a wound site such as a replanted avulsed tooth.⁴³⁻⁴⁵

Several case reports⁴⁶⁻⁴⁸ and other articles^{44-45,49} have shown promising results in terms of decreased replacement root resorption and decreased IRR when Emdogain was used topically prior to replantation of an avulsed tooth. Longitudinal outcome studies, however, are lacking. Future studies should provide much needed data in terms of the true value of Emdogain's use for traumatized, replanted teeth, especially when considering its considerable expense compared to other less expensive/more affordable alternatives. It is also worth noting that recent studies have found promising results using more novel, emerging alternatives, such as: (1) doxycycline²⁵; (2) minocycline^{25,50}; (3) alendronate¹³; or (4) intracanal medicaments such as Ledermix.¹²

The condemned PDL: Long-term therapy. Although ankylosis (osseous replacement/root resorption) is an unfortunate outcome for approximately 48% of replanted avulsed teeth,¹⁵ an ankylosed tooth is often a desirable outcome as a transitional condition for a growing child or adolescent.⁵¹ Extraction of an ankylosed tooth may result in: (1) loss of attached bone; (2) loss of the cortical maxillary plate; and (3) a bony deformation. Moreover, bony resorption following extraction complicates the esthetics and function of later restorations such as a fixed partial denture or dental implant.

When an adolescent's maxillary growth is completed, an excellent treatment option for an ankylosed tooth is decoronation, as described by Malmgren and colleagues.^{52,53} For this procedure, a full thickness mucoperiosteal flap is raised and the clinical crown and coronal root are removed with a bur below the level of the cemento-enamel junction. The root filling material is removed and the intracanal space is allowed to fill in with blood. The flap is then sutured over the site of the

newly created "socket." An excellent transitional esthetic option for the edentulous site is the use of the crown of the extracted tooth as a splinted pontic to the adjacent teeth. Other transitional esthetic alternatives might include the splinting of a denture tooth to the adjacent teeth or reliance upon a "flipper" appliance.

The decoronation procedure described by Malmgren and colleagues^{52,53} has been shown to preserve the volume-buccolingual as well as the vertical height-of the alveolar process for subsequent restorations when maxillary growth is completed. Extraction, meanwhile, contributes to further loss of this essential bone.

Finally, inflammatory root resorption (IRR) is a complication that occurs among 26% of the replanted teeth.¹⁵ This process has no treatment protocol at present, and very little can be done for teeth that exhibit even very early signs of IRR. Eventually, these teeth will not survive.^{11,15,54-56}

The use of adjunctive systemic antibiotics. The use of systemic antibiotics given at the time of replantation may be effective in preventing bacterial infection of necrotic pulp, a consequence that can precipitate IRR. For this reason, the use of systemic antibiotics following tooth avulsion/replantation is recommended by the AAE and IADT. Tetracycline has been shown to be antiresorptive, antiosteoclastic, anti-inflammatory, and antibacterial^{24,26,27,42} and remains in the sulcular fluid in high concentrations. Moreover, when placed topically and/or taken systemically after an avulsion injury, tetracycline has been shown to prevent or inhibit external root resorption.^{26,57,58} Tetracycline, however, can stain teeth in growing children. Nevertheless, it is the antibiotic of choice after replantation of avulsed teeth.

For patients susceptible to tetracycline staining, practitioners can prescribe 500 mg of penicillin VK qid or a child-equivalent dose (50 mg/kg divided into 4 equal doses, not to exceed an adult dose) for 7 days. Practitioners also can prescribe 100 mg of doxycycline or a child-equivalent (10-20 mg/lb divided into 4 equal doses, not to exceed 400 mg) for 7 to 10 days.⁶

Conclusion

The updated decision trees (Figures 1 and 2) offer the busy clinician contemporary, reference-based, easy-to-use flow charts for managing avulsed permanent incisors in children and adolescents.

References

1. Lee JY, Vann WF, Jr, Sigurdsson A. Management of avulsed permanent incisors: a decision analysis based on changing concepts. *Pediatr Dent* 2001;23:357-60.
2. Andreasen JO, Andreasen FM. Textbook and Color Atlas of Traumatic Injuries to the Teeth. 3rd ed. St. Louis, Mo: Munksgaard, Mosby Year-Book distributor; 1994.

3. American Association of Endodontics. Available at: "http://www.aae.org/NR/rdonlyres/9232084C-DD96-4459-98B6-33A17A3FEA10/0/2004TraumaGuidelines.pdf". Accessed August 13, 2006.
4. American Association of Endodontics. Available at: "http://www.iadt-dentaltrauma.org/site_2005/for_patients_permanent.htm#2". Accessed August 13, 2006.
5. Donaldson M, Kinirons MJ. Factors affecting the time of onset of resorption in avulsed and replanted incisor teeth in children. *Dent Traumatol* 2001;17:205-9.
6. Chappuis V, von Arx T. Replantation of 45 avulsed permanent teeth: A 1-year follow-up study. *Dent Traumatol* 2005;21:289-96.
7. Pohl Y, Wahl G, Filippi A, Kirschner H. Results after replantation of avulsed permanent teeth. III. Tooth loss and survival analysis. *Dent Traumatol* 2005;21:102-10.
8. Pohl Y, Filippi A, Kirschner H. Results after replantation of avulsed permanent teeth. II. Periodontal healing and the role of physiologic storage and antiresorptive-regenerative therapy. *Dent Traumatol* 2005;21:93-101.
9. Pohl Y, Filippi A, Kirschner H. Results after replantation of avulsed permanent teeth. I. Endodontic considerations. *Dent Traumatol* 2005;21:80-92.
10. Andreasen JO, Borum MK, Jacobsen HL, Andreasen FM. Replantation of 400 avulsed permanent incisors. 2. Factors related to pulpal healing. *Endod Dent Traumatol* 1995;11:59-68.
11. Kinirons MJ, Gregg TA, Welbury RR, Cole BO. Variations in the presenting and treatment features in reimplanted permanent incisors in children and their effect on the prevalence of root resorption. *Br Dent J* 2000;189:263-6.
12. Bryson EC, Levin L, Banchs F, Abbott PV, Trope M. Effect of immediate intracanal placement of Ledermix Paste on healing of replanted dog teeth after extended dry times. *Dent Traumatol* 2002;18:316-21.
13. Levin L, Bryson EC, Caplan D, Trope M. Effect of topical alendronate on root resorption of dried replanted dog teeth. *Dent Traumatol* 2001;17:120-6.
14. Nasjleti CE, Castelli WA, Caffesse RG. The effects of different splinting times on replantation of teeth in monkeys. *Oral Surg Oral Med Oral Pathol* 1982;53:557-66.
15. Kinirons MJ, Boyd DH, Gregg TA. Inflammatory and replacement resorption in reimplanted permanent incisor teeth: A study of the characteristics of 84 teeth. *Endod Dent Traumatol* 1999;15:269-72.
16. Dawoodbhoy I, Valiathan A, Lalani ZS, Cariappa KM. Splinting of avulsed central incisors with orthodontic wires: A case report. *Endod Dent Traumatol* 1994;10:149-52.
17. Croll TP, Helpin ML. Use of self-etching adhesive system and compomer for splinting traumatized incisors. *Pediatr Dent* 2002;24:53-6.
18. Croll TP. Bonded composite resin/ligature wire splint for stabilization of traumatically displaced teeth. *Quintessence Int* 1991;22:17-21.
19. Andreasen JO, Andreasen FM, Mejare I, Cvek M. Healing of 400 intra-alveolar root fractures. 2. Effect of treatment factors such as treatment delay, repositioning, splinting type and period and antibiotics. *Dent Traumatol* 2004;20:203-11.
20. von Arx T, Filippi A, Buser D. Splinting of traumatized teeth with a new device: TTS (titanium trauma splint). *Dent Traumatol* 2001;17:180-4.
21. Oikarinen K, Andreasen JO, Andreasen FM. Rigidity of various fixation methods used as dental splints. *Endod Dent Traumatol* 1992;8:113-9.
22. Andreasen JO, Borum MK, Andreasen FM. Replantation of 400 avulsed permanent incisors. 3. Factors related to root growth. *Endod Dent Traumatol* 1995;11:69-75.
23. Andreasen JO, Borum MK, Jacobsen HL, Andreasen FM. Replantation of 400 avulsed permanent incisors. 1. Diagnosis of healing complications. *Endod Dent Traumatol* 1995;11:51-8.
24. Cvek M, Cleaton-Jones P, Austin J, Lownie J, Kling M, Fatti P. Pulp revascularization in reimplanted immature monkey incisors—predictability and the effect of antibiotic systemic prophylaxis. *Endod Dent Traumatol* 1990;6:157-69.
25. Ritter AL, Ritter AV, Murrah V, Sigurdsson A, Trope M. Pulp revascularization of replanted immature dog teeth after treatment with minocycline and doxycycline assessed by laser Doppler flowmetry, radiography, and histology. *Dent Traumatol* 2004;20:75-84.
26. Cvek M, Cleaton-Jones P, Austin J, Lownie J, Kling M, Fatti P. Effect of topical application of doxycycline on pulp revascularization and periodontal healing in reimplanted monkey incisors. *Endod Dent Traumatol* 1990;6:170-6.
27. Yanpiset K, Trope M. Pulp revascularization of replanted immature dog teeth after different treatment methods. *Endod Dent Traumatol* 2000;16:211-7.
28. American Association of Endodontists. Endodontics: Colleagues for Excellence. Chicago, Ill: American Association of Endodontists; 2006.
29. Pettiette M, Hupp J, Mesaros S, Trope M. Periodontal healing of extracted dogs' teeth air-dried for extended periods and soaked in various media. *Endod Dent Traumatol* 1997;13:113-8.
30. Ashkenazi M, Marouni M, Sarnat H. In vitro viability, mitogenicity, and clonogenic capacity of periodontal ligament cells after storage in four media at room temperature. *Endod Dent Traumatol* 2000;16:63-70.

31. Cvek M, Granath LE, Hollender L. Treatment of nonvital permanent incisors with calcium hydroxide. 3. Variation of occurrence of ankylosis of reimplanted teeth with duration of extra-alveolar period and storage environment. *Odontol Revy* 1974;25:43-56.
32. Matsson L, Andreasen JO, Cvek M, Granath LE. Ankylosis of experimentally reimplanted teeth related to extra alveolar period and storage environment. *Pediatr Dent* 1982;4:327-29.
33. Marino TG, West LA, Liewehr FR, Mailhot JM, Buxton TB, Runner RR, et al. Determination of periodontal ligament cell viability in long shelf-life milk. *J Endod* 2000;26:699-702.
34. Blomlof L, Lindskog S, Andersson L, Hedstrom KG, Hammarstrom L. Storage of experimentally avulsed teeth in milk prior to replantation. *J Dent Res* 1983;62:912-6.
35. Blomlof L, Andersson L, Lindskog S, Hedstrom KG, Hammarstrom L. Periodontal healing of replanted monkey teeth prevented from drying. *Acta Odontol Scand* 1983;41:117-23.
36. Selvig KA, Zander HA. Chemical analysis and microradiography of cementum and dentin from periodontally diseased human teeth. *J Periodontol* 1962;33:303-10.
37. Nyman S, Houston F, Sarhed G, Lindhe J, Karring T. Healing following reimplantation of teeth subjected to root planing and citric acid treatment. *J Clin Periodontol* 1985;12:294-305.
38. Trope M. Clinical management of the avulsed tooth. *Dent Clin North Am* 1995;39:93-112.
39. American Association of Endodontists. Recommended Guidelines of the American Association of Endodontists for the Treatment of Traumatic Dental Injuries. Chicago, Ill: American Association of Endodontists; 2004.
40. Trope M. Treatment of the avulsed tooth. *Pediatr Dent* 2000;22:145-7.
41. Coccia CT. A clinical investigation of root resorption rates in reimplanted young permanent incisors: A five-year study. *J Endod* 1980;6:413-20.
42. Ma KM, Sae-Lim V. The effect of topical minocycline on replacement resorption of replanted monkeys' teeth. *Dent Traumatol* 2003;19:96-102.
43. Gestrelus S, Andersson C, Johansson AC, Persson E, Brodin A, Rydhag L, et al. Formulation of enamel matrix derivative for surface coating. Kinetics and cell colonization. *J Clin Periodontol* 1997;24:678-84.
44. Hammarstrom L. Enamel matrix, cementum development and regeneration. *J Clin Periodontol* 1997;24:658-68.
45. Filippi A, Pohl Y, von Arx T. Treatment of replacement resorption with Emdogain—a prospective clinical study. *Dent Traumatol* 2002;18:138-43.
46. Kenny DJ, Barrett EJ, Johnston DH, Sigal MJ, Tenenbaum HC. Clinical management of avulsed permanent incisors using Emdogain: Initial report of an investigation. *J Can Dent Assoc* 2000;66:21.
47. Andersson L, Bodin I, Sorensen S. Progression of root resorption following replantation of human teeth after extended extraoral storage. *Endod Dent Traumatol* 1989;5:38-47.
48. Barrett EJ, Kenny DJ, Tenenbaum HC, Sigal MJ, Johnston DH. Replantation of permanent incisors in children using Emdogain. *Dent Traumatol* 2005;21:269-75.
49. Iqbal MK, Bamaas N. Effect of enamel matrix derivative (Emdogain) upon periodontal healing after replantation of permanent incisors in beagle dogs. *Dent Traumatol* 2001;17:36-45.
50. Bryson EC, Levin L, Banchs F, Trope M. Effect of minocycline on healing of replanted dog teeth after extended dry times. *Dent Traumatol* 2003;19:90-5.
51. Andersson L, Malmgren B. The problem of dentoalveolar ankylosis and subsequent replacement resorption in the growing patient. *Aust Endod J* 1999;25:57-61.
52. Malmgren B, Cvek M, Lundberg M, Frykholm A. Surgical treatment of ankylosed and infrapositioned reimplanted incisors in adolescents. *Scand J Dent Res* 1984;92:391-9.
53. Malmgren B, Malmgren O. Rate of infraposition of reimplanted ankylosed incisors related to age and growth in children and adolescents. *Dent Traumatol* 2002;18:28-36.
54. Caliskan MK, Turkun M, Gokay N. Delayed replantation of avulsed mature teeth with calcium hydroxide treatment. *J Endod* 2000;26:472-6.
55. Heithersay GS. Replantation of avulsed teeth. A review. *Aust Dent J* 1975;20:63-72.
56. Andreasen JO, Borum MK, Jacobsen HL, Andreasen FM. Replantation of 400 avulsed permanent incisors. 4. Factors related to periodontal ligament healing. *Endod Dent Traumatol* 1995;11:76-89.
57. Sae-Lim V, Wang CY, Choi GW, Trope M. The effect of systemic tetracycline on resorption of dried replanted dogs' teeth. *Endod Dent Traumatol* 1998;14:127-32.
58. Sae-Lim V, Wang CY, Trope M. Effect of systemic tetracycline and amoxicillin on inflammatory root resorption of replanted dogs' teeth. *Endod Dent Traumatol* 1998;14:216-20.
59. Sigalas E, Regan JD, Kramer PR, Witherspoon DE, Opperman IA. Survival of human periodontal ligament cells in media proposed for transport of avulsed teeth. *Dent Traumatol* 2004;20:21-28.

Copyright of Pediatric Dentistry is the property of American Society of Dentistry for Children and its content may not be copied or emailed to multiple sites or posted to a listserv without the copyright holder's express written permission. However, users may print, download, or email articles for individual use.