

# The Applications of Diode and Er:YAG Lasers in Labial Frenectomy in Infant Patients

**Isa Gontijo, MS   Ricardo S. Navarro, PhD   Patrícia Haypek, MS, PhD  
Ana Lúcia Ciamponi, MS, PhD   Ana Estela Haddad, PhD**

## ABSTRACT

This paper describes a clinical case of labial frenectomy using different high power lasers: diode (810 nm) and Er:YAG (2,940 nm). Considerations are made about specific indications, surgery techniques, and advantages of labial frenectomy using these laser wavelengths. The diode laser has high absorbance by pigmented tissues with hemoglobin, melanin, and collagen chromophores. For this reason, this wavelength is well indicated for surgery in soft tissue (vaporization, incision, coagulation, hemostasis). It is not properly absorbed, however, and should never be used in contact with hard tissues (bone). The Er:YAG laser has high absorbance to water and mineral apatite, making this wavelength useful and safe for the ablation of hard tissues. In the labial frenectomy clinical procedure, a combined technique is suggested: using the diode laser in soft tissues and the Er:YAG laser in periosteal bone tissues and for removal of final collagen fibers. It is important for the professional to understand the physical characteristics of the different laser wavelengths and their interaction with biological tissues to assure that they are used in a safe way, and that the benefits of this technology can be provided to infant patients. (J Dent Child 2005;72:10-15)

**KEYWORDS:** LASER, FRENECTOMY, INFANT

The superior labial frenum, formed at the beginning of the third month of intrauterine life, consists of a triangular-shaped fold connecting the tubercle of the upper lip to the alveolar process, possibly extending to the palatal papillae in children. The loose connective tissue with elastic fibers covered by the stratified layered epithelium is the basic constituent of this frenum.<sup>1</sup> According to some authors, some muscular fibers—originating from the orbicularis muscle of the lip—can be present. There is a physiological tendency for apical retraction and atrophy of the frenum as the child grows and as the alveolar processes develop and the teeth erupt. Thus, after dental eruption, the upper labial frenum starts to be located several millimeters above the gingival margin. The

frenum's function is to limit the movement of an organ or part of it.<sup>2-5</sup> In the case of the superior labial frenum, its function is to limit the lip's exaggerated movements, which would permit excessive exposure of the gingival mucosa.

The labial frenum is considered to be hypertrophic when it remains inserted in the free gingival margin or on the palatine papillae, even after the alveolar growth which accompanies dental eruption. The diagnosis is made when, upon pulling the frenum, one can see ischemia of the palatine papillae.<sup>6,7</sup>

The hypertrophic frenum can be accompanied by the presence of a median interincisal diastema. It is necessary to differentiate physiological interincisal diastema ("ugly duckling stage") from pathological interincisal diastema. The etiology of pathological interincisal diastema can be determined by other factors other than hypertrophic frenum. These include the presence of supernumerary teeth, odontomas, lack of coalescence of the median raphe, missing teeth, neoplasias, osteodental disharmony, suckling habits, cysts, micrognathia, endocrine problems, or Paget's deforming osteitis. According to Moyers, the labial frenum is responsible for interincisal diastemas in only 24% of the cases.<sup>8,9</sup>

*Dr. Navarro is a postgraduate student and assistant professor, Special Laboratory of Lasers in Dentistry; Dr. Gontijo is a postgraduate student and Drs. Ciamponi and Haddad are professors, all in the Department of Orthodontics and Pediatric Dentistry, School of Dentistry, University of São Paulo, São Paulo, Brazil; Dr. Haypek is a postgraduate student, Department of Restorative Dentistry and Special Laboratory of Lasers in Dentistry, School of Dentistry, University of São Paulo.  
Correspond with Dr. Haddad at [ahaddad@usp.br](mailto:ahaddad@usp.br)*

Hirschfeld was the first author to advocate frenectomy when there was tensing of the tissues adjacent to the teeth, specifically the marginal gingiva, caused by the insertion of the frenum.<sup>10</sup> Frenectomy is the surgical procedure involving removal of the frenum. It is indicated:

1. in the presence of hypertrophic labial frenum;
2. when it provokes diastemas;
3. when it makes dental hygiene difficult or promotes the impacting of food.<sup>4</sup>

There are numerous surgical techniques for removal of the labial frenum. In 1977, Edwards called it "frenectomy" for total removal of the frenum and "frenotomy" when part of the frenum is removed and the remaining part is grafted in such a way as to reposition it between the insertion point on the gingiva and the free marginal gingiva.<sup>11</sup> Haddad and Fonoff classified these techniques, respectively, as "excisional" (total removal of the anatomical portion of the labial frenum) and "repositioning" (anatomical change of the labial frenum's position).<sup>5</sup>

Laser is an acronym for "light amplification by stimulated emission of radiation." It is an electron magnetic energy that presents directional, collimated, and monochromatic properties and coherence—both temporal and spatial—that distinguish it from disorganized and incoherent radiant energy.<sup>12</sup> The laser medium can be solid, liquid, or gas. This laser medium determines the wavelength emission of the laser and the properties and physical interaction with biological tissues.<sup>13,14</sup> The lasers can be classified as:

1. high-power laser treatment (HILT), leading to thermal and heat effects in irradiated tissues (incision, coagulation, vaporization, ablation);
2. low-power laser therapy (LILT), leading to no thermal effects but instead modulating (stimulation or inhibition) physiological processes inside cells.

The application of lasers in pediatric dentistry has arisen as a new tool to perform different clinical procedures in substitution of conventional procedures or in association with and complementary to conventional procedures. Previous authors described the use of different lasers in soft and hard tissue as more comfortable and well accepted by infant patients and parents, leading to a reduction of psychological trauma and fear during the dental appointment.<sup>15-18</sup>

Soft-tissue procedures were frequently rejected in the past because they were impossible to perform without general anesthesia in infants.<sup>19</sup> When it comes to surgical procedures, children and adolescents are special patients, because it is frequently difficult to get the child to cooperate. Because of this, the utilization of lasers in surgical procedures in children promotes the patient/professional relationship, as it can facilitate behavior management of the infant patient. Lasers' advantages include:

1. requiring less operating time;
2. promoting blood clotting;
3. needing a smaller amount of anesthetic;
4. frequently dispensing with the need to use sutures;
5. resulting in a postsurgical period with less pain and swelling when compared to conventional surgical techniques.<sup>17,18,20,21</sup>

The laser's hemostatic nature is of great value in oral and maxillofacial surgery.<sup>22</sup> Therefore, there is great potential for infant patients to benefit from the advantages that laser surgery provides.

The diode, neodymium, erbium, and CO<sub>2</sub> lasers are approved by the Food and Drug Administration (FDA) for use in oral surgery. The incorporation of the use of lasers in a variety of surgical procedures has been well documented.<sup>22-24</sup> The diode lasers present a solid semiconductor as an active medium by associating aluminum, gallium, and arsenate (with wavelengths varying between 800 and 980 nm), in the visible and invisible range of near infrared waves. Diode lasers can also demonstrate a system of delivery of the ray cluster through quartz optical fiber. The fiber's extremity should be cleaned frequently and split to maintain the light's effectiveness. The emission of the rays can be in a continuous or interrupted-continuous mode.<sup>24,25</sup> In clinical procedures on soft tissues, the continuous mode can be used frequently.

The diode laser's wavelength has high absorbance by pigmented tissues containing hemoglobin, melanin, and collagen chromophores and little absorbance by the hard dental tissues. Therefore, this wavelength is safe and well indicated for: (1) soft oral tissue surgeries in regions near dental structures; (2) cutting; (3) vaporization; (4) curettage; (5) blood coagulation; and (6) hemostasis.

It is also important to remember that a diode laser can cause a rapid temperature rise in the target tissue. The "diode revolution" has resulted in the development of high-intensity lasers that are much smaller and less expensive. Hence, they are more accessible to the surgeon dentist.<sup>24,26-29</sup>

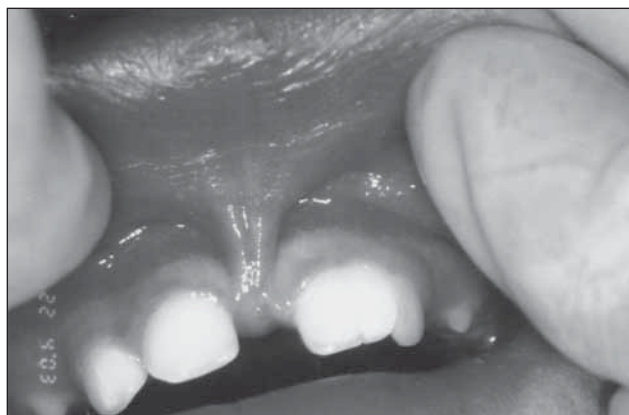The Er:YAG laser (2.94μm) presents a solid active medium—the garnet-aluminum-yttrium crystal—doped with erbium. The wavelength is situated on the invisible infrared strip near the nonionizing area. It is a pulsating laser with a system of delivering rays through an optic fiber, a hollow wave guide, or articulated arm. It is highly absorbed by water and the hydroxyl group of mineral apatite, presenting a strong interaction with the soft tissues' surface layers of the oral cavity and hard dental tissues, removing them with great efficacy.<sup>30</sup>

The erbium lasers promote the vaporization of water contained in the interior of the tissues in a physical, thermomechanical process called ablation. Moreover, the erbium lasers produce less thermal damage because they are pulsate lasers that utilize the air-water as a refrigeration system and are highly absorbed by intrinsic water—leading to energy concentration in irradiated tissue surface layers. These lasers also show less hemostasis effects when compared to the CO<sub>2</sub> and Nd:YAG lasers.<sup>20-23,31</sup>

The purpose of this paper was to describe a clinical case of labial frenectomy in an infant accomplished by the repositioning technique using 2 different high-power lasers: diode (810 nm; ZAP Lasers, Calif) and Er:YAG (2,940 nm; Opus 20, Opus Dent, Israel).

## CLINICAL CASE

The patient, a 24-month-old female, was seen in the pediatric dentistry postgraduate clinic at the School of Dentistry,



**Figure 1. View of the hypertrophic labial frenum.**

University of São Paulo (FOUSP), São Paulo, Brazil. The chief complaint related by the mother was the difficulty of cleaning the teeth in the upper incisors region due to the volume of the superior labial frenum (Figure 1).

The appointments and lasers used in this clinical case were performed at the Special Laboratory of Lasers in Dentistry, School of Dentistry, University of São Paulo (LELO FOUSP) using all the equipment and technical support available at this center. The psychological approach to the child was accomplished conventionally, using the techniques of "tell-show-do" and distraction.

At the first appointment:

1. prophylaxis was accomplished;
2. fluoride varnish was applied;
3. the mother was given dental hygiene and diet instructions.

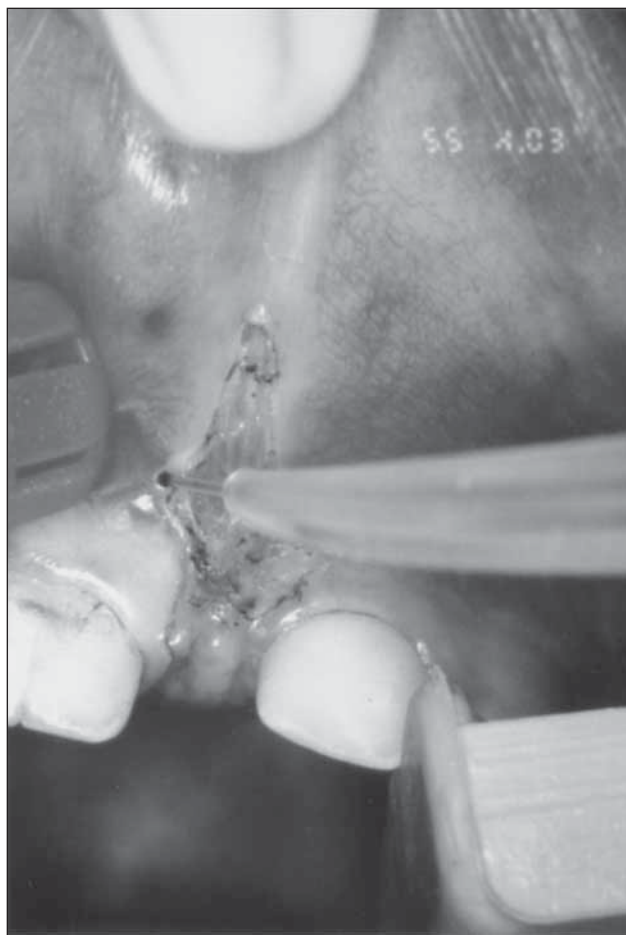
At the second session, the child was:

1. shown all the laser equipment;
2. presented protective goggles specific to the laser to become familiar with them;
3. administered topical anesthesia to become familiar with the anesthetic's taste and sensation.

During the surgical procedure, the dentist used the distraction techniques of singing age-appropriate children's songs to obtain behavioral control of the child. The topical anesthesia was administered and was followed soon afterward by the infiltrating anesthesia in the bottom of the gingival-labial sack, close to the area of the labial frenum. The anesthetic amount necessary for pain control was only a half carpule of 2% lidocaine.

The frenectomy procedure was first accomplished with the diode laser (GaAlAs; ZAP Lasers, Soft Lase, Calif) aiming a visible red diode beam (650 nm). The laser was operated in continuous or pulsed (10 pps) wave mode with a pulse width of 50 milliseconds, a wavelength of 810 nm ( $\pm 5$  nm), and a maximum output power of 3.5 W. In this clinical case, the diode laser was used with an output power of 1.5 W, in continuous wave mode, using a 600- $\mu$ m quartz optical fiber in contact with the tissue (Figure 2) to incise, vaporize, and remove the fibers and soft tissues (Figure 3).

Afterwards, the Er:YAG laser (Opus 20, Opus Dent, Tel Aviv, Israel) was applied, using a wavelength of 2,940 nm and aiming a beam of visible red diode (630 nm). It was operated in



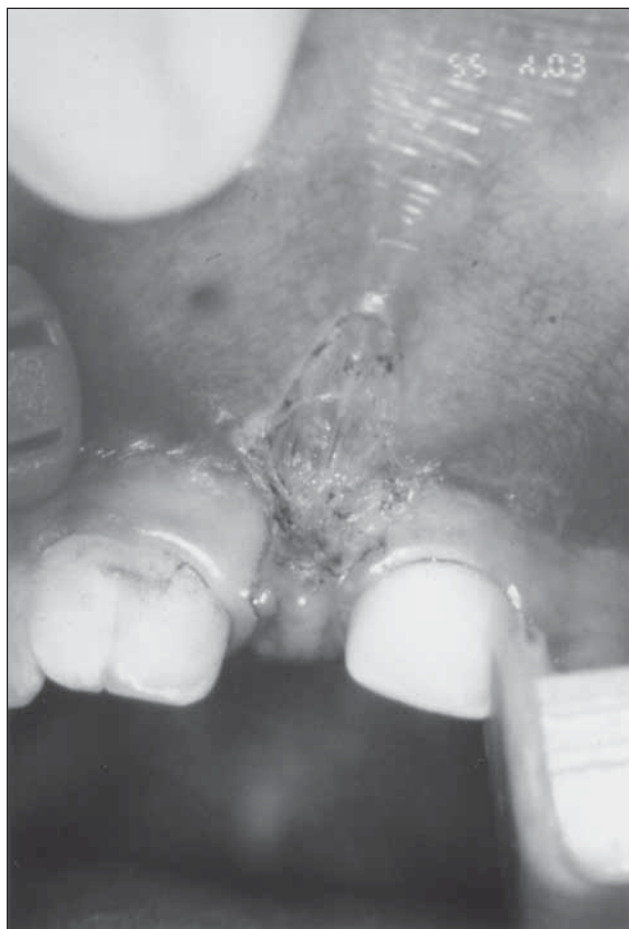**Figure 2. Use of the diode laser in the continuous mode of operation with the optic fiber in contact with the tissue.**

pulsed wave mode, with a pulse repetition rate of 10 to 20 pps and a pulse width of 200 to 500  $\mu$ m. A refrigeration by air-water and hollow wave guide delivering system was also used. This laser had an output energy of 150 mJ and a repetition rate of 10 pps. It was used in noncontact mode (2 mm to target tissue), with a sapphire tip (1-mm diameter) in a handpiece, to complete the final removal of frenum fibers inserted on the alveolar bone and periosteum tissue up to the limit of the palatine papillae (Figures 4 and 5).

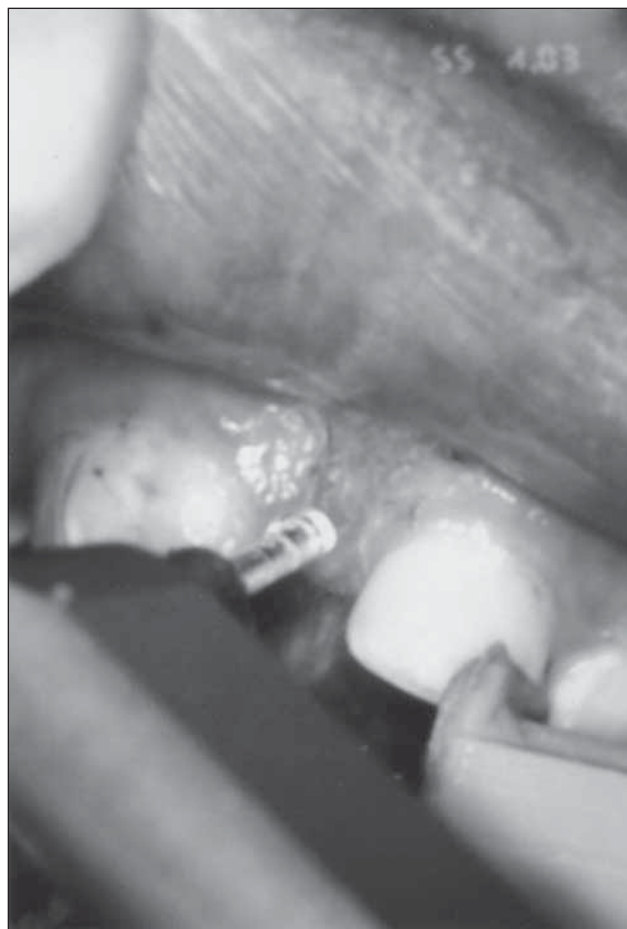It is important to note that infection control protocols were followed in the same manner as conventional surgery. The child, mother, and all the professionals used protection goggles appropriate for each laser wavelength.

An analgesic was prescribed to prevent postoperative discomfort. According to the report of the child's mother, however, it was not necessary. To clean the teeth near the operated region, the mother was instructed to wipe them with gauze soaked in chlorhexidine 0.12% during the first 3 days after the operation. The postoperative healing of the surgical wound 3 days after surgery can be seen in Figure 6. There was no evidence of complications in the postoperative period and total healing was seen 17 days after surgery (Figure 7). Figure 8 shows the new insertion of the labial frenum, in the limit between inserted gum and oral mucosa.





**Figure 3.** Aspect of the labial frenum after the first part of the procedure.



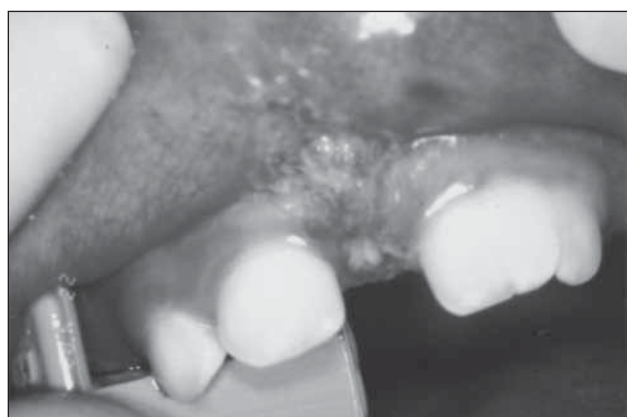**Figure 4.** Use of the Er:YAG laser in the removal of the fibers inserted on the alveolar bone.

## DISCUSSION

The abnormal or prominent labial frenum appears as a thick band of tissue arising from the oral mucosa of the upper or lower lip and extending to the border of the alveolar bone and up to the palatal papillae.<sup>3,17</sup> The labial frenectomy procedure is indicated when there is a diagnosis of persistent labial roof frenum or pathological interincisal diastema and/or a periodontal risk exists.<sup>2,6,7</sup>

There is controversy among clinicians concerning the right time to perform the surgery. Fonseca recommended waiting until after the permanent lateral incisors erupt. The majority of other authors, however, indicate the surgery should be performed after the permanent canines erupt, while others advocate for surgery to be performed after the permanent central incisors erupt.<sup>32</sup> All these controversies, however, are related to the frenectomy as a part of the treatment of a superior interincisal diastema. Kotlow suggests that optimal results are accomplished when the procedure is done between 8 and 18 months of age.<sup>19</sup>

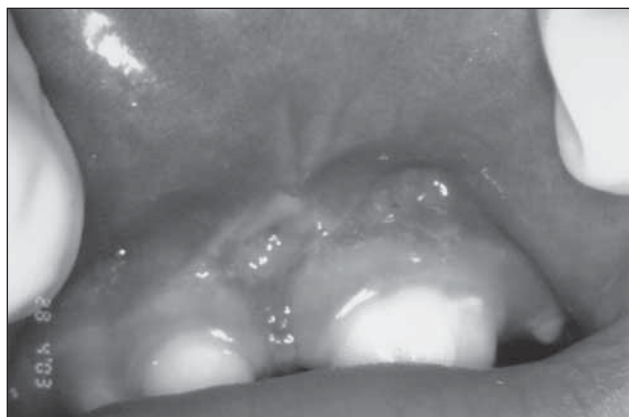
In this clinical case, the authors opted for performing a frenectomy on a young child due to periodontal risk, the difficulty of cleaning the maxillary incisors, and speed and ease of the laser procedure compared to conventional surgery. Clinically, a practitioner could observe a double frenum, with fibrous tissue, as shown in Figure 1. Although



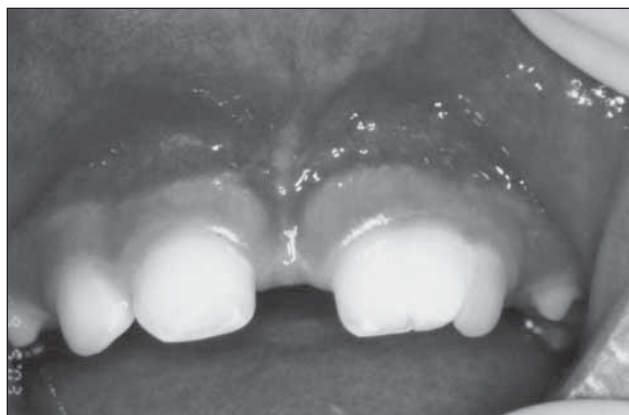**Figure 5.** View post-surgery.

it is not the subject of this paper, Figures 1, 5, and 7 also show the central left maxillary incisor to be a double tooth.

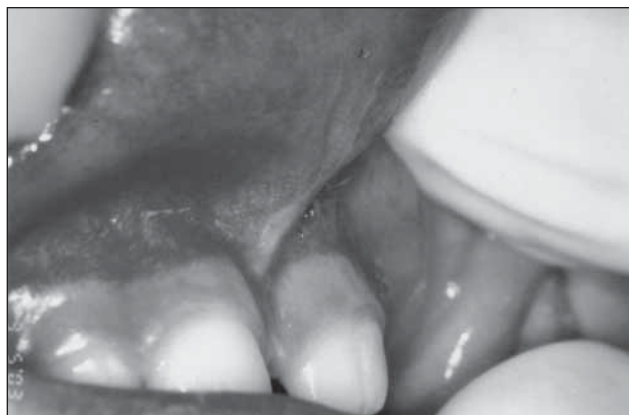In this clinical case, the technique of repositioning was performed. The first incision of the labial frenum was accomplished with the diode laser, up to the limit between the inserted gingiva and the alveolar mucosa—where one should reposition the insertion of the frenum. The diode laser was used for vaporization of fibers and coagulation effects. Afterwards, the Er:YAG laser was used under refrigeration for the removal of the final



**Figure 6.** View of the sixth day after surgery.



**Figure 7.** Frontal view of the labial frenum 17 days after laser surgery.



**Figure 8.** Lateral view of the labial frenum, showing its new insertion, in the limit between inserted gingival and oral mucosa.

fibers remaining on the alveolar border and periosteum tissue up to the limit of the palatal papillae.

Although in this clinical case the Er:YAG laser equipment (Opus 20) was used, there are other manufacturers of Er:YAG laser equipment available from manufacturers in the United States, Germany, Japan, and Italy. When the operator chooses specific laser equipment for clinical use for hard and soft tissue

management, he/she should know the function and resources of the chosen equipment, understand the laser wavelength interaction, and be able to apply the appropriate parameter to the clinical application.

The use of lasers in hard tissues (cavity preparation, etching, apicoectomy, osteotomy, bacterial reduction) and soft tissues (frenectomy, gingivectomy, operculectomy, crown lengthening, hyperplastic tissues) must be performed by trained professionals. They should have expert knowledge about optical properties, composition of target tissues and laser safety, risks and damages, security rules, interaction with tissues, and useful parameters. The operator should determine the pulse width, optimum energy, and repetition rate, and always choose the minimum fluence to promote effective and safe ablation of the target tissue.<sup>23,33</sup>

In this clinical case, insertion of the fibers in the interior of the bone tissue and periosteum limited the utilization of the diode laser. This wavelength shows low absorbance to hard tissues and operates in a continuous or interrupted continuous wave mode, promoting high thermal side effects and heat propagation to surrounding tissues. This can cause thermal damage to the medullae bone and tissue necrosis. For these reasons, the diode laser could not be used in direct contact with the bone tissue.<sup>25-29</sup>

Therefore, it became necessary to use the Er:YAG laser. This wavelength is well absorbed by water and apatite mineral contained in the alveolar bone tissue. It operates in pulsed wave mode, promoting efficient ablation of hard tissue with minimal thermal effects and safety to bone. In this way, a practitioner can avoid the propagation of thermal damage in the tissues involved.<sup>23,31,33,34</sup> Besides, the erbium laser causes no carbonization or charring of irradiated soft tissues, with no delay in the wound healing process, when compared to the CO<sub>2</sub> laser.<sup>31</sup>

The advantages of using both laser wavelengths in the surgical procedure included:

1. the facility of the technique;
2. hemostasis effect;
3. absence of bleeding;
4. excellent visualization of the operating field;
5. absence of need for sutures and surgery cement;
6. less need for local anesthesia;
7. reduced operating time;
8. absence of postoperative edema and pain.<sup>13,17,18,21,25</sup>

These advantages promoted by the laser contributed to the child's good behavior during the procedure. Despite the fact that this was an extremely young patient, there was no need for physical restraint, sedation, or the use of a tranquilizer. The child remained calm during the entire surgical procedure.

## CONCLUSIONS

It is absolutely necessary for the professional to:

1. understand the laser's physical characteristics and its interaction with the biological tissues to use it in a safe way;
2. obtain the benefits that this technology can provide for infant patients.

## ACKNOWLEDGEMENTS

The authors would like to thank the support of Special Laboratory of Lasers in Dentistry, School of Dentistry, University of São Paulo, São Paulo, Brazil.

## REFERENCES

1. Henry SW, Levin MP, Tsaknis PJ. Histologic features of superior labial frenum. *J Periodontol* 1976;47:25-28.
2. Coletton SH. Mucogingival surgical procedures employed in re-establishing the integrity of the gingival unit (III): The frenectomy and the free mucosal graft. *Quintessence Int* 1977;8:53-61.
3. Zegarelli EV, Kutscher AH, Hyman GA. Anomalies and malformations. In: Zegarelli EV, Kutscher AH, Hyman GA, eds. *Diagnosis of Diseases of the Mouth and Jaws*. Philadelphia: Lea and Febiger; 1978:512-513.
4. Lawrence GB, Fowler EB, Moore EA, Murray DJ. The free gingival graft combined with the frenectomy: A clinical review. *Gen Dent* 1999;47:514-518.
5. Haddad AE, Fonoff, RDN. Freio teto-labial persistente—Diagnóstico e tratamento cirúrgico. *Jornal Brasileiro de Odontopediatria e Odontologia do Bebê* 2000;3:125-129.
6. Gottsegen R. Frenum position and vestibule depth in relation to gingival health. *Oral Surg* 1954;7:1069-1072.
7. Koerner KR, Tilt LV, Johnson KR. Management of the abnormal frenum. In: *Color Atlas of Minor Oral Surgery*. London: Mosby-Wolfe; 1994:173-198.
8. Goodman NR. Treatment of diastema: Not always frenectomy. *Dent Surv* 1975;51:28-34.
9. Araújo LB, Bolognese AM. Diastema interincisal e freio labial anormal. *Rev Bras Odontol* 1983;40:20-28.
10. Hirschfeld I. The toothbrush: Its use and abuse. *J Am Dent Assoc* 1939;26:1237-1238.
11. Edwards JG. The diastema, the frenum, the frenectomy. *Oral Health* 1977;67:51-62.
12. Nelson JS, Berns MW. Basic laser physics and tissue interactions. *Contemp Dermatol* 1988;2:3-15.
13. Pick RM, Powell GL. Lasers in dentistry: Soft-tissue procedures. *Dent Clin North Am* 1993;31:281-297.
14. Gutknecht N, Frazen R. O laser: Função, Interação e Segurança. In: Gutknecht N, Eduardo CP, eds. *A Odontologia e o laser-Atuação do Laser na Especialidade Odontológica*. Berlin: Quintessenz Verlags-GmbH; 2004:25-60.
15. Gimble C, Hansen R, Swett A, Winn D, Pelagalli J, Cozean C. Er:YAG clinical studies for hard tissue applications. Proceedings of the ISLD Congress, Singapore, 1994:267-271.
16. Cozean CD, Powell L. Er:YAG clinical results on hard tissue: phase II. In: Featherstone JD, Rechmann P, Fried DS, eds. *Lasers in Dentistry IV*. Proceedings SPIE. 1998;3248:33-39.
17. Matsumoto, K, Hossain M. Frenectomy with the Nd:YAG laser: A clinical study. *J Oral Laser Appl* 2002;2:25-30.
18. Eduardo CP, Navarro RS, Gontijo I, Haypek P, Côrrea MSN. Utilização Clínica do Laser em Odontopediatria. In: Gutknecht N, Eduardo CP, eds. *A Odontologia e o laser-Atuação do Laser na Especialidade Odontológica*. Berlin: Quintessenz Verlags-GmbH; 2004:241-262.
19. Kotlow LA. Laser in pediatric dentistry. *Dent Clin North Am* 2004;48:889-922.
20. Strauss RA. Lasers in oral and maxillofacial surgery. *Dent Clin North Am* 2000;44:851-873.
21. Fonoff R, Watanabe IS, Eduardo CP. Reparação tecidual da mucosa bucal de ratos submetidos a frenectomia labial com laser de CO<sub>2</sub>: Estudo ao microscópio de luz. *Pesqui Odontol Brás* 2003;17:210.
22. Strauss RA, Fallon SD. Lasers in contemporary oral and maxillofacial surgery. *Dent Clin North Am* 2004;48:861-888.
23. Wigdor HA, Walsh JT, Featherstone J, Visuri SR, Fried D, Waldvogel JL. Lasers in dentistry. *Lasers Surg Med* 1995;16:103-133.
24. Coluzzi DJ. An overview of laser wavelengths used in dentistry. *Dent Clin North Am* 2000;44:753-765.
25. Goharkhay K, Moritz A, Wilder-Smith P, Schoop U, Kluger W, Jakolitsch S, Sperr W. Effects on oral soft tissue produced by a diode laser in vitro. *Lasers Surg Med* 1999;25:401-406.
26. Romanos GE, Karman MA, Nentwig GH. Clinical experience with a diode laser in oral surgical procedures. Proceedings of ISLD Congress, 1998:38.
27. Romanos GE, Nentwig GH. Diode laser (980 nm) in oral and maxillofacial surgical procedures: Clinical observations based on clinical applications. *J Clin Laser Med Surg* 1999;17:193-197.
28. Coluzzi DJ. Fundamentals of dental lasers—science and instruments. *Dent Clin North Am* 2004;48:751-770.
29. Hibst R, Keller U. Experimental studies of the application of Er:YAG laser on dental hard substances: I. Light microscopic and SEM investigations. *Lasers Surg Med* 1989;9:338-344.
30. Keller U, Hibst R. Er:YAG laser effects on oral hard and soft tissues. In: Miserendino, LJ, Pick RM, eds. *Lasers in Dentistry*. Carol Stream: Quintessence; 1995:161-172.
31. Fonseca GD. Frenectomia lingual. *Rev Fed Odontol Ecuat* 1970;1:307-311.
32. Fried D., Ragadio JA, Champion D. Residual heat deposition in dental enamel during IR laser ablation at 2.79, 2.94, 9.6 and 10.6  $\mu\text{m}$ . *Lasers Surg Med* 2001;29:221-229.
33. Swick M. Cosmetic diode laser gingivectomy with frenectomy. Featured wavelength: Diode. 2000;8:19.
34. Dostálová T, Jelínková H, Kucerová H, et al. Noncontact Er:YAG laser ablation: Clinical evaluation. *J Clin Laser Med Surg* 1998;16:273-282.