

# Oligodontia in the Primary Dentition: Report of a Case

**Karthik Venkataraghavan, MDS**

**Athimuthu Anantharaj, MDS**

**Praveen Prasanna, MDS**

**R. Sudhir, BDS**

## ABSTRACT

Congenital absence of primary teeth is relatively rare. The prevalence, possible etiological factors and management of oligodontia was briefly reviewed. This paper reports a rare case of multiple missing (n=18) primary teeth in a 4-year-old male of Asian origin. (J Dent Child 2007;74:154-6)

**KEYWORDS:** MORPHOLOGY FACIAL, MIXED DENTITION, OCCLUSAL FORCE, PREMATURE TEETH LOSS

Congenital absence of primary teeth is relatively rare.<sup>1</sup> Congenital absence of a few teeth in the primary or permanent dentition could be described by 2 terms, hypodontia, which is the absence of 1 or few teeth, and oligodontia, which is the absence of numerous teeth and is commonly associated with specific syndromes and/or severe systemic abnormalities.<sup>2</sup>

Agenesis is rare in the primary dentition. Indeed, the reduction in number of teeth is concomitant with the reduction in the size of the jaw in human evolution and believed to be a continuing evolutionary trend.

According to Shapiro,<sup>5</sup> congenital absence of teeth is the most common dental anomaly in man. Hypodontia in primary dentition is rare. If it occurs, it is seen in the incisor region and is often associated with missing succedaneous teeth.<sup>6</sup> The most commonly missing teeth in the dentition in Asian patients are the mandibular incisors.<sup>7</sup> Taurodontism and a reduced tooth length have been reported to occur in patients with oligodontia. A recent study of oligodontia patients indicated that 11% of the mandibular first molars showed taurodontism and short roots.<sup>8</sup> Causes of missing teeth, particularly anodontia—an extreme expression of oligodontia—are very rare and challenging to the clinician.<sup>9</sup>

Scientific analysis of the congenital absence of teeth in humans dates back to the early 1900s. A classical study was

conducted by Grahen in 1956<sup>10</sup> on parents and siblings of 171 hypodontia patients. Grahen concluded that, in the majority of cases, oligodontia is mainly determined by a dominant autosomal gene pattern with incomplete penetrance of the trait and variable expressivity.

There is no precise, factual description of the causal factors underlying the lack of formation of certain teeth. Possible causes include trauma, infection of the developing tooth bud, radiation overdose, glandular dysfunction, systemic conditions such as rickets or syphilis, German measles during pregnancy, and severe intrauterine disturbances and heredity.<sup>4</sup>

## CASE REPORT

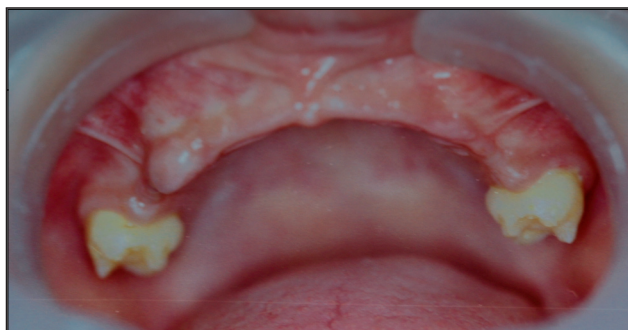A 4-year-old Asian boy presented to the department of Pediatric Dentistry, RV Dental College and Hospital, Bangalore, Karnataka, India, with the complaint of missing primary teeth and improper speech. His parents related a history of marrying in the same blood line (marriage to a relative). Family history regarding absence of teeth was not significant. The dental history given by the parents suggested the congenital absence of most of the primary teeth.

Intraoral examination during the first visit revealed the presence of only teeth nos. A and J (Figures 1 and 2). The alveolus was very thin, and the teeth were of normal size, shape, and color. The orthopantomograph (OPG; Figure 3) revealed the presence of all the permanent tooth buds.

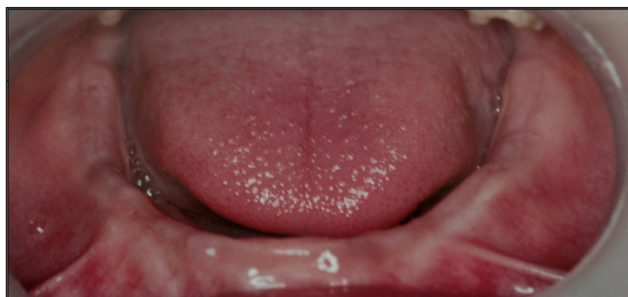After the initial visit, the child did not report back to the clinic for the next year. During the second visit a year later, another intraoral examination was carried out—revealing the absence of tooth no. J and the presence of only no. A. Another OPG (Figure 4) taken during this visit revealed

*Drs. Venkataraghavan and Praveen are assistant professors, Dr. Anantharaj is professor and Head of Department, and Dr. Sudhir is lecturer, all in the Department of Pedodontics, RV Dental College and Hospital, Bangalore, India. Correspond with Dr. Karthik at [veekart@yahoo.co.in](mailto:veekart@yahoo.co.in)*

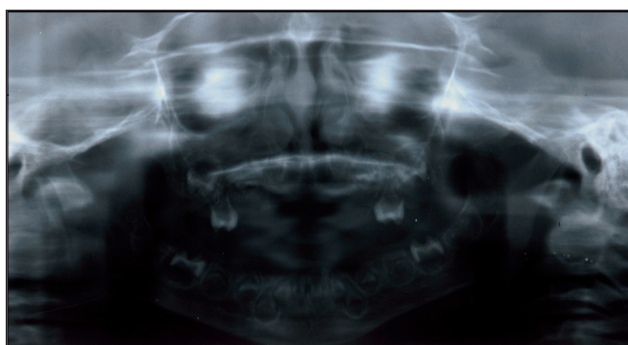
the following: presence of A; defective formation of dentin in teeth nos. 3, 14, 19, and 30.



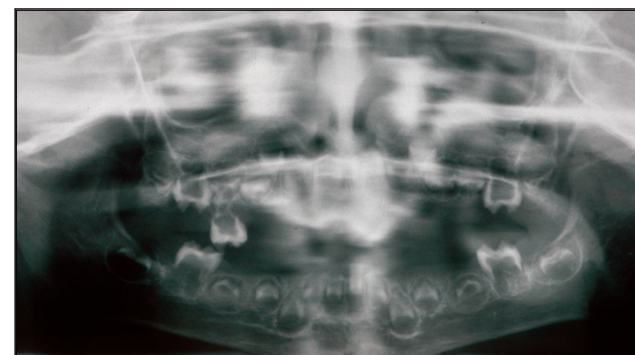
**Figure 1.** An intraoral photograph showing the maxillary arch with Right and Left Second Primary Molars



**Figure 2.** An intraoral photograph showing the Mandibular arch with all Primary Teeth missing.



**Figure 3.** Orthopantomogram (OPG) showing congenital absence of all primary teeth except the maxillary right and left primary second molars and the presence of all the permanent tooth buds.



**Figure 4.** Orthopantomogram (OPG) showing missing left primary second molar and the presence of all the developing permanent tooth buds with defective formation of dentin & the roots of the permanent molars and Lower central Incisors.

## DISCUSSION

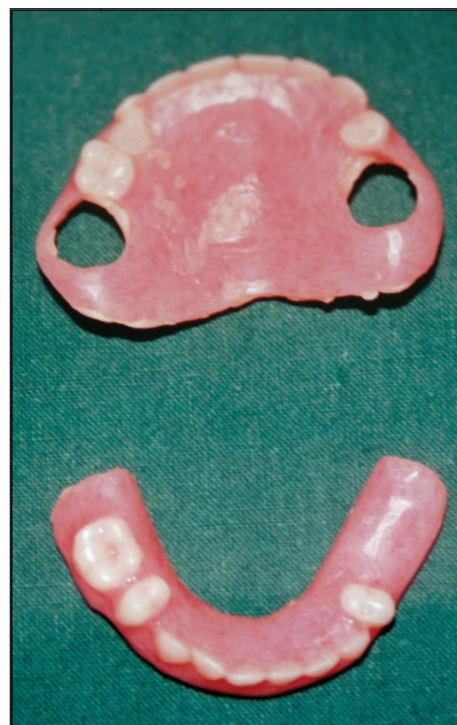This is an interesting case for several reasons. First there are few cases reported in the dental literature regarding the congenital absence of primary teeth.<sup>3</sup> In this case, there are 18 missing teeth, which makes it an even rarer finding. Parental history of marrying a relative may be suggestive of such an anomaly, as the literature is replete with cases where there has been a developmental anomalies in children from such marriages. As the patient lives in a different state than the authors' clinic where he reported, other medical tests could not be performed. Radiographic pictures show evidence of the presence of all permanent tooth buds and defective formation of dentin in teeth nos. 3, 14, 19, and 30.

The parent's main concerns were speech impairment and missing teeth. To tackle these problems, the patient is being managed with complete dentures and periodic recalls. As the child actively grows, he will require long-term prosthodontic management.

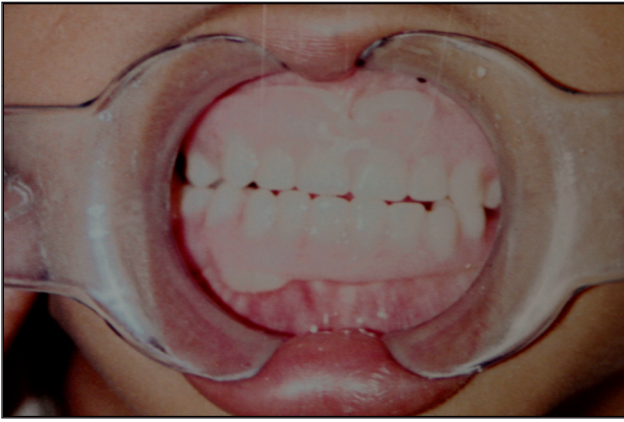## SUMMARY

The patient's main concern was speech impairment due to missing primary teeth. To improve the child's speech and esthetics, the authors decided to fabricate complete dentures.

During the first visit, the child showed the presence of teeth nos. A and J. Consequently, upper and lower complete dentures were fabricated with openings in the region of teeth nos. A and J (Figures 5 and 6). During the second visit, J teeth had exfoliated. The dentures had become loose, so a new set was fabricated with an opening only in the region of tooth no. A.



**Figure 5.** Photograph showing the upper and lower complete dentures with windows created in the region of the maxillary right and left primary second molars.



**Figure 6.** Photograph showing the upper and lower dentures inside the oral cavity.

The parents reported a drastic improvement in the child's speech and mastication. The patient is being kept under periodic observation to initiate future treatment modification if and when the need arises.

## REFERENCES

1. Mc Donald RE, Avery DR. Acquired and developmental disturbances of the teeth and associated oral structures. *Dentistry for the Child and Adolescent*. St. Louis, Mo: CV Mosby; 1989:147.
2. Stewart RE. The dentition and anomalies of tooth size, form, structure, and eruption. *Pediatric Dentistry: Scientific Foundations of Clinical Procedures*. St. Louis, Mo: CV Mosby; 1982:91.
3. Shashikiran ND, Karthik V, Subba Reddy VV. Multiple congenitally missing primary teeth: Report of a case. *Pediatr Dent* 2002;24:2,149-52.
4. Lee W Graber, Congenital absence of teeth: A review with emphasis on inheritance patterns. *J Am Dent Assoc* 1978;96:266-75.
5. Shapiro SD, Farrington FH. A potpourri of syndromes with anomalies of the dentition. *Birth Defects Orig Artic Ser* 1983;19:129-40.
6. Meon R. Hypodontia of the primary and permanent dentition. *J Clin Pediatr Dent* 1992;16:121-3.
7. Davis PJ. Hypodontia and hyperdontia of permanent teeth in Hong Kong schoolchildren. *Community Dent Oral Epidemiol* 1987;15:218-20.
8. Van Der Weide Y, Sheen WHA, Bosman F. Taurodontism and length of teeth in patients with oligodontia. *J Oral Rehabil* 1993;401-12.
9. Yamashita Y, Miyazaki H, Ueno S, Takehara T. Dento-facial structure with complete anodontia of permanent teeth: Report of a case. *J Dent Child* 1992;59:231-4.
10. Grahen HJ. Hypodontia in permanent dentition. *Odontol Rev* 1956;7:1.