

Strategies for Addressing Restorative Challenges in HIV-infected Children

Juliana Pires Abdelnur, DDS, MSD Daniella Ferraz Cerqueira, DDS, MSD
Gloria Fernanda Castro, DDS, MSD, PhD Lucianne Cople Maia, DDS, MSD, PhD
Ivete Pomarico Ribeiro de Souza, DDS, MSD, PhD

ABSTRACT

The complete caries removal of deep/extensive dentin carious lesions with conventional procedures (high- and low-speed bur) may increase the risk of pulp exposure. In children with systemic diseases, such as HIV-infected children, the dental treatment proposed for the primary dentition with pulp involvement is tooth extraction once endodontic therapies cannot be guaranteed successfully. Therefore, the objective of this study was to describe 3 cases of alternative techniques for caries removal in extensive and/or deep dentin carious lesions in the primary dentition of HIV-infected children: (1) atraumatic restorative treatment (ART); (2) Carisolv; and (3) Papacarie. (*J Dent Child* 2008;75:69-73) Received October 16, 2006 | Last Revision February 8, 2007 | Revision Accepted February 13, 2007.

KEYWORDS: CHILDREN, DENTAL CARIES, HIV-INFECTION, RESTORATIONS

The dental literature demonstrates a higher prevalence of dental caries in HIV-infected children compared to noninfected, especially in the primary dentition.^{1,2} The prevalence rates for caries in the primary dentition of HIV-infected children range from 36% to 60%,^{3,4} and the dmft mean scores range from 4.4 to 16.9.^{4,5} Many hypotheses have been suggested to justify the development of carious lesions in HIV-infected children as:

1. a frequent intake of sweetened drugs^{6,7};
2. hypercaloric nutrition (high sugar consumption to increase caloric intake and compensate for weight loss⁶);
3. the presence of oral lesions, which makes oral hygiene difficult and increases the ingestion of sweetened liquid food⁸;
4. parents' negligence to their children's oral health⁹;
5. alterations in salivary flow as a side effect of the intake of some drugs or as a consequence of HIV salivary gland disease^{10,11};
6. immunodeficiency as a result of HIV infection¹²;
7. the decrease of salivary immunoglobulin total count with the progression of AIDS disease.¹³

The presence of decayed teeth with or without pulp involvement and a dental abscess in the oral cavity may be considered a focus of infection for HIV-infected children. Due to the compromised immune system of these patients, the dental treatment proposed for the primary dentition with pulp involvement is tooth extraction once the pulp therapy in such cases cannot be successfully guaranteed.¹⁴

The chemomechanical and mechanical techniques may be used for caries removal in children with systemic diseases, such as HIV-infected children, and they also fulfill the requirements for utilization in field programs. Moreover, these techniques are considered more conservative than complete caries removal with conventional procedures (high- and low-speed bur) since they follow the concept of removing the affected dentin and decrease the removal of sound dentin.¹⁵⁻¹⁹

Therefore, the aim of the present study was to describe 3 alternative techniques used for caries removal in extensive and/or deep dentin carious lesions in the primary teeth of HIV-infected children.

CASE REPORTS

The subjects of these case reports consisted of 3 patients from a pediatric AIDS outpatient clinic (Instituto de Pediatria e Puericultura Martagão Gesteira-IPPMG) of the Federal University of Rio de Janeiro, Brazil. All children included had a definitive diagnosis of HIV infection, confirmed by 2

Drs. Abdelnur and Cerqueira are postgraduate students, Drs. Castro and Maia are adjunct professors, and Dr. de Souza is full professor, all in the Department of Pediatric Dentistry and Orthodontics, School of Dentistry, Federal University of Rio de Janeiro, Rio de Janeiro, Brazil. Correspond with Dr. Maia at rorefa@terra.com.br.

positive ELISA tests and 1 western blot. All children were also participants in a dental health program (SIDA [Syndrome d'Immuno Déficience Acquis]/AIDS project) instituted by the pediatric dentistry department of the Federal University of Rio de Janeiro that provides dental assistance for HIV-infected children. Informed consents were obtained from all children's parents/legal guardians.

A record file was made for each child providing data on anamnesis, oral examination, diet, and oral hygiene. Prior to oral examination, an assistant performed the children's tooth-brushing with a fluoridated toothpaste, followed by a topical fluoride application (2.0% sodium fluoride). A trained dental team performed the examination with the child lying on a cot. Gauzes were used to dry dental surfaces. Using the buccal mirror with the aid of a flashlight to illuminate the oral cavity, the DMFS and dmfs scores were recorded. Orofacial lesions, when present, were also recorded. All children with dental needs were scheduled for the dental treatment.

As a routine of SIDA/AIDS program, carious lesions are treated by dentists of the AIDS outpatient clinic and those children who needed a dental extraction and radiographic examination are referred to the pediatric dental clinic of the Federal University of Rio de Janeiro.

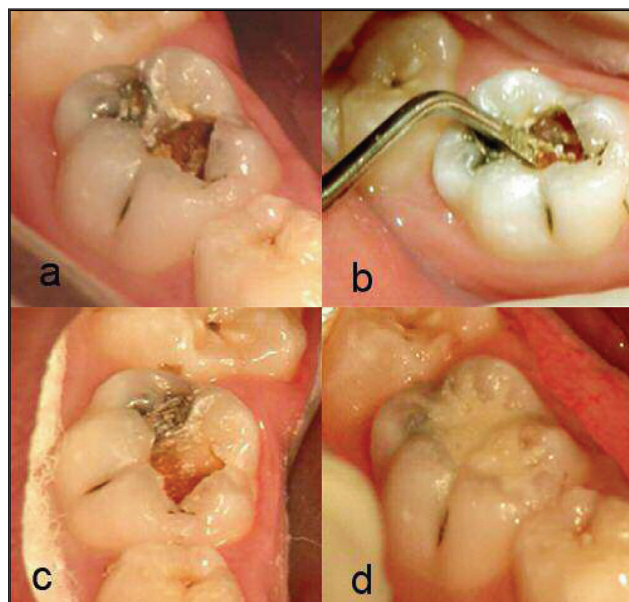


Figure 1a. Second primary mandibular tooth with an extensive and deep carious lesion in the dentin.

Figure 1b. Soft infected dentin excavation with manual instrument.

Figure 1c. Final aspect of the cavity after removal of the carious lesion.

Figure 1d. Restoration of tooth no. T with glass ionomer cement (Fuji-IX).

CASE NO. 1

A 7-year-old female African American child was brought by her father for a regular visit at the SIDA/AIDS project. Her medical history demonstrated that she had:

1. mild signs and symptoms of HIV infection; and
2. the absence of immunosuppression;

3. a CD4 percentage of 42%;
4. been under antiretroviral therapy using AZT (zidovudine) and ddI (didanosine) syrups (Table 1);
5. a good hygiene status;
6. a noncariogenic diet; and
7. presented with bilateral submandibular gland enlargement.

After the intraoral examination, only one decayed tooth was observed: the second primary mandibular molar (tooth no. T), with an extensive occlusal lesion (Figure 1). The dentists chose the atraumatic restorative treatment (ART)¹⁵ to remove the carious lesion. The procedure was realized without local anesthesia, and it could be observed that, after the infected tissue removal, no pulp exposure was clinically visible. Afterwards, the tooth was filled with glass ionomer cement (Fuji-IX, GC Corp, Tokyo, Japan; Figures 1a-c). The patient was discharged on the same day.

CASE NO. 2

A 7-year-old female child of African descent was referred by the dental team of the SIDA/AIDS project to the pediatric dental clinic for radiographic examination. The medical history demonstrated that she had:

1. moderate signs and symptoms of HIV infection;
2. severe immunosuppression;
3. CD4 percentage of 15%;
4. been under antiretroviral therapy using AZT, ddI, 3TC (lamivudine), d4T (stavudine), and enfavirenz, all in syrup form (Table 1);
5. a poor hygiene status;
6. a cariogenic diet;
7. generalized gingivitis; and
8. bilateral submandibular gland enlargement.

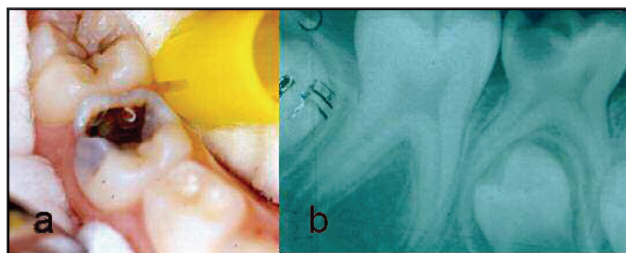


Figure 2a. The second primary mandibular molar (tooth no. T), with an extensive carious lesion in the dentin on the occlusal surface.

Figure 2b. Periapical radiograph of the second primary mandibular tooth (no. T), with a radiolucent image suggesting a dentin carious lesion in the dentin.

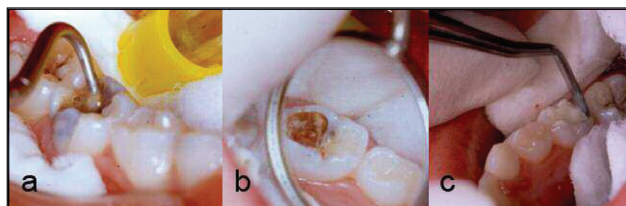


Figure 3a. Gel turbidity as an indicator of removal of infected dentin.

Figure 3b. Final aspect of tooth's cavity after 3 applications of Carisolv gel.

Figure 3c. Restoration of tooth no. T with glass ionomer cement (Fuji-IX, GC Corp).

Her oral exam revealed a dmft score of 9 (5 decayed teeth and 4 teeth that indicated caps extraction). The radiograph exam of the second primary mandibular molar (tooth no. T), showed an extensive carious lesion in the dentin (Figures 2a-b). A chemomechanical method (Carisolv)¹⁷ was chosen to remove dental caries tissue without local anesthesia or rubber dam. This technique achieved its goal, and no pulp exposure was clinically observed. The tooth was restored with glass ionomer cement (Fuji-IX, GC Corp; Figures 3a-c).

CASE NO. 3

A 9-year-old female Caucasian child was referred by the dental team of the project to the pediatric dental clinic for radiographic examination of her second primary mandibular tooth (no. K). Her medical history demonstrated she had:

1. mild signs and symptoms of HIV infection;
2. absence of immunosuppression;
3. not been under antiretroviral therapy (Table 1);
4. a cariogenic diet;
5. poor oral hygiene status;
6. gingivitis localized in the molar areas; and
7. bilateral submandibular gland enlargement.

Her dental exam revealed a dmft score of 5, with 4 decayed teeth and a fractured amalgam filling in the occlusal and lingual surfaces of tooth no. K (Figure 4a). After bite-wing radiographs, the extension and the depth of secondary carious lesion and the possible pulp involvement could be observed (Figure 4b). The caries removal was done using a chemomechanical technique called Papacárie¹⁶ (a chemomechanical method developed in Brazil, already patented and commercialized in Brazil, that currently is being patented

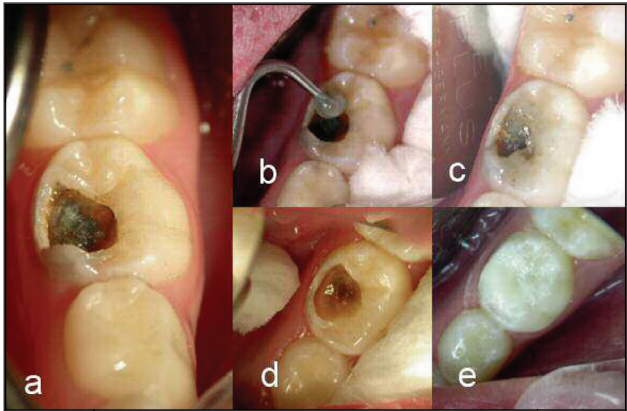


Figure 5a. Initial aspect of dentin carious lesion (extension and deep).
Figure 5b. First application of Papacarie gel.
Figure 5c. Gel turbidity as an indicator of infected dentin removal.
Figure 5d. Final aspect of tooth's cavity after 3 applications of Papacárie gel.
Figure 5e. Restoration of tooth no. K with glass ionomer cement (Fuji-IX, GC Corp).

internationally), following the manufacturer's instructions, without local anesthesia and rubber dam (use of cotton rolls). No pulp exposure was clinically visualized after caries removal (Figures 5c-d). The tooth was then filled with glass ionomer cement (Fuji-IX, GC Corp; Figure 5e).

The dental treatment plan proposed for the decayed teeth of the case 1, 2 and 3 children employed the same techniques for caries removal and tooth extraction when indicated. After the treatment, all 3 patients were scheduled for follow-up visits every month at the SIDA/AIDS project to monitor their restorations and to reinforce oral hygiene and dietary instructions for oral health maintenance. All 3 patients had no clinical signs and symptoms of pulp involvement at the first appointment within 1 month.

DISCUSSION

Most studies demonstrate a higher prevalence of dental caries in HIV-infected children compared to noninfected.^{1,2,13} The same could be observed in these case reports, although 1 child presented only 1 decayed tooth. The factors associated with caries devel-

opment in HIV-infected children are frequently observed among patients from the SIDA/AIDS project, as is shown in Table 1, which demonstrates that all 3 patients had at least 2 or more of these factors present.

At the oral examination, all 3 patients presented with primary teeth that had extensive and deep dentin carious lesions with probable pulp involvement. In such cases, according to McDonald and Avery,¹⁴ tooth extraction is the dental treatment proposed in children with systemic disease. Therefore, this study's purpose was to use alternative techniques for more conservative caries removal in carious lesions in HIV-infected children as an attempt to avoid pulp

Patient	Clinical classification*	Immunological classification†	CD4 (%)	Antiretroviral therapy	Form	Antibiotic therapy	DMFT
Case 1	A	1	42	AZT, ddI	Syrup	Bactrim	1
Case 2	B	2	15	AZT, ddI, 3TC, d4T, efavirenz	Syrup	Bactrim	9
Case 3	A	1	>25	-	-	-	5

* A=mild symptoms; B=severe symptoms.
† 1=absence of immunosuppression; 2=moderate immunosuppression.

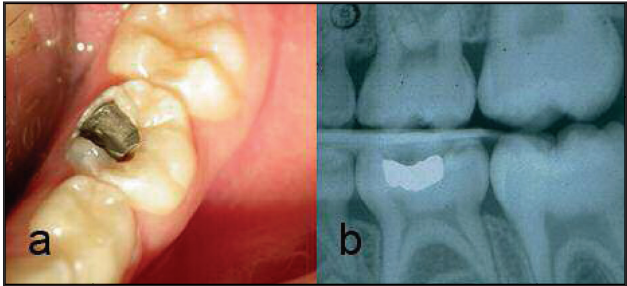


Figure 4a. Left primary mandibular tooth (no. K), with a fractured amalgam filling on the lingual and occlusal surfaces.
Figure 4b. Left bitewing radiograph with a radiolucid image under the restoration, suggesting secondary dentin carious lesion.

exposure and, consequently, early tooth extraction—since complete caries removal has been shown to increase the risk of pulp exposure.²⁰

In case 1, the patient presented at her oral examination only 1 decayed tooth with an extensive lesion in the dentin once her good oral hygiene and dietary habits could explain her low caries prevalence. It was then decided to treat the patient at the same appointment, using the ART technique¹⁵ to remove the carious lesion. Advantages of this technique include the ability to remove carious dentin without affecting the sound dentin, it is a preventive and restorative procedure that causes little discomfort, low cost, its ability to be used in field programs¹⁸, and its minimally invasive approach.²¹

The ART technique was compared with a more conventional treatment technique. This study's results show that the preparations with hand instruments resulted in smaller-sized cavities and, therefore, may be less traumatic to the tooth. It was also associated with less pain reactions compared to the more conventional technique.²² In the present case, ART allowed the patient's treatment in one session, preventing the carious lesion progression.

In case 2, the patient also revealed an extensive carious lesion of the second primary mandibular molar (tooth no. T), which was confirmed in the radiograph. It was then decided to use Carisolv¹⁷ for caries removal again to avoid pulp exposure. In contrast with conventional excavators and drills used for conventional excavation, carious dentin is removed using specially designed hand instruments, all of which reduce the risk of removing intact dentin. Another advantage of this technique is the elimination of local anesthesia in 80% of dental procedures.^{17,19,23} A review with Carisolv revealed a reduction in the number of vital pulp exposures, suggesting that traumatic exposure of the pulp does not occur once its solution does not remove the sound dentin.¹⁹

In case 3, the patient had a secondary carious lesion in her second primary mandibular tooth (no. K). Papacárie¹⁶ was chosen for caries removal because this procedure would avoid a possible pulp exposure rather than conventional techniques (high- and low-speed bur) and, therefore, would preserve the dental element in the oral cavity. One of the indications of this method is the removal of dentin carious preserving the surrounding dentin without local anesthesia, especially in deep carious lesions.¹⁸ All the indications were consonant with the present case.

The materials used in the chemomechanical techniques Carisolv and Papacárie had the same purpose, although they had different chemical compositions. Papacárie, however, has a lower cost in Brazil compared to Carisolv, making it a more convenient for dental care programs.

In the 3 case reports, the restorative material chosen was glass ionomer cement (Fuji-IX, GC Corp) due to its properties of chemical adhesion to enamel and dentin, biocompatibility, fluoride release to dental structures, saliva and biofilm, and reduction of caries progression when in contact with this material.²⁴⁻²⁶

All treatment plans achieved their objectives, as carious lesions were treated and all patients had their teeth preserved in the oral cavity. These techniques should be considered for use in children with systemic diseases as an alternative of conventional techniques (high- and low-speed bur), and they also fulfill the dental care demand of health dental programs. ART, Papacárie, and Carisolv have been currently used in the SIDA/AIDS project and can be used in field programs. The practice of preventive dentistry should, therefore, adopt more conservative and tooth-preserving procedures. More studies are needed, however, to compare alternative techniques with conventional procedures, in special-need patients.

REFERENCES

1. Eldridge K, Gallagher JE. Dental caries prevalence and dental health behavior in HIV infected children. *Int J Paediatr Dent* 2000;10:19-26.
2. Pongsiriwet S, Iamaroon A, Kanjanavanit S, Pattanaporn K, Krisanaprakornkit S. Oral lesions and dental caries status in perinatally HIV-infected children in Northern Thailand. *Int J Paediatr Dent* 2003;13:180-5.
3. Howell RB, Jandinski J, Palumbo P, Shey Z, Houpt M. Dental caries in HIV-infected children. *Pediatr Dent* 1992;14:370-1.
4. Castro GF, Portela MB, Esteves CC, Souza, IPR. Oral manifestations and their correlation with clinical/immunological classification in HIV+ children. *J Dent Res* 2000;79:480.
5. Flaitz C, Wullbrandt B, Sexton J, Bourdon T, Hicks J. Prevalence of orodental finding in HIV-infected Romanian children. *Pediatr Dent* 2001;23:44-5.
6. Howell RB, Houpt M. More than one factor can influence caries development in HIV-positive children. *Pediatr Dent* 1991;13:247.
7. Pierro VS, Abdelnur JP, Maia LC, Trugo LC. Free sugar concentration and pH of paediatric medicines in Brazil. *Community Dent Health* 2005;22:180-3.
8. American Dietetic Association. Position of the American Dietetic Association: Oral health and nutrition. *J Am Diet Assoc* 1996;96:184-9.
9. Greenspan D, Greenspan JS. Oral manifestations of human immunodeficiency virus infection. *Dent Clin North Am* 1993;37:21-32.
10. Fox PC. Salivary gland involvement in HIV-1 infection. *Oral Surg Oral Med Oral Pathol* 1992;73:168-70.
11. Mandel ID, Barr CE, Turgeon L. Longitudinal study of parotid saliva in HIV infection. *J Oral Pathol Med* 1992;21:209-13.
12. Madigan A, Murray PA, Houpt M, Cattallano F, Feuerman M. Caries experience and cariogenic markers in HIV- positive children and their siblings. *Pediatr Dent* 1996;18:129-36, 1996.

13. Castro GFBA, Souza IPR, Silva SLM, Stashenko, P, Teles, RP. Salivary IgA to cariogenic bacteria in HIV+ children and its correlation with caries prevalence and levels of cariogenic microorganisms. *Oral Microbiol Immunol* 2004;19:281-8.
14. Mc Donald RE, Avery DR. Restorative dentistry. In: Mc Donald RE, Avery DR, eds. *Dentistry for the Child and Adolescent*. 7th ed. St. Louis, Mo: Mosby Co; 2000:390.
15. Frencken JE. *Reports in the Execution of Mongoro Rotation in Primary Oral Health Care in the Academic Year 1984-1985*. Dar Es Salaam, Tanzania: University of Dar Es Salaam, Division of Dentistry; 1985.
16. Bussadori SK, Castro LC, Galvão AC. Papain gel: A new chemomechanical caries removal agent. *J Clin Pediatr Dent* 2005;30:115-9.
17. Ericson D, Zimmerman M, Raber H Götrick B, Bornstein R, Thorell J. Clinical Evaluation of efficacy and safety of a new method for chemomechanical removal of caries. *Caries Res* 1999;33:171-7.
18. Frencken JE, Pilot T, Songpaisan Y, Phantumvanit P. Atraumatic restorative treatment (ART): Rationale, technique, and development. *J Public Health Dent* 1996;56(spec issue no. 3):135-40, 161-3.
19. Maragakis GM, Hahn P, Hellwig E. Chemomechanical caries removal: A comprehensive review of the literature. *Int Dent J* 2001;51:291-9.
20. Ricketts DNJ, Kidd EAM, Innes N, Clarkson J. Complete or ultraconservative removal of decayed tissue in unfilled teeth. *Cochrane Database Syst Rev* 2006;19:3.
21. Tyas MJ, Anusavice KJ, Frencken JE, Mount GJ. Minimal intervention dentistry: A review. FDI commission project 1-97. *Int Dent J* 2000;50:1-12.
22. Rahimtoola S, van Amerongen E. Comparison of two tooth-saving preparation techniques for one-surface cavities. *J Dent Child* 2002;69:16-26.
23. Lozano-Chourio MA, Zambrano O, González H, Quero M. Clinical randomized controlled trial of chemomechanical caries removal (Carisolv). *Int J Paediatr Dent* 2006;16:161-7.
24. Creanor SL, Carruthers LM, Saunders WP, Strang R, Foye RH. Fluoride uptake and release characteristics of glass ionomer cements. *Caries Res* 1994;28:322-8.
25. Forss H, Seppa L. Prevention of enamel demineralization adjacent to glass ionomer filling materials. *Scand J Dent Res* 1990;98:173-8.
26. Hume WR, Mount G.J. In vitro studies on the potential for pulpal cytotoxicity of glass-ionomer cements. *J Dent Res* 1988;67:915-8.
27. Center for Disease Control and Prevention. 1994 revised classification system for human immunodeficiency virus infection in children less than 13 years of age. *MMWR Morb Mortal Wkly Rep* 1996;43:1-10.