

# Dentinogenesis Imperfecta: Long-term Rehabilitation in a Child

**Dominique Bouvier, DChD, PhD**      **Benoît Leheis, DDS**  
**Jean-Pierre Duprez, DDS, PhD**      **Elias Bittar, DChD**  
**Jean-Loup Coudert, DDS, PhD**

## ABSTRACT

The treatment of dentinogenesis imperfecta represents a challenge for the dental practitioner. The aim of this case report was to describe the chronology and problems encountered in the long-term rehabilitation of a young girl suffering from dentinogenesis imperfecta with severe attrition. A 2-stage treatment over a period of 9 years is described and discussed. This treatment comprised an initial treatment to restore esthetic appearance and function during primary and mixed dentitions and a complete prosthetic rehabilitation in a second stage to protect permanent teeth with low-fusion ceramic-metal individual crowns. Discovery of a follicular cyst is also reported and its treatment is described. (*J Dent Child* 2008;75:192-6)

Received March 13, 2007; Last Revision May 25, 2007; Revision Accepted May 29, 2007.

KEYWORDS: DENTINOGENESIS IMPERFECTA, CYSTS FOLLICULAR, CYSTS, CLINICAL REHABILITATION, DENTAL RESTORATIONS, CROWNS

The treatment of dentinogenesis imperfecta (DI) with severe attrition still remains a challenge for the dental practitioner because of the considerable loss of dental tissue encountered and the necessity to achieve functional and esthetic restoration, even at a very early age.

This hereditary affection is characterized by disturbed formation of dentin in both primary and permanent teeth in most cases.<sup>1</sup> Shields and al.<sup>1</sup> suggested a classification of DI into 3 types:

1. Type I (OMIM 166240) occurs with osteogenesis imperfecta and may be recessive.
2. Type II (OMIM 125490), also called hereditary opalescent dentin, is not associated with osteogenesis imperfecta and is one of the most common autosomal dominant inherited disorders in human beings.

3. Type III (OMIM 125500), the rarest, is found only in a triracial, inbred population in southern Maryland (Brandywine type) and is also an autosomal dominant disorder.

The prevalence for all types of DI is approximately 1 per 8,000.<sup>2</sup>

Histologically, the structure of the enamel and the cementum is reported to be normal. The characteristic scalloping at the dentoenamel junction is decreased or absent. This scalloping is supposed to provide mechanical interlocking between enamel and dentin. When the scalloping is missing, the enamel tends to crack within the enamel itself or along the dentoenamel junction.<sup>6</sup> In most cases, the mantle dentine presents a normal structure, whereas the dentinal tubules of the circumferential dentin are reduced in number and appear irregular in shape, size, and course. The number of odontoblasts is reduced. Pulpal inclusions and much hypomineralized interglobular dentin may be frequent.<sup>3</sup>

Clinically, the child's teeth have an abnormal brown, gray, or blue hue and appear opalescent under transmitted light. As soon as the primary teeth have erupted, the enamel often chips and fractures away. This occurs at the anterior teeth's incisal rim and on the posterior teeth's occlusal surfaces.

*Dr. Bouvier is associate professor, Dr. Benoît Leheis is assistant, and Dr. Duprez is associate professor, all the Department of Pediatric Dentistry, Faculty of Dentistry, University Lyon 1, University of Lyon, Lyon, France. Pediatric Dentistry Clinic, Hospices Civils de Lyon, Lyon France. Dr. Bittar is in private practice, Lyon, France; Dr. Coudert is professor, Department of Oral Surgery, Faculty of Dentistry, University Lyon 1, University of Lyon, Lyon, France. Oral Surgery Clinic, Hospices Civils de Lyon, Lyon, France. Correspond with Dr. Duprez at [duprezjeanpierre@numericable.fr](mailto:duprezjeanpierre@numericable.fr)*

The exposed dentin, which is poorly calcified, is rapidly subject to severe attrition. Periapical abscesses are common on primary teeth.<sup>7</sup> In some cases, permanent teeth seem to be less susceptible to the characteristic excessive attrition than primary teeth. The caries index is low in the patients with DI due to attrition, which makes the teeth smooth and self-cleaning. When caries occurs, it tends to spread laterally rather than invade.<sup>2,4</sup>

Radiographically, before attrition, the primary and permanent teeth have bulbous crowns with important cervical constrictions. The roots are short. In both primary and permanent dentition, complete obliteration of the pulp and root canals is a characteristic of DI.<sup>5,6</sup> When the child is very young, however, the pulp chambers of the primary teeth may be very wide, like “shell teeth.”<sup>7</sup> When the child is older and the permanent teeth are still immature, only the coronal segment may start obliteration. Periapical radiolucent areas may also be noted in the absence of any other dental pathology.<sup>8</sup>

Different dental approaches for managing DI with severe attrition have been suggested in the dental literature. In the past, most cases were left untreated until adolescence or adulthood, when all the teeth were extracted and complete dentures fitted. More recently, different strategies of treatment have been proposed—such as full coverage crowns, overdentures, or implants with removable prostheses.<sup>2,6,9</sup> The choice of the rehabilitation depends on the patient’s age at the beginning of the treatment and the severity of the attrition.<sup>6</sup> Intracoronal restorations such as composites are not recommended for DI with severe wear, but may be acceptable in mild cases with low attrition.<sup>7</sup>

The purpose of this article was to describe the chronology and problems encountered in the long-term rehabilitation of a young girl suffering from DI with severe attrition. A 2-stage treatment restoring esthetic and functional qualities is described and discussed.

## CASE REPORT

### CASE HISTORY

A 6-year-old girl suffering from DI was referred to the pediatric dentistry department, Hospices Civils, Lyon, France. Her aunt had been treated for the same affection in the department a few years previously.<sup>10</sup> The patient’s complaint was that she did not have teeth like her school friends. Her medical history revealed only common childhood diseases. The investigation of the family reported a diagnosis of DI, with severe attrition on both primary and permanent dentition, over at least 3 generations.

### FINDINGS

The oral examination (Figure 1) showed excessive attrition of her primary teeth and loss of vertical dimension. Primary maxillary lateral and right central incisors and the primary maxillary left first molar were absent. No dental caries or abscesses were noted on the remaining teeth. First permanent molars had just erupted and were not yet worn.

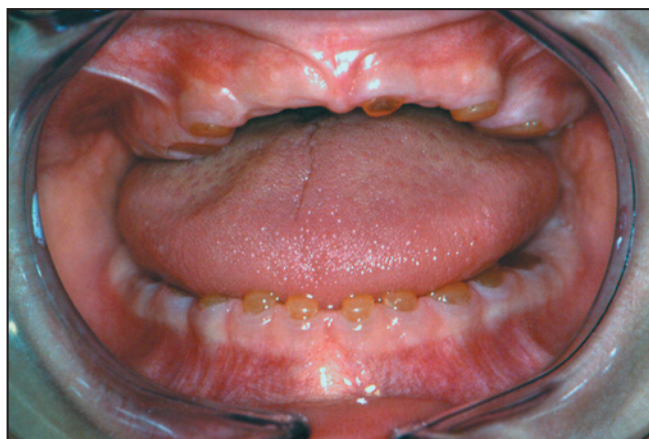

Figure 1. Clinical view of the dentinogenesis imperfecta patient.

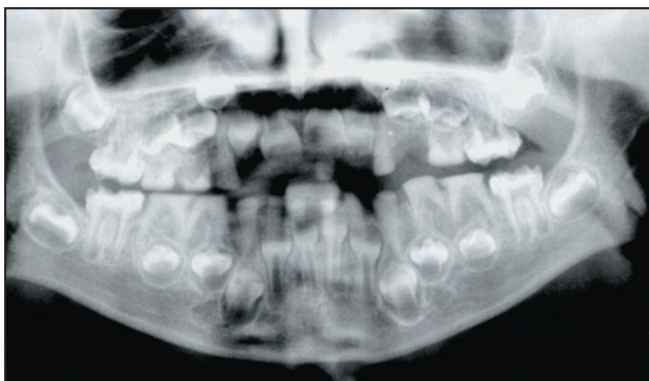


Figure 2. Panoramic radiograph of the patient.

Panoramic radiography revealed obliteration of the canals and absence of periapical pathology in primary teeth. Immature roots and bulbous crowns with cervical constrictions were evident in permanent first molars (Figure 2).

## MANAGEMENT

The treatment was planned in 2 stages:

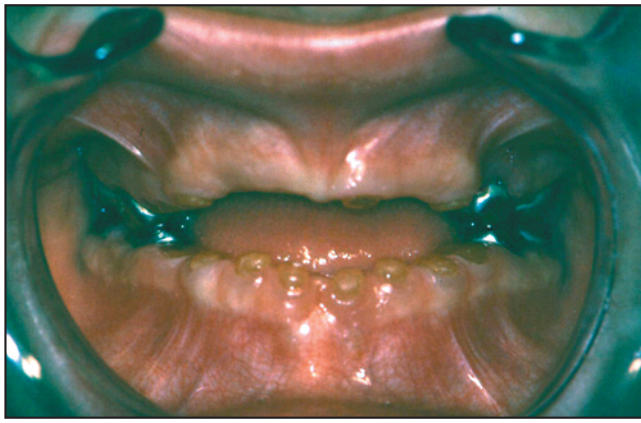1. an initial phase during primary and mixed dentitions; and
2. a long-term prosthetic rehabilitation in the permanent dentition.

### INITIAL TREATMENT

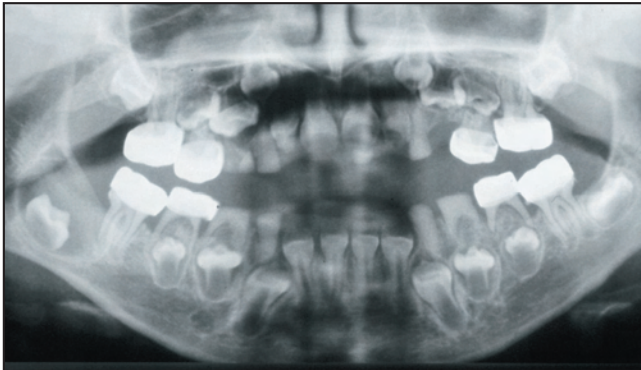
The first step consisted in fitting stainless steel crowns (preformed metal crowns, 3M ESPE, St. Paul, Minn) on primary second molars and permanent first molars to increase vertical dimension and protect first permanent molars against attrition. Subgingival preparation was required to increase the clinical crown’s length, and only minimal preparation of the occlusal surfaces was undertaken (Figure 3). The crowns were cemented with glass ionomer cement (Fuji I, GC, Tokyo, Japan). The patient was examined at regular intervals to check for eruption of the incisors and signs of functional disorder due to the new occlusion.

One year after the first appointment, a follicular cyst associated with the permanent mandibular right second

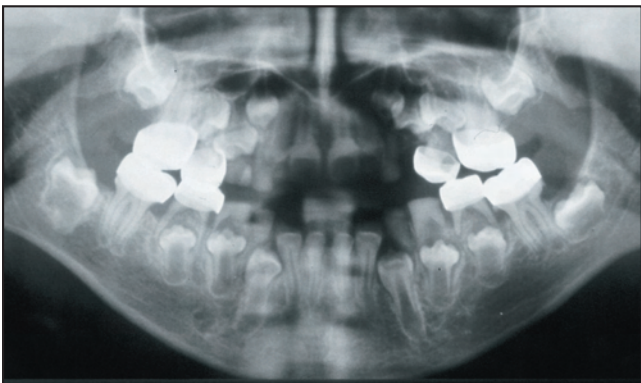



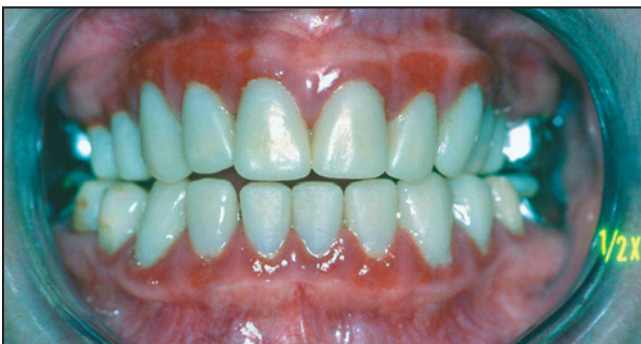**Figure 3.** View of the new vertical dimension with stainless steel crowns on primary second molars and permanent first teeth.



**Figure 4.** Follicular cyst associated with permanent mandibular right second molar germ.



**Figure 5.** Disappear of the cyst and earlier eruption of permanent mandibular right second molar.



**Figure 6.** Appearance of the patient with completed temporary restorations after the initial treatment.

molar germ was diagnosed on a radiology control (Figure 4). Marsupialization of the cyst was undertaken, and the cyst was then packed with iodoform gauze (Ercemeche, Péters Surgical, Bobigny, France), which was renewed over a period of 2 months. Six months later, the cyst had disappeared entirely, a complete generation of the bone structures was seen (Figure 5), and the right second molar had erupted precociously. Shortly after the eruption of the lower and upper incisors, polycarbonate resin restorations (Ion, 3M ESPE) were fitted onto these teeth before attrition began.

All the remaining permanent teeth were crowned immediately after eruption either with polycarbonate resin crowns (premolars and canines) or with stainless steel crowns (second molars). This treatment made it possible to reduce the wear of teeth as they erupted and to permit the establishment of a full permanent dentition.

This first stage lasted 8½ years. During this long period, the patient was monitored at 3-month intervals to check for any esthetic or functional problems and was encouraged to use the oral hygiene procedure established for her at home. New polycarbonate crowns were fitted on the incisors, and mandibular third molar germs were extracted. The only clinical sign during this stage was some gingival inflammation caused by the subgingival preparation (Figures 6 and 7).

## SECOND STAGE

When the child was 14½ years old, she was admitted for long-term prosthetic rehabilitation. The bone growth stage was reached 14 months earlier, and maxillary growth was stable. The provisional restorations were removed, and tooth preparations were completed for individual low-fusion ceramic-metal crowns. Occlusal registrations were obtained with wax wedges (Moyco Industries Inc, Philadelphia, Pa), maintaining the vertical dimension of the provisional restorations. Final impressions were obtained with individual copings filled with syringed impression material (Express, 3M ESPE) and placed on the prepared teeth. Individual trays were filled with medium consistency impression material (Express, 3M ESPE) and placed on the complete set of copings. From these impressions, working casts were mounted on a semi-adjustable articulator according to the records obtained.

A precious alloy (Degunorm, Degussa AG, Hanau, Germany) was used for producing 28 individual frameworks for ceramic-metal crowns. The frameworks were tried in the patient's mouth to check the marginal fit and centric relation position (Figure 8). The low-fusion ceramic (Ducera, Degussa AG) was then applied to produce 24 full-coverage crowns on incisors, canines, premolars, and lower molars. Both first and second upper molars were fitted with ceramic crowns with metal occlusal surfaces. The crowns were cemented with glass ionomer cement (Fuji I, GC America, Inc, Alsip, Ill). Recall visits were scheduled every 3 months during the first year. One year later, clinical and radiographic control revealed only little inflammation around the anterior teeth crowns (Figures 9 and 10).

## DISCUSSION

DI is a hereditary abnormality which can have different clinical manifestations: DI with excessive and rapid attrition on both primary and permanent teeth, and mild DI with little or no attrition on the permanent teeth.<sup>10</sup> In both types, the primary dentition appears more severely affected by attrition than the permanent dentition.<sup>7</sup> It is essential that children suffering for DI be admitted into an early treatment in order to halt attrition, which causes functional disorders. This early treatment also helps solve esthetic problems that are often the cause of psychological difficulty for the child, which can result in reluctance to integrate society.

It is of the utmost importance to diagnose DI as early as possible and to cover deciduous teeth before they undergo severe and rapid attrition. Sapir et al<sup>7</sup> study a case of an 18-month-old DI patient undergoing treatment under general anesthesia and point out both the advantages and the drawbacks of early DI treatment.

When the child is examined after the eruption of the deciduous teeth, the teeth have inevitably undergone attrition as in the patient described in this article. This first stage of treatment's initial objective was to increase the vertical dimension of the teeth by crowning the primary molars, which would enable the permanent teeth to erupt without undergoing early attrition. If root resorption of the primary incisors and canines has not gone too far, it is also

possible to restore these deciduous teeth using composite<sup>13</sup> or pedomorphic strip crowns<sup>7</sup> to improve the esthetics. In mixed dentition, it is also necessary to cover the permanent teeth as soon as they enter into occlusion, so as to prevent them from attrition. This treatment is long and complex. Patient collaboration and parent compliance are factors of success in the restoration. The dentist may, in some cases, resort to conscious sedation if the child is anxious or to general anesthesia if the child is too young.<sup>7,13</sup>

By this initial treatment, it is possible to reduce the wear of teeth as they erupt and ensure the integrity of the full permanent dentition until adolescence when prosthetic rehabilitation can be undertaken.

The purpose of this second stage, which begins when maxillary growth is stable, is to establish esthetic appearance and efficient masticatory functions. Actually, full coverage crowns are usually the preferred restorations for these young patients.<sup>6,10</sup>

In this case, a follicular cyst had appeared on the mandibular right second molar germ. Despite the DI, this follicular cyst healed after marsupialization treatment and the tooth was able to erupt normally. In one case in the dental literature, a mandibular cyst associated with DI type I is described.<sup>15</sup>

Radiolucencies in the permanent teeth are also mentioned in the dental literature in the absence of any other

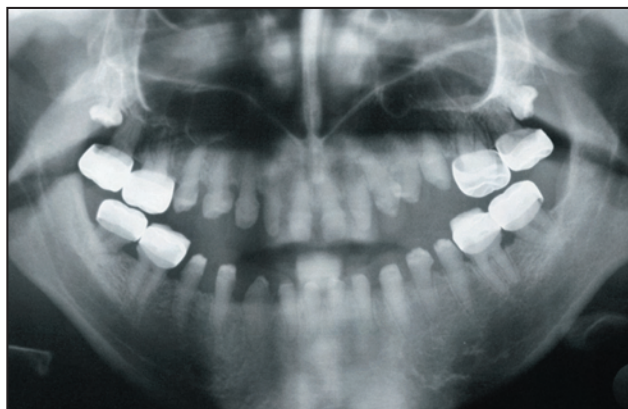

Figure 7. Panoramic radiograph at the end of the initial treatment.

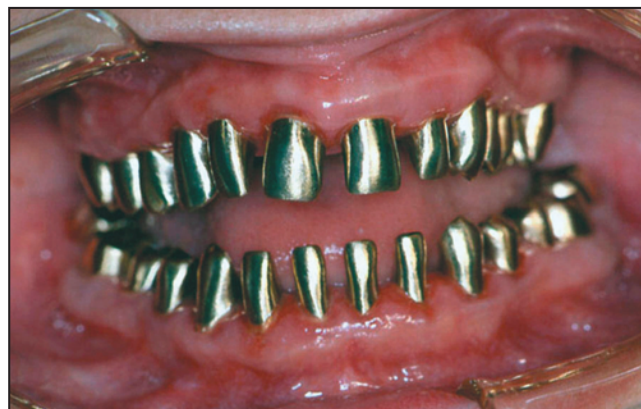

Figure 8. Metal framework adjusted in the mouth.

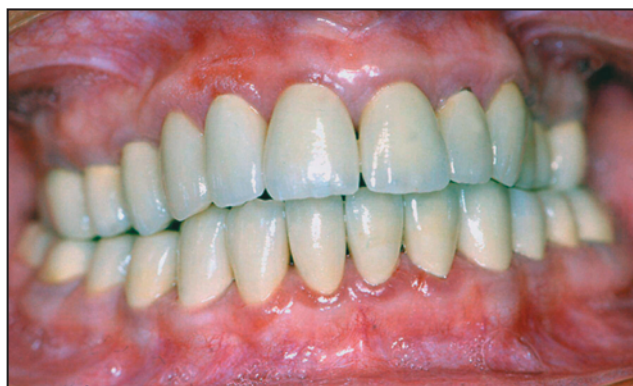

Figure 9. Clinical view of the patient with prosthetic crowns 1 year later.

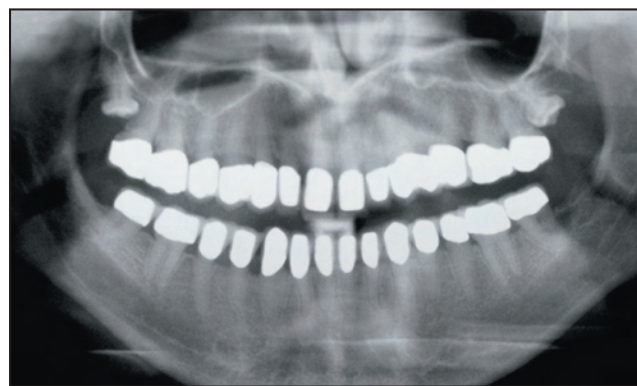

Figure 10. Panoramic radiograph 1 year later.



dental pathology.<sup>8,16</sup> These periapical lesions seem to appear on the first molars, despite complete pulpal obliteration.<sup>5,10</sup> Several hypotheses could be suggested: pulpal strangulation could have occurred secondarily to pulpal obliteration, but all the teeth would be affected; or overpressure on these molars existed, resulting from excessive occlusal function over a long period of time due to rapid attrition of the primary teeth.

Because of complete obliteration, endodontic treatment has a very poor prognosis and most teeth with such radiolucencies have to be extracted.<sup>5,10</sup> Early restoration of the vertical dimension, together with the fitting of crowns on the deciduous and permanent teeth, apparently avoids the appearance of apical lesions on the permanent molars. Moreover, the use of more malleable materials than ceramics such as precious metal alloy or low-fusion ceramic provides a lower hardness factor on the occlusal surfaces and may decrease the risk of overpressure on these teeth.<sup>6</sup>

## CONCLUSIONS

Complete restoration of DI is a long and complex process requiring a carefully established protocol for both the initial treatment and the long-term prosthetic phase, generally extending over several years. Thanks to the evolution of materials and methods, even very young children can now benefit from fixed prostheses, conserve their "dental capital," and attain adulthood without the major problems traditionally resulting from dentinogenesis imperfecta.

## REFERENCES

1. Shields ED, Bixler D, el-Kafrawy AM. A proposal classification for heritable human dentin defects with a description of a new entity. *Arch Oral Biol* 1973;18:543-53.
2. Darendeliler-Kaba A, Marechaux SC. Hereditary dentinogenesis imperfecta: A treatment program using an overdenture. *J Dent Child* 1992;59:273-6.
3. Wright JT, Gantt DG. The ultrastructure of the dental tissues in dentinogenesis imperfecta in man. *Arch Oral Biol* 1985;30:201-6.
4. Modesto A, Alves AC, Vieira AR, Portella W. Dentinogenesis imperfecta Type II: Case report. *Braz Dent J* 1996;7:47-52.
5. Pettiette MT, Wright JT, Trope M, Hill C. Dentinogenesis imperfecta: Endodontic implications. Case Report. *Oral Surg Oral Med Oral Radiol Endod* 1998;86:733-7.
6. Moundouri-Andritsakakis H, Kourtis SG, Andritsakakis DP. All-ceramic restorations for complete-mouth rehabilitation in dentinogenesis imperfecta: A case report. *Quintessence Int* 2002;33:656-60.
7. Sapir S, Shapira J. Dentinogenesis imperfecta: An early strategy. *Pediatr Dent* 2001;23:232-7.
8. Gage JP, Symons AL, Romaniuk K, Daley TJ. Hereditary opalescent dentine: Variation in expression. *J Dent Child* 1991;58:134-9.
9. Cehreli ZC, Altay N. Dentinogenesis imperfecta: Influence of an overdenture on gingival tissues and tooth mobility. *J Clin Pediatr Dent* 1996;20:277-80.
10. Bouvier D, Duprez JP, Morrier JJ, Bois D. Strategies for rehabilitation in the treatment of dentinogenesis imperfecta in a child: A clinical report. *J Prosthet Dent* 1996;75:238-41.
11. Komorowska A, Rozynkowska D, Lee KW, Renouf DV, Nicholls AC, Mackenzie J, Pope FM. A Polish variant of isolated dentinogenesis imperfecta with a generalised connective tissue defect. *Br Dent J* 1989;167:239-43.
12. MacDonald RE, Avery DR. *Dentistry for the Child and Adolescent*. 6<sup>th</sup> ed. St. Louis, Mo: Mosby Co.; 1994:131-233.
13. Huth KCh, Pashos E, Sagner T, Hickel R. Diagnostic features and pedodontic-orthodontic management in dentinogenesis imperfecta type II: A case report. *Int J Paediatr Dent* 2002;12:316-21.
14. Stephen, LXG, Beighton P. Dental management of severe dentinogenesis imperfecta in a mild form of osteogenesis imperfecta. *J Clin Pediatr Dent* 2002;26:131-6.
15. Vorast H, Howaldt HP, Wetzel WE. The treatment of mandibular cysts associated with osteogenesis imperfecta. *J Dent Child* 2000;67:64-6.
16. Mac Dougall M. Refined mapping of the human sialo-phosphoprotein (DSPP) gene within the critical dentinogenesis imperfecta type II and dentin dysplasia type II loci. *Eur J Oral Sci* 1998;106:227-33.