

The Effect of Vertical and Horizontal Head Positioning in Panoramic Radiography on Mesiodistal Tooth Angulations

Ian W. Mckee, DDS, MSc^a; Kenneth E. Glover, DDS, MSD^b; Philip C. Williamson, DDS, MSc^c; Ernest W. Lam, DMD, PhD^d; Giseon Heo, BSc, PhD^e; Paul W. Major, DDS, MSc^f

Abstract: The purposes of this study were to examine the effect of potentially common patient positioning errors in panoramic radiography on imaged mesiodistal tooth angulations and to compare these results with the imaged mesiodistal tooth angulations present at an idealized head position. A human skull served as the matrix into which a constructed typodont testing device was fixed according to anteroposterior and vertical cephalometric normals. The skull was then repeatedly imaged and repositioned five times at each of the following five head positions: ideal head position, 5° right, 5° left, 5° up, and 5° down. The images were scanned and digitized with custom software to determine the image mesiodistal tooth angulations. Results revealed that the majority of image angles from the five head positions were statistically significantly different than image angles from the idealized head position. Maxillary teeth were more sensitive to 5° up/down head rotation, with 5° up causing mesial projection and 5° down causing distal projection of maxillary roots. Mandibular anterior teeth were more sensitive to 5° right/left head rotation, with the projected mesiodistal angular difference between 5° right and 5° left rotation ranging from 4.0° to 22.3°. Maxillary teeth were relatively unaffected by 5° right/left head rotation, and mandibular teeth were relatively unaffected by 5° up/down head rotation. It was concluded that the clinical assessment of mesiodistal tooth angulation with panoramic radiography should be approached with extreme caution with an understanding of the inherent image distortions that can be further complicated by the potential for aberrant head positioning. (*Angle Orthod* 2001;71:442–451.)

Key Words: Axial inclination; Root parallelism; Head rotation; Patient positioning

INTRODUCTION

Orthodontists critically evaluate crown and root position before, during, and after orthodontic treatment in the pursuit of excellence of the occlusal result. Whereas this assess-

ment is often performed clinically, panoramic radiography is frequently used to visualize root parallelism and mesiodistal tooth angulation.^{1–3}

In his well-known study, Andrews⁴ stated that normal occlusion is dependant on, among other factors, the correct mesiodistal inclination (or tip). Other investigators have found that appropriate axial inclinations and root parallelism are important for proper occlusal and incisal function of the teeth and are an important component in maintaining a stable treatment result.^{1,5–10} This has special significance in the orthodontic extraction case, where extraction sites are prone to open if roots are insufficiently paralleled.^{5,7,10}

Although panoramic radiography offers numerous diagnostic and prognostic uses in orthodontic diagnosis and treatment planning, the machinery produces images with variable magnification factors (both horizontal and vertical), resulting in angular distortion.¹¹ Various investigators have studied panoramic image generation in an attempt to quantify the dimensional accuracy of the images.^{2,3,12–40}

Although convenient to make, the panoramic radiograph is extremely technique and operator sensitive. Schiff et al²² reported that the most frequent errors in panoramic radiography occurred in patient positioning. In a study of 1000 panoramic films, the relative frequency of positioning errors

^a Senior Orthodontic Resident, Division of Orthodontics, Faculty of Medicine and Dentistry, University of Alberta, Edmonton, Alberta, Canada.

^b Professor and Chairman, Division of Orthodontics, Faculty of Medicine and Dentistry, University of Alberta, Edmonton, Alberta, Canada.

^c Clinical Assistant Professor, Division of Orthodontics, University of Alberta, Edmonton, Alberta, Canada.

^d Associate Professor, Division of Radiology, Faculty of Medicine and Dentistry, University of Alberta, Edmonton, Alberta, Canada.

^e Faculty Lecturer, Department of Mathematical Sciences, Faculty of Science, University of Alberta, Edmonton, Alberta, Canada.

^f Professor, Division of Orthodontics, Faculty of Medicine and Dentistry, University of Alberta, Edmonton, Alberta, Canada.

Corresponding author: Dr Paul Major, Faculty of Medicine and Dentistry, Room 1043, Dentistry/Pharmacy Center, University of Alberta, Edmonton, Alberta, Canada T6G 2N8 (e-mail: major@ualberta.ca).

Based on a thesis submitted by Dr Mckee in partial fulfillment of the degree of Master's of Science, Division of Orthodontics, Faculty of Medicine and Dentistry, University of Alberta, Edmonton, Alberta, Canada.

Accepted: March 2001. Submitted: January 2001.

© 2001 by The EH Angle Education and Research Foundation, Inc.

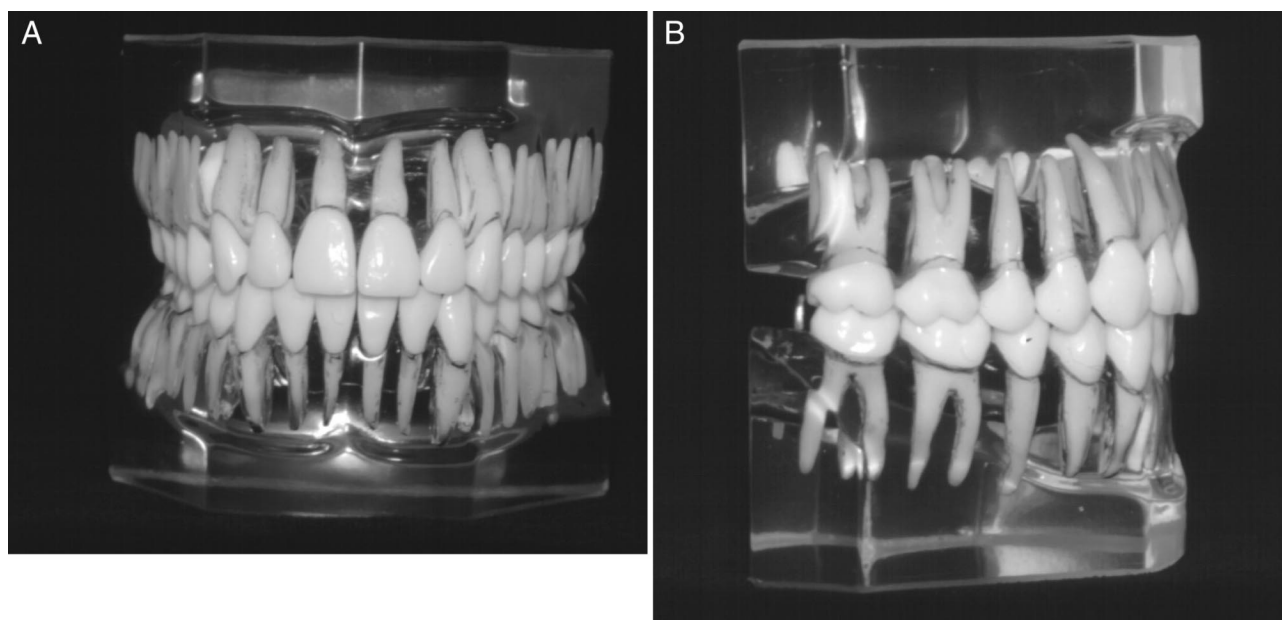


FIGURE 1. Initial typodont testing device.

was as follows: 14% chin too low, 4% head tilted, 4% head turned, and 1% chin too high.²² In conventional panoramic radiography, the image layer is significantly narrower in the anterior region, and blurring and distortion are least in the center of the image layer.^{18,24,25,27,29,39} Failure to position the patient's dental arches accurately causes variation in both vertical and horizontal magnification, resulting in angular distortion of the image.²⁵ Investigations into the effect of vertical and horizontal rotation of a skull or testing device on angular measurements revealed that the canine/premolar region of both arches expressed the largest amount of distortion.^{17,38} Xie et al⁴⁰ assessed the accuracy of vertical measurements taken from panoramic radiographs. They recommended selecting a horizontal reference line that is located anatomically directly above or below the point being measured and in the plane of the center of the image layer, rather than a reference plane distant from the site of measurement.⁴⁰

Considering that the inherent dimensional inaccuracy of panoramic images is compounded by the variability of patient positioning, it seems reasonable to believe that the assessment of mesiodistal angulations of teeth cannot be reliably performed on panoramic films. The purposes of this study were to examine the effects of varying horizontal and vertical head rotations of an anatomic typodont/skull testing device on image mesiodistal angulations from the Orthopantomograph (OP 100; Instrumentarium, Munich, Germany) and to compare these findings to the image mesiodistal angulations from an idealized head position.

MATERIALS AND METHODS

Test device design

The test device consisted of a clear anatomic maxillary and mandibular typodont (Ormco Corporation, Orange, Ca-

lif) with an idealized occlusion from second molar to second molar (Figure 1). For each tooth, two chromium steel balls (Commercial Bearing, Edmonton, Alberta, Canada) measuring 1.58 mm in diameter were glued into position following preparation with a #2 round bur. The occlusal ball was placed in the buccolingual and mesiodistal midpoint of the crown on the occlusal/incisal surface, whereas the placement of the apical ball into the root surface depended on the tooth being prepared. Excluding maxillary and mandibular first and second molars and maxillary first bicusps, the apical ball was placed into the buccolingual and mesiodistal midpoint of the root in the apical third. For teeth displaying dilaceration in the apical third, the apical dilaceration was removed with a diamond disc to remove the effect of dilaceration on long axis determination. For the remaining teeth, the apical ball was placed in the center of the bifurcation/trifurcation. These steel balls served as reference markers for image angle determination, and an imaginary line joining the centers of the occlusal and apical balls was used to represent the long axis of each typodont tooth.

The maxillary and mandibular typodont was then bonded with 0.022-inch-slot clear orthodontic brackets (Spirit, Ormco Corporation) to idealized bracket positions, and a passive 0.020-inch round stainless steel archwire (Permachrome resilient/Orthoform III, 3M Unitek, Monrovia, Calif) was ligated into position with elastomeric modules (Figure 2).

Typodont positioning into skull

A dried adult human skull with complete natural dentition and class I skeletal and dental relation served as the

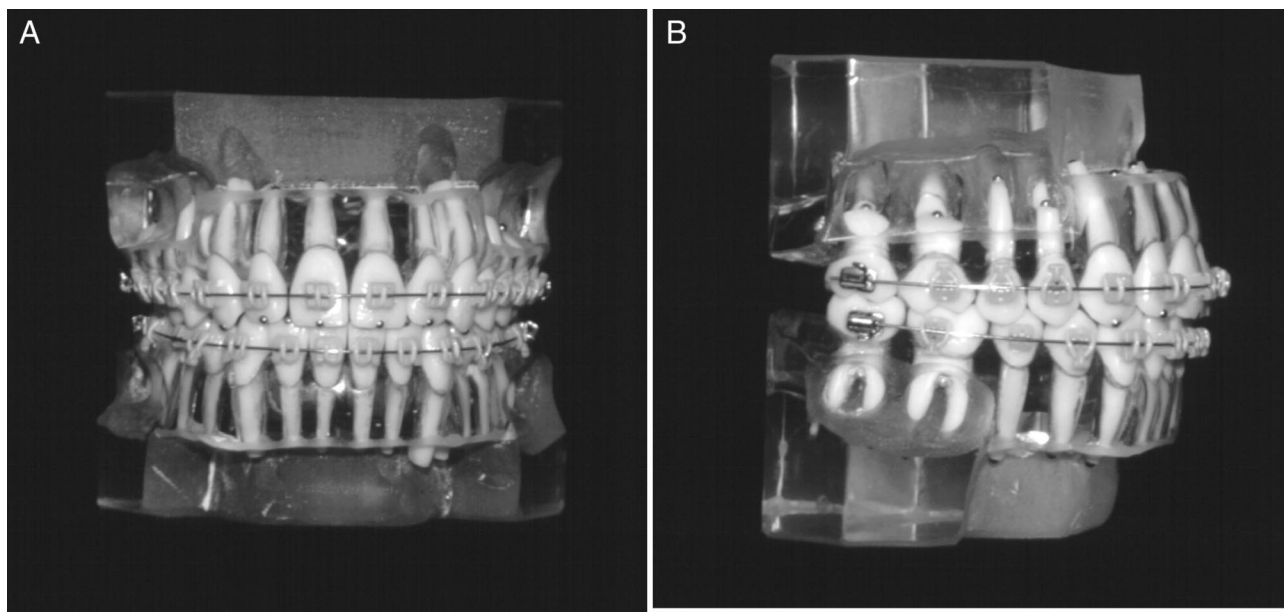


FIGURE 2. Modified typodont testing device.

matrix into which the typodont dentition was fixed for subsequent panoramic imaging (Figure 3).

The glenoid fossa was remodeled with cold-cure acrylic resin to provide positive seating of the condyle. This ensured reproducible mandibular opening/closing and a stable centric occlusion supported by both typodont tooth intercuspation and condyle/glenoid fossa fit. Chromium steel balls measuring 1.58 mm in diameter were fixed to the skull at the following positions to confirm that the vertical, anteroposterior, and transverse positions of the typodont dentition conformed to pre-established norms:

1. Nasion—the junction of the nasal and frontal bones at the most posterior point on the curvature of the bridge of the nose.
2. Right and left anatomic porion—the most superior point of the external auditory canal (anatomic porion).
3. Pogonion—the most anterior point on the contour of the chin.

The natural maxillary dentition, supporting bone, and portions of the skeletal maxilla were removed, and the maxillary typodont dentition was temporarily wired into place with ligature wires. Multiple anthropometric, lateral, and postero-anterior (PA) cephalometric measurements were made with subsequent movements of the maxillary typodont until the following positions were obtained:

1. Transverse—bisection of the midpoint of the incisal steel balls on typodont teeth #11 and 21 with a line joining the steel balls placed at nasion and pogonion (measured on PA cephalometric image).
2. Anteroposterior—nasion perpendicular to Frankfort horizontal (PoOr) to upper incisor edge = 5 mm (measured

on lateral cephalometric image). (Modification of the McNamara analysis measurements was calculated by adding the 14-year-old norm for nasion perpendicular to Frankfort horizontal to A-point (3.8 mm) to the 14-year-old norm for A-point parallel to nasion perpendicular to Frankfort horizontal to facial surface of upper incisor (1.2 mm); total distance nasion perpendicular to Frankfort horizontal to facial surface of upper incisor = 5 mm.

3. Vertical

- a. Nasion to maxillary central incisor edge = 76 mm (linear distance measured on skull).
- b. Occlusal plane cant to Frankfort horizontal (PoOr) to occlusal plane = 9° (measured on lateral cephalometric image).

The maxillary typodont was then rigidly fixed to the skull

The position of the mandibular typodont dentition in all three planes of space was determined by its centric occlusion articulation with the maxillary typodont. The dental relationship of the articulated typodont was a fully interdigitated class I molar and cuspid relation with 2-mm overjet, 2-mm overbite, and coincident dental midlines. The mandibular typodont dentition was firmly ligature-tied to the maxillary typodont dentition, and the natural mandibular dentition, supporting bone, and portions of the skeletal mandible were removed. The skeletal mandible was then rotated upward (ensuring full seating of the condyle in the glenoid fossa) until the pre-existing vertical dimension of the skull was achieved (distance nasion to pogonion = 108 mm). The mandibular typodont was then rigidly fixed to

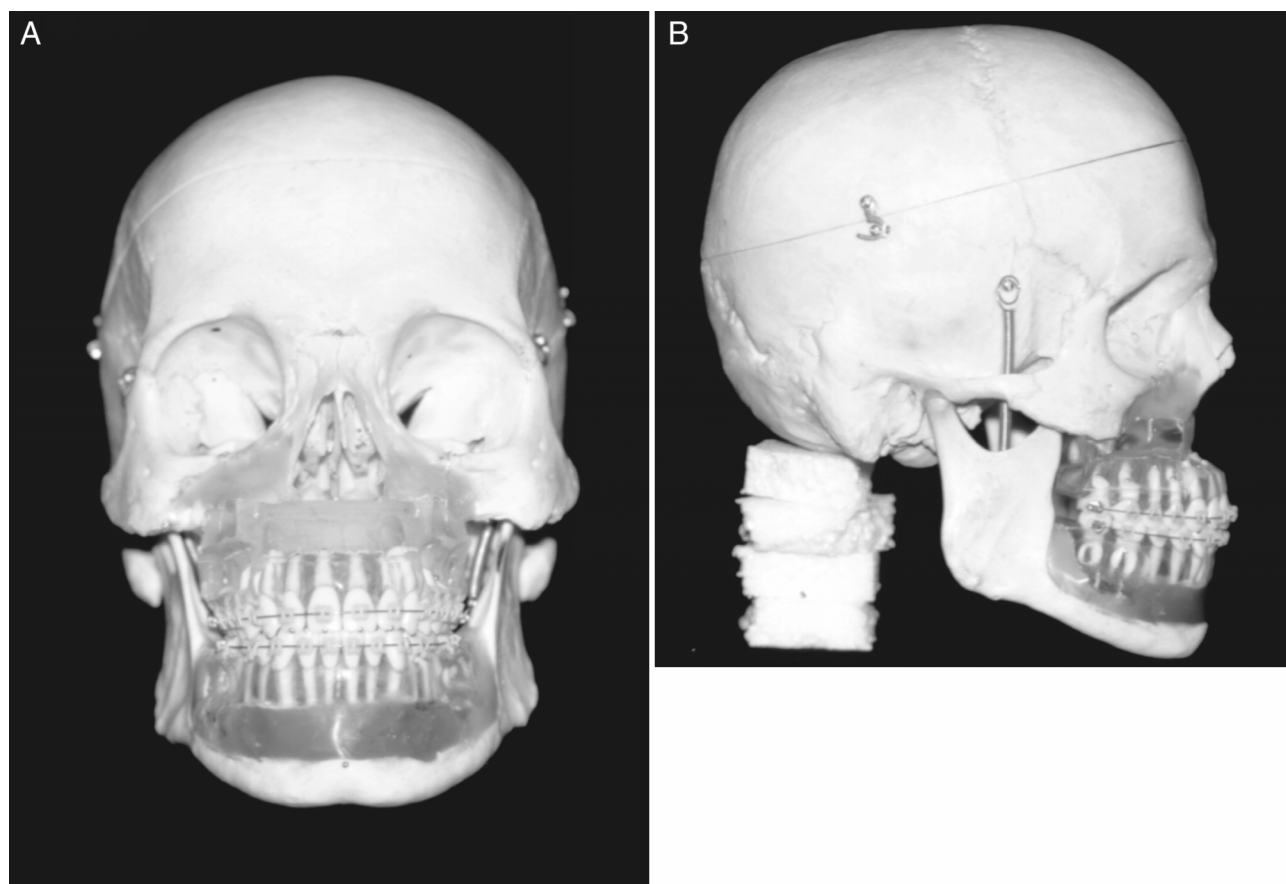


FIGURE 3. Typodont/skull testing device.

the skeletal mandible, and the intermaxillary ligature wires were released. Lateral and PA cephalometric analyses of the finalized movements revealed attainment of positioning goals and a remarkably “normal” dental-to-skeletal and dental-to-dental relation as shown:

1. Upper incisor to Frankfort horizontal (PoOr) = 108° .
2. Lower incisor to mandibular plane (GoMe) = 94° .
3. Interincisal angle = 132° .

Head holder

A custom-designed radiolucent head holder (Mechanical Engineering, University of Alberta, Edmonton, Alberta, Canada) was constructed to ensure the validity of the horizontal and vertical head rotation about a reproducible axis of rotation (Figure 4). The head holder consisted of three components:

1. Hollow cylinder—permanently attached to the exterior surface of the skull at foramen magnum.
2. Solid cylinder—precision-machined end attached into hollow cylinder and connected at its base via internal screw threads to the mounting screw on the camera tripod.

3. Camera tripod—fully adjustable vertical and horizontal controls.

Panoramic radiographs

The skull and head holder assembly was positioned into an Orthopantomograph OP 100 at five separate times at each of the following five head positions and exposed:

1. Ideal position: 0° horizontal rotation, 0° vertical rotation.
2. 5° right: 5° “right” horizontal rotation, 0° vertical rotation.
3. 5° left: 5° “left” horizontal rotation, 0° vertical rotation.
4. 5° up: 0° horizontal rotation, 5° “head up” vertical rotation.
5. 5° down: 0° horizontal rotation, 5° “head down” vertical rotation.

Optimum image density and contrast was achieved at exposure settings of 57 KVP, 2.0 mA, and 17.6 seconds. The object was to position the skull to simulate the desired position of the patient’s head in the panoramic unit and to represent common patient positioning errors (Figure 5). For the idealized head position, the Frankfort horizontal was aligned with the horizontal light guide, the midsagittal plane was aligned with the vertical light guide, and the

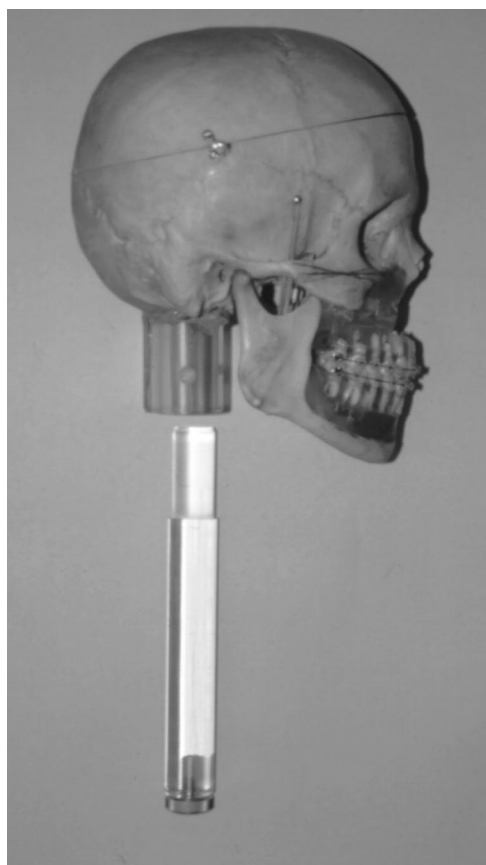


FIGURE 4. Skull and head holder.

incisal edges of the maxillary and mandibular incisors were placed into the notched bite block. For the horizontal (right and left) rotations, markings placed on the frontal bone of the skull at 5° “right” and 5° “left” assisted in alignment with the panoramic unit’s vertical light guide while keeping the Frankfort horizontal aligned with the horizontal light guide. For the vertical (up and down) rotations, markings placed on the lateral surface of the skull at 5° “head up” and 5° “head down” assisted in alignment with the panoramic unit’s horizontal light guide while keeping the midsagittal plane aligned with the vertical light guide.

The combined head holder and tripod assembly ensured that the right and left rotation occurred about the center of foramen magnum (ie, vertical axis of rotation) and that the up and down rotation occurred about the incisal edges of the maxillary and mandibular incisors and bite block assembly (ie, horizontal axis of rotation).

Image angle determination

Custom-designed software (Mechanical Engineering, University of Alberta) was utilized to calculate the mesiodistal angulation of the typodont teeth relative to the reference archwire from the 25 panoramic images. The radiographs were scanned with a resolution of 600 dpi and magnification of 200% (Hewlett Packard Scan Jet 6100 C/T,

Palo Alto, Calif, Hewlett Packard Desk Scan II, Palo Alto, Calif, Corel Photopaint 6.0 Ottawa, ON, Canada, Crusher-soft Software, Edmonton, AB, Canada) on a Dell Dimension XPS D433 PII IBM-compatible PC. The order of landmark identification was standardized for all radiographs and involved the following 4 points for each tooth angle determination:

1. T^C (tooth crown): the center of the occlusal steel ball.
2. T^R (tooth root): the center of the apical/furcal steel ball.
3. W^D (wire distal): intersection of a computer-generated vertical midpoint between adjacent teeth (on the distal side of the tooth being measured) and the image of the reference archwire.
4. W^M (wire mesial): intersection of a computer-generated vertical midpoint between adjacent teeth (on the mesial side of the tooth being measured) and the image of the reference archwire.

Upon completion of digitization of each panoramic image, the program generated an Excel spreadsheet of the image mesiodistal angulation (determined as the angle formed by lines constructed between the reference points T^C and T^R and between W^D and W^M) for the 24 teeth.

Error of the method and statistical analysis

The principal investigator undertook all typodont/skull modifications, skull positioning, and image angle measurements.

The total error of each image angle measurement was a combination of the error of measurement (ie, digitization) and the error of repeated head positioning for each of the five head positions. To determine the error of digitization, one of the 25 images was randomly selected, and each tooth was digitized five consecutive times. The error of digitization ranged from 0.45° to 0.86°. The average total error and standard deviation for each head position’s image angle measurements were as follows: ideal, 0.96° (0.57°); 5° right, 1.32° (1.03°); 5° left, 1.38° (0.97°); 5° up, 0.99° (0.47°); 5° down, 2.28° (3.05°).

Paired *t*-tests were completed for each tooth to detect angular differences between the idealized head position and each of the four head positions (5° right, 5° left, 5° up, and 5° down). Significance levels of less than .05 were considered to be statistically significant.

RESULTS

The mean and standard deviation values for the image mesiodistal angulations for all 24 teeth are presented in Table 1. Paired *t*-tests comparing the idealized head position individually to 5° right, 5° left, 5° up, and 5° down head positions are presented in Table 2.

The majority of maxillary and mandibular image angles (64%) from the 4 head positions were statistically significantly different from image angles from the idealized head

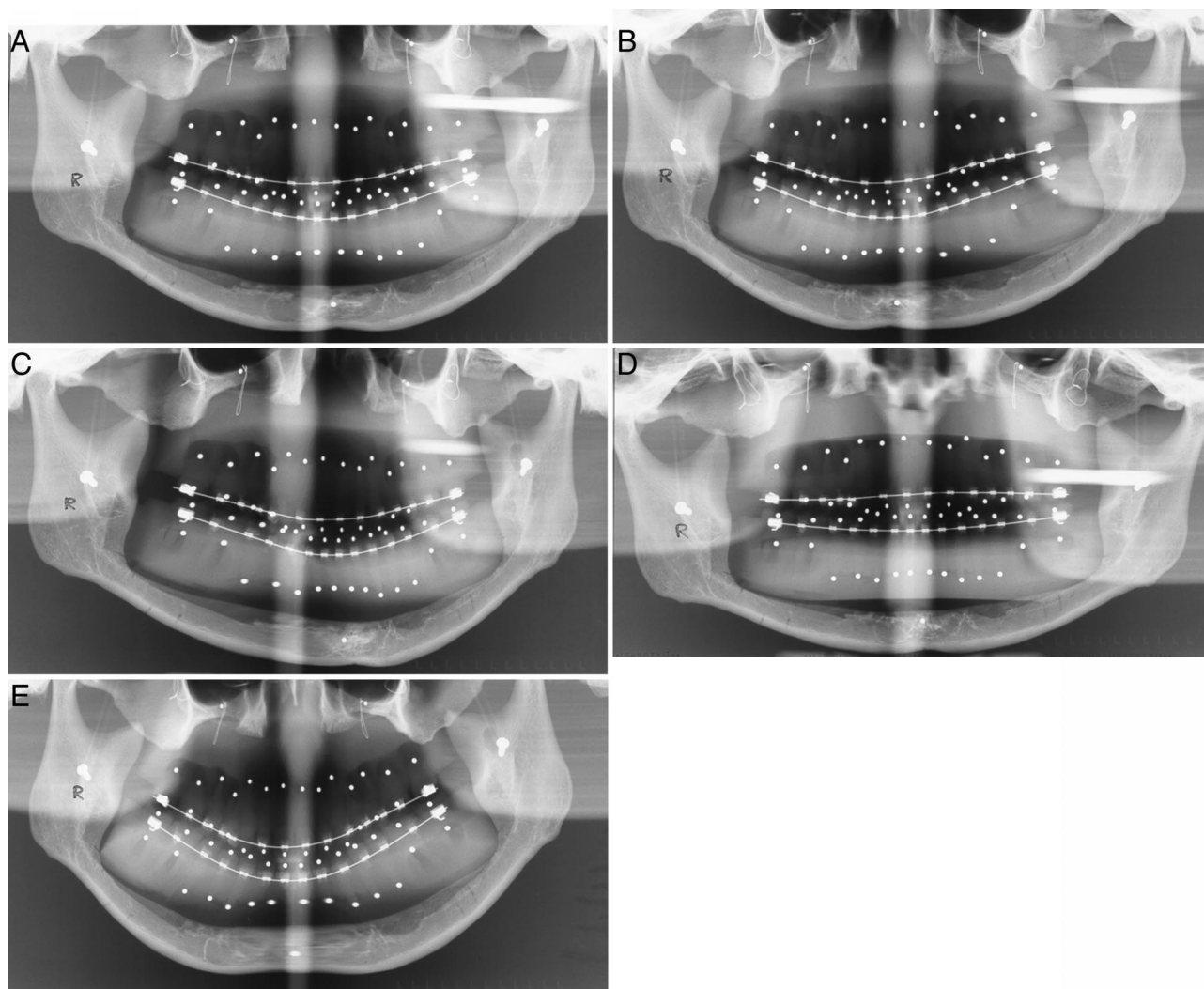


FIGURE 5. Panoramic images from the Orthopantomograph OP 100 at each of the 5 head positions. (A) Ideal head position. (B) 5° right. (C) 5° left. (D) 5° up. (E) 5° down.

position. Examination of Figures 6 and 7 reveals a common pattern between the varying head positions. For the maxillary teeth, 5° up and 5° down head rotations had a much more pronounced effect on deviations from idealized head position than did 5° right and 5° left head rotations. Whereas 5° up resulted in a mesial projection of all maxillary roots (teeth #11 and 21 remained unchanged), 5° head down resulted in a distal projection of all maxillary roots. The maxillary canine and first and second premolars displayed the most distortion, and the maxillary central incisor the least distortion for the up and down head rotations. For the mandibular teeth, 5° right caused the anterior roots to incline to the right, thereby increasing the mesiodistal angulation of teeth #41, 42, and 43 while decreasing the mesiodistal angulation of teeth #31, 32, and 33. Similarly, 5° left caused the anterior roots to incline to the left, thereby increasing the mesiodistal angulation of teeth #31 and 32 while decreasing the mesiodistal angulation of teeth #41,

42, and 43. As mentioned previously, 5° up and down had less of an effect on mandibular root projection than did 5° right and left rotations.

Table 3 reports the total envelope of angulation error separately for horizontal head rotation and vertical head rotation. Horizontal head rotation had the greatest distorting effect on the mandibular anterior teeth, with a perceived angular difference between 5° right and 5° left rotation of 4° to 22.3°. Vertical head rotation had the greatest distorting effect on the maxillary anterior and posterior teeth (excluding teeth #11 and 21), with a perceived angular difference between 5° up and 5° down rotation of 7.6° to 14.9°.

DISCUSSION

Considering that only one panoramic unit was used in this study, the results can only be applied to the Orthopantomograph OP 100. However, a companion study imple-

TABLE 1. Mean and Standard Deviation Value for the Image Mesiodistal Angulations by Tooth Number (in Degrees)^a

Tooth No.	Image Angles (5 Head Positions)									
	Ideal Position		5° Right		5° Left		5° Up		5° Down	
	Mean	SD	Mean	SD	Mean	SD	Mean	SD	Mean	SD
16	97.1	0.4	98.9	0.5	96.5	1.0	92.7	0.4	102.8	0.6
15	98.3	0.9	101.3	0.9	99.9	1.1	92.7	0.6	105.3	0.9
14	98.0	0.4	99.1	0.7	101.0	1.4	90.7	0.8	104.9	0.9
13	97.0	0.9	97.2	0.7	99.2	0.7	91.2	0.7	101.7	0.7
12	92.6	0.7	92.2	0.6	94.3	0.8	90.1	0.6	97.7	0.6
11	90.0	0.9	89.3	0.8	89.9	0.3	89.6	1.0	91.1	0.7
21	94.1	1.2	94.0	0.6	93.8	0.6	94.0	0.9	95.4	0.6
22	94.0	0.8	96.1	0.6	95.2	0.8	91.2	0.6	98.9	0.6
23	93.1	1.0	94.5	1.4	95.9	1.2	87.9	1.2	100.4	1.3
24	98.2	0.6	99.0	1.2	100.9	0.8	91.3	0.8	106.2	1.1
25	93.0	0.8	91.4	0.6	96.4	0.6	86.9	0.6	99.6	0.4
26	94.7	0.6	93.9	0.7	97.9	0.8	90.6	1.3	100.0	0.5
36	85.3	0.6	88.7	0.6	81.1	0.6	87.5	0.7	84.3	1.4
35	87.0	0.6	89.3	0.6	82.9	0.9	89.8	0.8	86.0	1.0
34	86.3	0.7	86.6	1.1	82.9	0.6	88.5	1.4	86.3	1.1
33	84.5	1.1	80.5	2.3	84.5	0.7	87.8	1.4	87.1	1.8
32	89.1	1.6	80.8	3.9	95.3	2.8	89.8	1.4	97.1	5.5
31	92.7	2.3	85.6	3.2	102.9	2.1	92.8	2.0	101.6	9.1
41	91.7	2.4	100.3	3.9	78.0	3.1	89.8	2.2	90.4	12.0
42	90.0	1.9	94.6	2.3	75.9	2.2	87.6	1.4	91.0	7.4
43	87.8	1.2	89.4	1.6	76.0	3.5	89.3	1.3	90.2	2.6
44	86.8	0.3	85.1	1.1	80.9	3.3	89.4	0.9	87.3	0.8
45	89.3	0.9	86.7	0.8	91.8	2.2	93.3	0.5	89.2	1.7
46	86.0	0.5	83.4	1.0	89.4	0.8	89.0	0.5	84.8	1.3

^a A mesiodistal angulation value greater than 90° indicates a distal inclination to the root. A mesiodistal angulation value less than 90° indicates a mesial inclination to the root.

menting four different panoramic units with the same testing device at a standardized head position revealed striking similarities and trends between panoramic units in their overestimation and underestimation of tooth angulations.⁴¹ In addition, although the results can only be applied to the typodont tooth angulations represented, the skull/typodont testing device was reasonably anatomic in design. The arch form, arch dimensions, and positioning of the dentition within the skull could represent a clinical situation. Although the true buccolingual angulations of the typodont were not determined, lateral cephalometric measurements of the upper and lower incisor angulations revealed positioning well within a range of normal.

This testing device is in contrast to previous studies using nonanatomic tooth angulations with considerably less attention to jaw positioning within the panoramic unit's image layer.^{2,17,38} Lucchesi et al² used a Plexiglas mandibular model with steel pins placed at mesiodistal angulations selected randomly but confined to a range of -20 to +20 degrees. Three-dimensional positioning of the model into the panoramic unit used not a skull, but rather placement within the unit's chin rest. Other investigators have relied on steel wire meshes to depict arch form and dimension.^{17,38} The lead shot utilized to represent tooth angulations was usually orientated with total disregard for the unique mesiodistal

and buccolingual inclinations represented in the human dentition.

The results of this study revealed that most of the image angulations from the four aberrant head positions were statistically significantly different from the image angulations at the ideal head position. The application of clinically significant tolerance limits should be applied to this research. Previous investigators have reported that for clinical purposes, variations of as much as 2.5° (in either direction) between a tooth and an established reference plane does not constitute a serious objection to the use of the radiograph.^{12,17,38} Application of these clinically significant tolerance limits revealed that 53% of the maxillary and mandibular image angles from the four head positions were still clinically significantly different from the image angles at ideal head position.

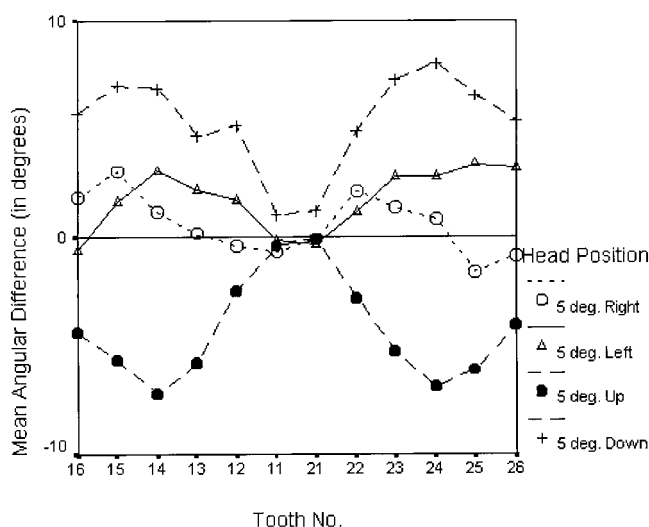
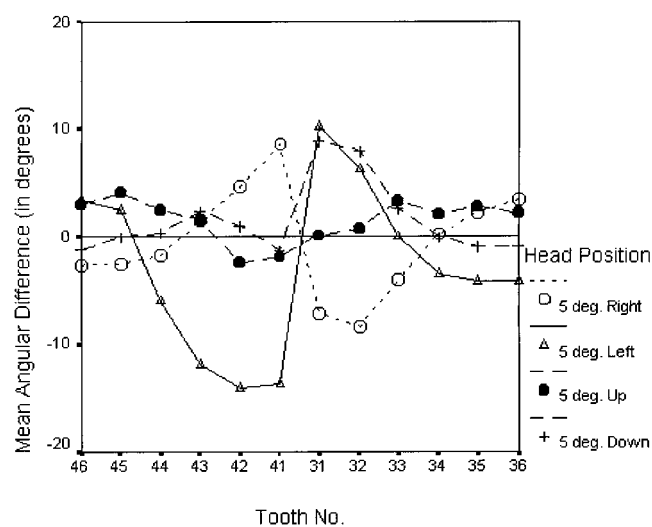
The relative sensitivity of the maxillary tooth angulations to up/down skull rotation and of the mandibular tooth angulations to right/left rotation is difficult to explain. Horizontal head rotation alters the object-film and source-object distances, resulting in varying degrees of horizontal and vertical magnification, and therefore angle distortion. Horizontal head rotation also alters beam projection angle. With the image layer being narrowest in the anterior dental region, it is possible that the mandibular anterior teeth are less tolerant of horizontal rotation.

TABLE 2. Paired *t*-test Comparisons of Mesiodistal Tooth Angulations at Varying Vertical and Horizontal Head Positions vs Idealized Head Position (Mean Difference in Degrees)^a

Tooth No.	5° Right vs Ideal		5° Left vs Ideal		5° Up vs Ideal		5° Down vs Ideal	
	Mean Difference	<i>P</i> Value	Mean Difference	<i>P</i> Value	Mean Difference	<i>P</i> Value	Mean Difference	<i>P</i> Value
16	1.9	.001*	-0.6	.191	-4.4	.001*	5.7	.001*
15	3.0	.014*	1.6	.090	-5.6	.001*	7.0	.001*
14	1.2	.031*	3.0	.004*	-7.2	.001*	6.9	.001*
13	0.2	.736	2.2	.023*	-5.8	.001*	4.7	.001*
12	-0.4	.454	1.7	.008*	-2.4	.004*	5.2	.001*
11	-0.7	.372	-0.1	.820	-0.4	.372	1.0	.168
21	-0.1	.903	-0.4	.617	-0.1	.925	1.3	.072
22	2.2	.014*	1.2	.088	-2.8	.009*	4.9	.001*
23	1.4	.053	2.8	.012*	-5.2	.001*	7.3	.001*
24	0.9	.243	2.8	.001*	-6.9	.001*	8.0	.001*
25	-1.6	.014*	3.4	.001*	-6.1	.001*	6.6	.001*
26	-0.8	.038*	3.2	.002*	-4.1	.006*	5.3	.001*
36	3.5	.001*	-4.1	.002*	2.2	.002*	-0.9	.069
35	2.3	.005*	-4.1	.001*	2.8	.004*	-1.0	.126
34	0.3	.563	-3.4	.002*	2.2	.062	0.0	.988
33	-4.0	.005*	0.0	.987	3.3	.005*	2.6	.068
32	-8.3	.008*	6.2	.006*	0.8	.290	8.0	.044*
31	-7.2	.006*	10.2	.001*	0.1	.906	8.9	.119
41	8.6	.019*	-13.7	.003*	-1.9	.261	-1.3	.798
42	4.6	.042*	-14.1	.001*	-2.4	.122	1.0	.725
43	1.6	.208	-11.8	.003*	1.5	.198	2.4	.035*
44	-1.7	.013*	-5.9	.016*	2.6	.003*	0.4	.383
45	-2.5	.021*	2.6	.054	4.1	.001*	-0.1	.958
46	-2.6	.003*	3.4	.003*	3.0	.001*	-1.2	.069

^a Mean difference = (deviated head position, ie, 5° right, 5° left, 5° up, or 5° down) - (idealized head position).

* A *P* value of less than .05 is considered statistically significant.

**FIGURE 6.** Mean angular difference of the image (4 varying head positions) vs image (idealized head position) mesiodistal angulations for maxillary teeth by tooth number.**FIGURE 7.** Mean angular difference of the image (4 varying head positions) vs image (idealized head position) mesiodistal angulations for mandibular teeth by tooth number.

The possibility that aberrant head positioning or measurement error could have been responsible for true/image angle differences must be considered. However, great care was taken in the use of all machine guides for skull positioning. Use of a custom-designed head holder ensured the

validity of the horizontal and vertical head rotation about a reproducible axis of rotation. In addition, the skull positioning was repeated five times for each machine to establish a data set of five measurements for each tooth. Subjectivity of landmark identification on the scanned panto-

TABLE 3. Total Envelope of Error for Combined Horizontal (5° Right/5° Left) and Combined Vertical (5° Up/5° Down) Head Rotation (Mean Angular Difference in Degrees)

Tooth No.	Horizontal Head Rotation		Vertical Head Rotation	
	Mean Angular Difference	SD	Mean Angular Difference	SD
16	2.5	0.6	10.1	0.8
15	1.4	1.1	12.6	1.2
14	1.8	1.2	14.1	1.5
13	2.0	0.7	10.5	0.7
12	2.1	1.1	7.6	0.4
11	0.6	0.6	1.4	1.2
21	0.3	0.6	1.4	1.1
22	1.0	0.7	7.7	1.2
23	1.4	2.3	12.5	2.1
24	1.9	1.6	14.9	1.2
25	5.0	0.8	12.7	0.6
26	4.0	1.0	9.4	1.6
36	7.6	0.7	3.1	1.4
35	6.4	1.3	3.8	0.6
34	3.7	1.4	2.2	1.7
33	4.0	2.3	0.7	3.0
32	14.5	3.0	7.2	6.9
31	17.4	1.8	8.8	10.7
41	22.3	2.4	0.6	13.6
42	18.7	0.5	3.4	8.6
43	13.4	3.1	0.9	3.7
44	4.2	3.7	2.2	1.2
45	5.1	2.0	4.2	1.9
46	6.0	1.3	4.2	1.5

mography images was reduced by using the center of the radiopaque steel ball for identification as well as a computer-generated midpoint between adjacent teeth.

The decision to select 5° vertical and horizontal head rotation was based on an attempt to be as clinically relevant as possible. It appeared from markings on the skull that this degree of aberrant head positioning in clinical practice would likely represent the upper limit of improper patient positioning by qualified personnel.

This is the first study to use an orthodontic archwire as a reference plane for angular assessment of teeth. Previous investigators have chosen such reference planes as the upper and lower margins of the film, the palatal plane, the occlusal plane, the mandibular plane, the ramal plane, the inferior orbital plane, and the articular eminences.^{2,17,38,40} Although the occlusal plane and archwire plane would be anatomically similar, use of a radiopaque wire offers less subjectivity than determination of an occlusal plane. Furthermore, the proximity of the reference archwire and tooth to each other and to the plane of the image layer may result in less distortion than the use of a reference plane distant from the site of measurement. In a practical sense, use of an orthodontic archwire is very convenient in the angular assessment of teeth during orthodontic treatment, as it can be left in place during panoramic imaging.

CONCLUSION

The following conclusions can be drawn from this study:

1. The majority of maxillary and mandibular image angles (64%) from the 4 head positions were statistically significantly different from image angles at the idealized head position.
2. Vertical head rotation (5° up and 5° down) had a much more pronounced effect on the deviation of maxillary angle projection. Conversely, horizontal head rotation (5° right and 5° left) had a much more pronounced effect on the deviation of mandibular anterior angle projection from truth.
3. Application of clinically significant tolerance limits of 2.5° revealed that 53% of the maxillary and mandibular image angles from the four head positions were still clinically significantly different from the image angles at ideal head position.
4. The clinical assessment of mesiodistal tooth angulation with panoramic radiography should be approached with extreme caution, with an understanding of the inherent image distortions that are further complicated by the potential for aberrant head positioning.

ACKNOWLEDGMENT

The Rayburn McIntyre Memorial Fund supported this study. We acknowledge the mathematical and software design assistance of Kent West, BSc, MSc.

REFERENCES

1. Mayoral G. Treatment results with light wires studied by panoramic radiography. *Am J Orthod.* 1982;81:489-497.
2. Lucchesi MV, Wood RE, Nortje CJ. Suitability of the panoramic radiograph for assessment of mesiodistal angulation of teeth in the buccal segments of the mandible. *Am J Orthod Dentofac Orthop.* 1988;94:303-310.
3. Ursi WJ, Almeida RR, Tavano O, Henriques JF. Assessment of mesiodistal axial inclination through panoramic radiography. *J Clin Orthod.* 1990;24:166-173.
4. Andrews LF. The six keys to normal occlusion. *Am J Orthod.* 1972;62:296-309.
5. Edwards JG. The prevention of relapse in extraction cases. *Am J Orthod.* 1971;60:128-144.
6. Graber TM. Postmortems in posttreatment adjustment. *Am J Orthod.* 1966;52:331-352.
7. Hatasaka HH. A radiographic study of roots in extraction sites. *Angle Orthod.* 1976;46:64-68.
8. Holdaway RA. Bracket angulation as applied to the edgewise appliance. *Angle Orthod.* 1952;22:227-236.
9. Strang RJ. Factors associated with successful orthodontic treatment. *Am J Orthod.* 1952;38:790-800.
10. Jarabak JR, Fizzell JA. *Technique and Treatment With Light-Wire Edgewise Appliances.* St Louis, Mo: CV Mosby Co; 1972:277-379.
11. Goaz PW, White SC. *Oral Radiology: Principles and Interpretations.* 2nd ed. St Louis, Mo: CV Mosby Co; 1987:314-338.
12. Frykholm A, Malmgren O, Samfors KA, Welander U. Angular

- measurements in orthopantomography. *Dentomaxillofac Radiol.* 1977;6:77–81.
13. Samfors KA, Welander U. Angle distortion in narrow beam rotation radiography. *Acta Radiol Diagn (Stockh).* 1974;15:570–576.
 14. Tronje G, Welander U, McDavid WD, Morris CR. Image distortion in rotational panoramic radiography, III: inclined objects. *Acta Radiol Diagn (Stockh).* 1981;22:585–592.
 15. Turner KO. Limitations of panoramic radiography. *Oral Surg Oral Med Oral Pathol.* 1968;26:312–320.
 16. Kite OW, Swanson T, Levin S, Bradbury E. Radiation and image distortion in the panorex x-ray unit. *Oral Surg.* 1962;15:1201–1210.
 17. Samawi SS, Burke PH. Angular distortion in orthopantomogram. *Br J Orthod.* 1984;11:100–107.
 18. Rowse CW. Notes on interpretation of the orthopantomogram. *Br Dent J.* 1971;130:425–434.
 19. Updegrave WJ. The role of panoramic radiography in diagnosis. *Oral Surg Oral Med Oral Pathol.* 1966;22:49–57.
 20. Lund TM, Manson-Hing LR. A study of the focal troughs of three panoramic dental x-ray machines, I: the area of sharpness. *Oral Surg Oral Med Oral Pathol.* 1975;39:318–328.
 21. Manson-Hing LR, Lund TM. A study of the focal troughs of three panoramic dental x-ray machines, II: image dimensions. *Oral Surg Oral Med Oral Pathol.* 1975;39:647–653.
 22. Schiff T, D'Ambrosio J, Glass BJ, Langlais RP, McDavid WD. Common positioning and technical errors in panoramic radiography. *J Am Dent Assoc.* 1986;113:422–426.
 23. McVaney TP, Kalkwarf KL. Misdiagnosis of an impacted supernumerary tooth from a panoramic radiograph. *Oral Surg Oral Med Oral Pathol.* 1976;41:678–681.
 24. Scarfe WC, Eraso FE, Farman AG. Characteristics of the Orthopantomograph OP 100. *Dentomaxillofac Radiol.* 1998;27:51–57.
 25. McDavid WD, Tronje G, Welander U, Morris CR, Nummikoski P. Imaging characteristics of seven panoramic x-ray units. *Dentomaxillofac Radiol.* 1985;8(suppl):1–68.
 26. Lund TM, Manson-Hing LR. Relations between tooth positions and focal troughs of panoramic machines. *Oral Surg Oral Med Oral Pathol.* 1975;40:285–293.
 27. Hassen SM, Manson-Hing LR. A study of the zone of sharpness of three panoramic x-ray machines and the effect of screen speed on the sharpness zone. *Oral Surg Oral Med Oral Pathol.* 1982;54:242–249.
 28. Razmus TF, Glass BJ, McDavid WD. Comparison of image layer location among panoramic machines of the same manufacturer. *Oral Surg Oral Med Oral Pathol.* 1989;67:102–108.
 29. Welander U, Wickman G. Blurring and layer thickness in narrow beam rotational radiography. *Acta Radiol Diagn (Stockh).* 1977;18:705–714.
 30. Glass BJ, McDavid WD, Welander U, Morris CR. The central plane of the image layer determined experimentally in various rotational panoramic x-ray machines. *Oral Surg Oral Med Oral Pathol.* 1985;60:104–112.
 31. Scarfe WC, Nummikoski P, McDavid WD, Welander U, Tronje G. Radiographic interproximal angulations: implications for rotational panoramic radiography. *Oral Surg Oral Med Oral Pathol.* 1993;76:664–672.
 32. Friedland B. Clinical radiological issues in orthodontic practice. *Semin Orthod.* 1998;4:64–78.
 33. Larheim TA, Svanaes DB. Reproducibility of rotational panoramic radiography: mandibular linear dimensions and angles. *Am J Orthod Dentofac Orthop.* 1986;90:45–51.
 34. Wyatt DL, Farman AG, Orbell GM, Silveira AM, Scarfe WC. Accuracy of dimensional and angular measurements from panoramic and lateral oblique radiographs. *Dentomaxillofac Radiol.* 1995;24:225–231.
 35. Tronje G, Eliasson S, Julin P, Welander U. Image distortion in rotational panoramic radiography, II: vertical distances. *Acta Radiol Diagn (Stockh).* 1981;22:449–455.
 36. Chaushu S, Chaushu G, Becker A. The use of panoramic radiographs to localize displaced maxillary canines. *Oral Surg Oral Med Oral Radiol Endod.* 1999;88:511–516.
 37. Gavel V, Dermaut V. The effect of tooth position on the image of unerupted canines on panoramic radiographs. *Eur J Orthod.* 1999;21:551–560.
 38. Philipp RG, Hurst RV. The cant of the occlusal plane and distortion in the panoramic radiograph. *Angle Orthod.* 1978;48:317–323.
 39. Martinez-Cruz S, Manson-Hing LR. Comparison of focal trough dimensions and form by resolution measurements in panoramic radiography. *J Am Dent Assoc.* 1987;114:639–642.
 40. Xie Q, Soikkonen K, Wolf J, Mattila K, Gong M, Ainamo A. Effect of head positioning in panoramic radiography on vertical measurements: an *in vitro* study. *Dentomaxillofac Radiol.* 1996;25:61–66.
 41. McKee IW. *The Accuracy of Panoramic Radiography in the Assessment of Mesiodistal Tooth Angulations at Varying Horizontal and Vertical Head Positions* [master's thesis]. Edmonton, Alberta, Canada: University of Alberta; 2001.