

An Orthodontic Case of Transposition of the Upper Right Canine and First Premolar

Kayo Sato, DDS^a; Masahiko Yokozeki, DDS, PhD^b; Toyoaki Takagi, DDS^c;
Keiji Moriyama, DDS, PhD^d

Abstract: Tooth transposition is a rare and severe positional anomaly that may create many orthodontic problems from both esthetic and functional points of view. In this report, we describe a case of the orthodontic management of a transposition of the upper canine and premolar with congenital absence of the upper lateral incisor. The patient was treated with a multibracket appliance and the extraction of three premolars, and treatment was completed without a need for any prosthetic replacement. (*Angle Orthod* 2002;72:275–278.)

Key Words: Tooth transposition; Dental substitution; Congenitally missing; Orthodontic management

INTRODUCTION

Tooth transposition, which is considered to be a subdivision of ectopic eruption, can be defined as a positional interchange of two adjacent teeth in the dental arch.¹ Complete transposition has been described as the transposition of both the crown and the entire root structure. Incomplete transposition has been described as the transposition of the crown but not the root apex.² Among the many types of transpositions, maxillary canine-premolar transposition is described as the most frequently seen disorder.³ The case of maxillary canine-premolar transposition is usually better managed orthodontically on a nonextraction basis, keeping the transposed order of the teeth.³ Because of atypical reasons^{4,5} or dental crowding, extraction of permanent teeth may be considered for the orthodontic treatment of patients with maxillary canine-premolar transposition. In this report, we describe the orthodontic management of a case of upper right canine and premolar transposition associated with a congenital absence of the upper lateral incisor.

CASE REPORT

The patient, a healthy 12-year-old boy, was initially examined at the Tokushima University Dental Hospital. A clinical oral and dental examination revealed an Angle Class I malocclusion with moderate crowding of mandibular dentition in the early permanent dentition. Since the right maxillary lateral incisor was congenitally absent, the upper midline was deviated to the right, and the right maxillary canine was in an ectopic buccal position (Figure 1). The arch length discrepancy was +1 mm in maxillary dentition and -4 mm in mandibular dentition. A panoramic radiograph showed tooth germs of the four third molars and transposition of the root apex of the right maxillary canine (Figure 2). Cephalometric analysis did not show any notable deviation in the skeletal and dental patterns except as shown in Table 1.

TREATMENT

The treatment plan was to extract the lower left and right first premolars and the upper left first premolar to correct the upper midline and eliminate the mandibular discrepancy. The transposed right maxillary premolar, because of its complete transposition, was then to be used in the occlusion by substituting it for the right maxillary lateral incisor using a multibracket appliance. A lingual arch was placed in the maxillary dentition to control the maxillary right first premolar and preserve the anchorage.

All of the maxillary and mandibular teeth were bonded with a 0.018 × 0.025" standard edgewise appliance after the removal of the three premolars. A special effort was made during treatment to control the root position of the right first molar. After the removal of bands and brackets,

^a Resident, Department of Orthodontics, School of Dentistry, University of Tokushima, Tokushima, Japan.

^b Assistant Professor, Department of Orthodontics, School of Dentistry, University of Tokushima, Tokushima, Japan.

^c Instructor, Department of Orthodontics, School of Dentistry, University of Tokushima, Tokushima, Japan.

^d Professor and Chairman, Department of Orthodontics, School of Dentistry, University of Tokushima, Tokushima, Japan.

Corresponding author: Keiji Moriyama, DDS, PhD, Department of Orthodontics, School of Dentistry, University of Tokushima, 3-18-15, Kuramoto-cho, Tokushima 770-8503, Japan.
(e-mail: moriyama@dent.tokushima-u.ac.jp).

Accepted: October 2001. Submitted: July 2001.

© 2002 by The EH Angle Education and Research Foundation, Inc.

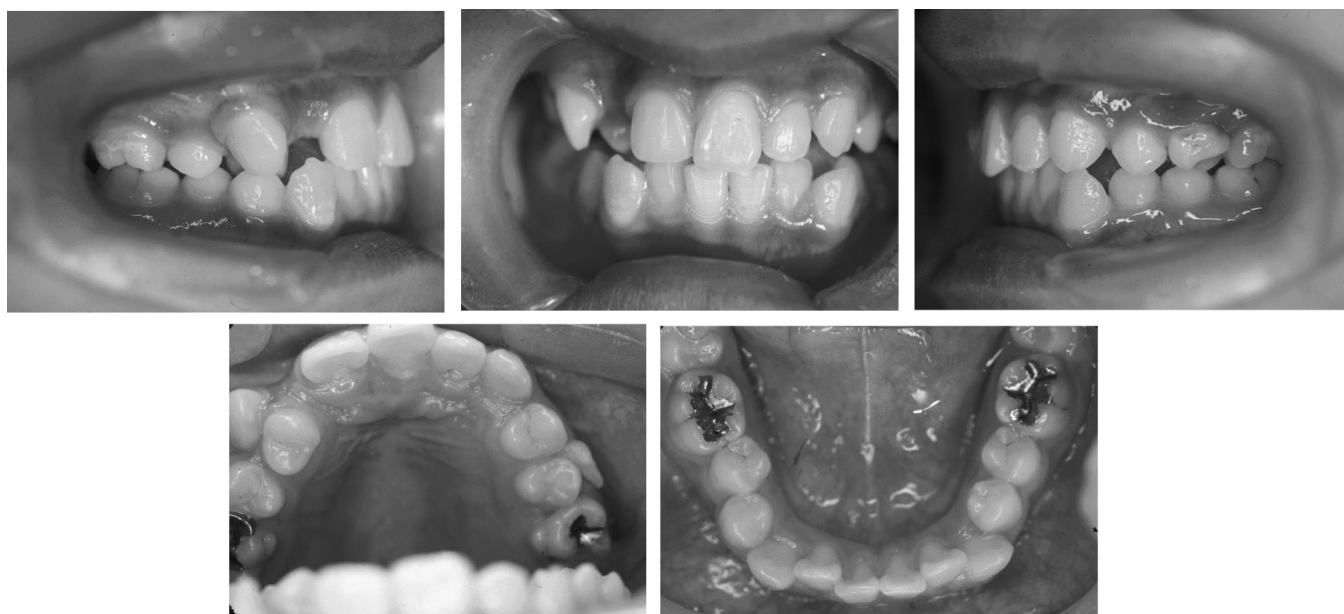

FIGURE 1. Pretreatment intraoral views.

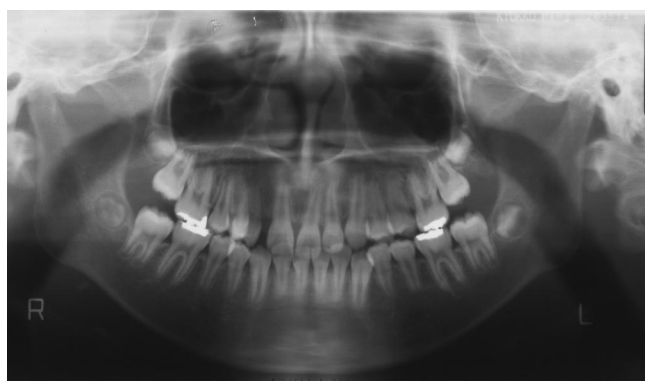

FIGURE 2. Pretreatment panoramic radiograph.

a maxillary removable retainer and a mandibular lingual fixed retainer were placed for retention.

TREATMENT RESULT

The crowding of the lower arch and the deviation of the maxillary dental midline were corrected, and the results are shown in the posttreatment stage (Figures 3 and 4). When the initial and posttreatment skeletal measurements are compared (Table 1), a slight decrease in the SNA angle (80.9° to 79.6°) and ANB angle (5.1° to 3.9°) was observed, probably due to the downward growth of the maxilla (Figure 5). The mandibular plane angle (31.3° to 28.7°) and the gonial angle (125.0° to 121.8°) also decreased during the treatment period. Comparison of the initial and posttreatment denture measurements showed changes in U1 to the

TABLE 1. Summary of Cephalometric Analysis^a

Measurement	Pretreatment		Posttreatment	
	Patient (age, 12 y, 0 mo)	Age-Matched Japanese Population (mean age, 11 y, 2 mo ± 1.1 mo)	Patient (age, 18 y, 1 mo)	Age-Matched Japanese Population (mean age, adult male)
SNA, degrees	80.9	80.53	79.6	81.82
SNB, degrees	75.9	76.22	75.6	78.61
ANB, degrees	5.1	4.2	3.9	3.28
MPA, degrees	31.3	32.44	28.7	26.25
Gonial angle, degrees	125.0	128.31	121.8	116.3
U1 to FHP, degrees	110.0	110.55	107.2	108.94
L1 to MP, degrees	92.4	94.11	88.0	94.67
FMIA, degrees	56.3	53.45	63.3	58.98

^a MPA indicates mandibular plane angle; FHP, Frankfort horizontal plane.

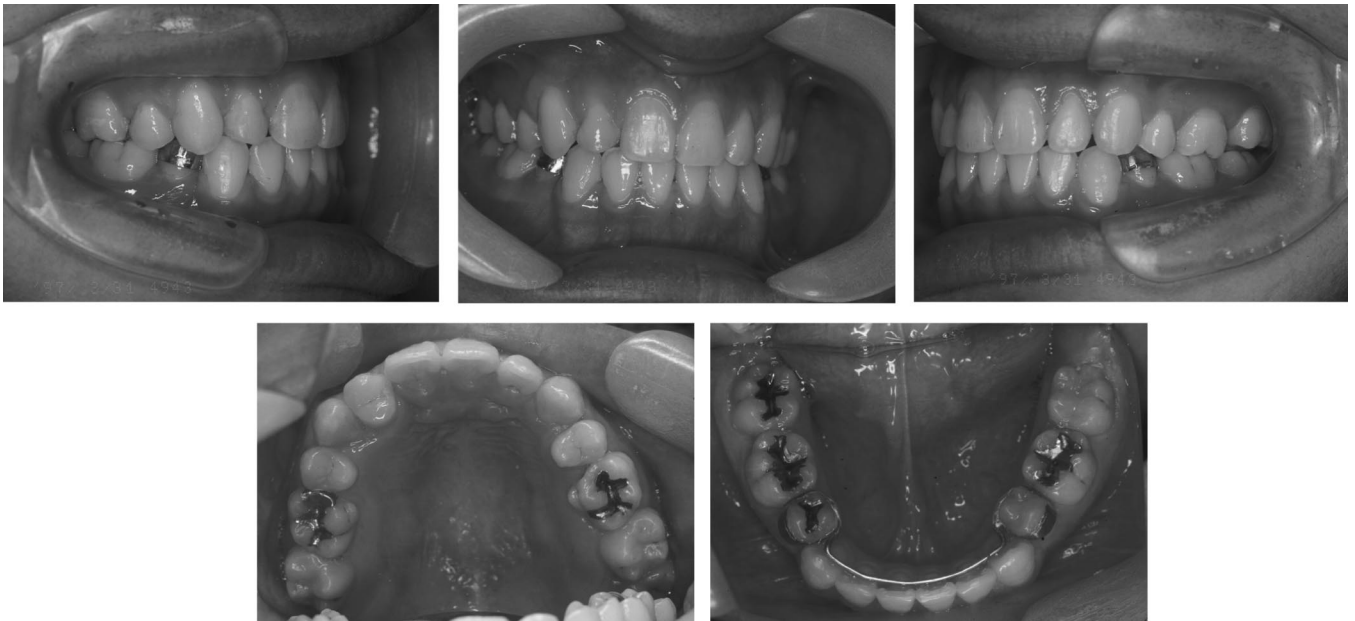

FIGURE 3. Posttreatment intraoral views.

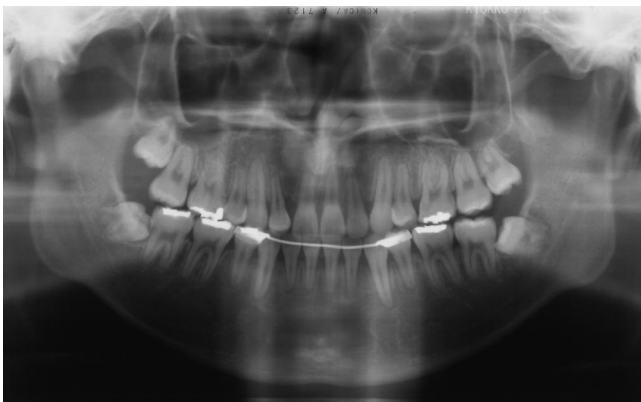

FIGURE 4. Posttreatment panoramic radiographs.

Frankfort horizontal plane (110.0° to 107.2°), L1 to the mandibular plane (92.4° to 88.0°), and FMIA (56.3° to 63.3°), probably due to the extraction of the first premolars.

DISCUSSION

Tooth transposition is a rare and severe positional anomaly that causes many problems during orthodontic management. Although the etiology of tooth transposition remains unclear, two principal theories of this anomaly have been proposed. One is transposition of the analogue during odontogenesis and migration of the tooth from the normal path of eruption.⁶ The other is a genetic influence, which has been stressed because of the bilateral occurrence of the problem, the sex-associated frequency difference, and the high prevalence of other associated dental anomalies.^{1,7} It has been reported that a large number of cases with transposed teeth are associated with dental anomalies such as a

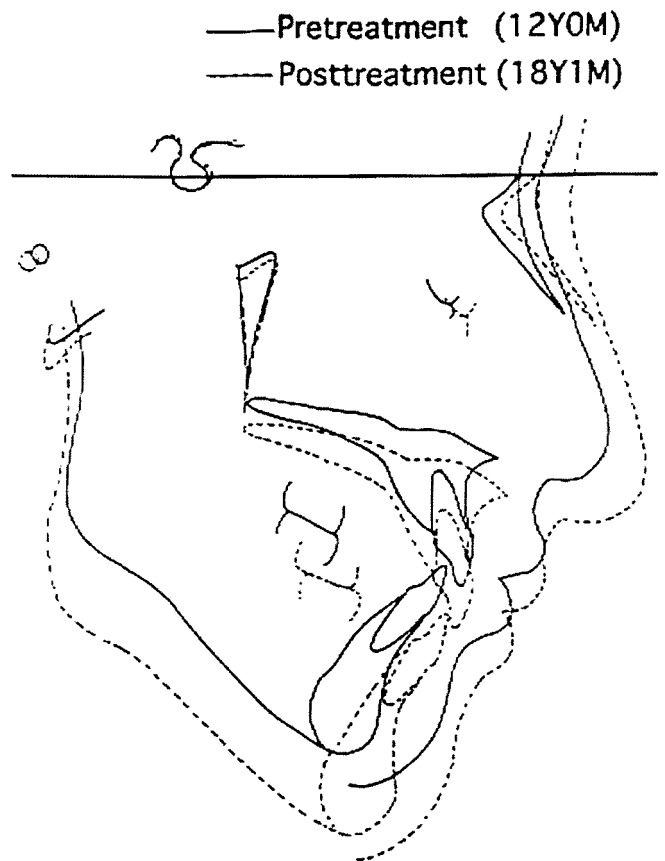


FIGURE 5. Superimposed lateral cephalometric tracing.

peg-shaped lateral incisor and congenitally absent teeth in some studies of a large sample size of people seeking dental or orthodontic treatment.^{1,3,6-10} Particularly, a high incidence of congenitally absent teeth and peg-shaped lateral incisors are associated with maxillary canine and premolar transposition,^{1,7,8} as was detailed for the case in this article. Interestingly, a high prevalence of maxillary canine and premolar transposition is reported in patients with Down syndrome characterized by trisomy 21.¹¹ In the case reported here, the right maxillary incisor was congenitally missing, but the patient had no family history of dental anomalies, earlier dental trauma, or inflammation for these to be considered as causative for the transposition.

Many cases of the orthodontic treatment of transposed teeth have been reported, and substitution of a transposed premolar for a maxillary lateral incisor has also been described in previous reports. Parker⁵ reported the long-term stability of orthodontic treatment by bilaterally substituting the premolars for the lateral incisors in a case with bilateral maxillary canine-premolar transposition coupled with a congenitally missing maxillary lateral incisor. Nestel and Walsh⁴ reported unilateral substitution of a premolar for a lateral incisor in a case of bilateral maxillary canine-premolar transposition and unilateral congenital absence of the maxillary lateral incisor. When maxillary canine-premolar transposition is associated with a missing maxillary lateral incisor, the substitution of the premolar for the lateral incisor could be chosen to avoid prosthetic restorations with a bridge or denture.

After an overall consideration of the cephalometric and dental cast analyses, one might have considered the alternative of nonextractive treatment for this patient. If nonextractive treatment were selected for this case, however, an atypical prosthetic treatment would have been expected. Therefore, substitution of the transposed premolar for the lateral incisor was finally selected as the treatment, even if extraction of other premolars was needed. Another advantage of this type of substitution was to create canine guidance during lateral movement of the mandible. Fortunately, the size of the right maxillary premolar was very similar to that of the left maxillary lateral incisor. Therefore, a Class I canine relationship was successfully established on the right side as well as on the left side after orthodontic treatment. Furthermore, the patient could also accept the esthetic outcome and was satisfied with the alignment of the maxillary anterior teeth after morphologic adjustment of the transposed first premolar during the last step of the treatment.

It has been reported that the prevalence of tooth transposition is 0.065% in the Japanese general population¹² and 0.66% in Japanese orthodontic patients.¹³ This rare dental

anomaly makes orthodontic management more complicated, and we have to consider many factors that affect the treatment results such as esthetics, occlusion, treatment period, patient cooperation, and periodontal support. Accumulation of treated cases of tooth transposition would provide clinicians with the best understanding of the orthodontic treatment options.

CONCLUSION

Although the prevalence of tooth transposition is low, this type of dental anomaly causes many problems in orthodontic management. Additionally, if there are congenitally missing teeth associated with the transposed teeth, treatment planning becomes even more complicated.

Achievement of optimal function and esthetics in cases with tooth transposition requires the utmost care in the design of the treatment and the cooperation of the patient. However, the challenge of orthodontic treatment may have good results and also may provide orthodontists with the best understanding of how to resolve similar malocclusions in the future.

REFERENCES

1. Peck L, Peck S, Attia Y. Maxillary canine-first premolar transposition, associated dental anomalies and genetic basis. *Angle Orthod.* 1993;63:99-109.
2. Shapira Y, Kuflinec MM. Tooth transpositions—a review of the literature and treatment considerations. *Angle Orthod.* 1989;59:271-276.
3. Peck S, Peck L. Classification of maxillary tooth transpositions. *Am J Orthod Dentofac Orthop.* 1995;107:505-517.
4. Nestel E, Walsh JS. Substitution of a transposed premolar for a congenitally absent lateral incisor. *Am J Orthod Dentofac Orthop.* 1988;93:395-399.
5. Parker WS. Transposed premolars, canines, and lateral incisors. *Am J Orthod Dentofac Orthop.* 1990;97:431-448.
6. Shapira Y. Transposition of canines. *J Am Dent Assoc.* 1980;100:710-712.
7. Chattopadhyay A, Srinivas K. Transposition of teeth and genetic etiology. *Angle Orthod.* 1996;66:147-152.
8. Plunkett DJ, Dysart PS, Kardos TB, Herbison GP. A study of transposed canines in a sample of orthodontic patients. *Br J Orthod.* 1998;25:203-208.
9. Peck S, Peck L, Kataja M. Site-specificity of tooth agenesis in subjects with maxillary canine malpositions. *Angle Orthod.* 1996;66:473-476.
10. Peck S, Peck L, Kataja M. Mandibular lateral incisor-canine transposition, concomitant dental anomalies, and genetic control. *Angle Orthod.* 1998;68:455-466.
11. Shapira J, Chaushu S, Becker A. Prevalence of tooth transposition, third molar agenesis, and maxillary canine impaction in individuals with Down syndrome. *Angle Orthod.* 2000;70:290-296.
12. Asakura S, Okamoto T, Tamoto H, Kumano S, Murata Y. Forty cases of tooth transposition. *Dent Outlook.* 1958;15:979-986.
13. Yoshida S, Suzuki A, Ito K, Tanne K. Current status of migrated tooth and clinical consideration for the orthodontic treatment. *J Hiroshima University Dent Soc.* 1995;27:266-274.