

# Tooth Abrasion in Unilateral Posterior Crossbite in the Deciduous Dentition

Isabella Tollaro, MD, DDS<sup>a</sup>; Efisio Defraia, MD, DDS<sup>b</sup>; Andrea Marinelli, DDS, PhD<sup>c</sup>; Muhieddin Alarashi, DDS, PhD<sup>d</sup>

**Abstract:** The aim of this study was to evaluate the degree of abrasion in posterior teeth of subjects with unilateral posterior crossbite in the deciduous dentition. A group of 54 untreated subjects in deciduous dentition (test group, TG) was selected from a parent sample of 1500 patients from the files of the Department of Orthodontics of the University of Florence. A sample of 20 subjects with normal occlusion in the deciduous dentition was selected as the control group (CG). As experimental units in TG, 54 crossbite sides (CB, consisting of 33 right and 21 left crossbite sides) and 54 noncrossbite sides (NCB) were used. In CG, one randomly chosen single side for each subject (NCBC) was used for comparisons. The findings of the present study indicated that subjects with unilateral crossbite in the deciduous dentition showed a significantly smaller degree of dental abrasion in the crossbite side when compared with both the opposite side and control group sides. The lack of abrasion in crossbite sides was primarily due to a significantly lesser degree of abrasion of the upper deciduous canines. (*Angle Orthod* 2002;72:426–430.)

**Key Words:** Occlusal wear; Primary dentition; Malocclusion; Dental attrition

## INTRODUCTION

Tooth abrasion can be considered as a physiological condition in the deciduous dentition, with its pattern indicating the functional relationship between the dental arches.<sup>1</sup> The degree of tooth abrasion differs in different populations and ethnic groups in relation to dietary habits. Eskimos, North American Indians, and Greek mountaineers, for instance, showed a great extent of abrasion as a result of coarse and rough food diets.<sup>2</sup> In a Swedish population, Hugoson et al<sup>3</sup> found that tooth wear was absent or slight in 19% of a sample of 5-year-old children in the primary dentition. Madlena and coworkers<sup>4</sup> examined 992 extracted primary teeth from Hungarian children by means of a stereomicroscope, and they found tooth wear in more than 75% of the examined teeth.

Tooth abrasion allows for adequate sliding between the dental arches, which is a necessary condition in order to achieve functionally correct development of the masticatory system.<sup>1,5</sup> If physiological abrasion doesn't occur, the morphology and position of the teeth in the dental arches can create interference to physiological occlusion. This uncomfortable occlusion can be produced by a series of factors such as long, sharp deciduous canines, and as a result, the mandible may search for a new adaptive position.<sup>6</sup> In the sagittal plane, extensive cuspal abrasion, through the removal of occlusal interferences, permits the mandible to shift in a forward position more easily. In contrast, children without physiological abrasion assume a temporary functional retraction of the mandible during closure due to occlusal interferences usually in the canine region.<sup>7</sup>

Similarly in the transverse plane, it can be hypothesized that, in the presence of some occlusal interference, the mandible could shift laterally, resulting in a lateral shift with a posterior crossbite occlusion. In fact, several authors<sup>8–11</sup> observed that forced guidance occurred in most unilateral crossbites.

Posterior crossbite is a common malocclusion in early stages of development, with prevalence rates ranging from 8% to 16% and with unilateral crossbite considered the most frequent clinical condition.<sup>8–10,12–18</sup> It has been demonstrated that lateral posterior crossbite brings an anomalous chewing pattern in the mixed dentition<sup>19</sup> and that early correction is advisable to minimize future problems.<sup>20</sup>

The aim of this study was to evaluate the degree of abra-

<sup>a</sup> Professor, Head and Chairman, Department of Orthodontics, University of Florence, Italy.

<sup>b</sup> Assistant Professor, Department of Orthodontics, University of Florence, Italy.

<sup>c</sup> Program in Preventive Orthodontics, Department of Orthodontics, University of Florence, Italy.

<sup>d</sup> Program in Clinical Pediatrics and Orthodontics, Department of Orthodontics, University of Florence, Italy.

Corresponding author: Andrea Marinelli, DDS, PhD, Dipartimento di Odontostomatologia, Università degli Studi di Firenze, Via del Ponte di Mezzo 46–48, 50127 Firenze, Italia (e-mail: a.marinelli@yahoo.com).

Accepted: February 2002. Submitted: November 2001.

© 2002 by The EH Angle Education and Research Foundation, Inc.

sion in posterior teeth in subjects with unilateral crossbite in the primary dentition in order to investigate the role of tooth wear in association with lateral shift of the mandible and to determine possible occlusal targets for early treatment of the malocclusion.

### MATERIALS AND METHODS

A sample of 54 subjects with unilateral posterior crossbite (19 males, 35 females, test group [TG]) was selected from 1500 cases from the archives of the Department of Orthodontics of the University of Florence. The following inclusionary criteria were adopted:

- presence of unilateral posterior crossbite,
- absence of any previous orthodontic treatment,
- availability of dental casts of good quality,
- absence of missing teeth, dental traumas, dental anomalies, deep caries, restorations, pedodontic crowns,
- availability of panoramic x-rays.

Mean age of the TG was four years and 10 months  $\pm$  six months. The unilateral posterior crossbite (as assessed from the dental records and confirmed on the dental casts) was on the right side in 33 cases and on the left side in 21 cases.

A sample of 20 patients with normal occlusion in the deciduous dentition (nine males, 11 females, control group [CG]) was selected. The control group matched all inclusionary criteria with the exception of the posterior crossbite.

As experimental units in the TG, 54 crossbite sides (CB, consisting of 33 right and 21 left crossbite sides) and 54 noncrossbite sides (NCB) were used. In the CG (20 subjects), one randomly chosen single side for each subject (noncrossbite control [NCBC]) was used for comparisons.

### METHODS

Two operators, in the same room and in the same lighting, performed simultaneous examinations of the dental casts. The degree of abrasion for every posterior tooth was assigned a score from zero to three according to the method of Knight and coworkers<sup>21</sup> as follows:

Score 0 = no obvious wear facets in enamel; occlusal/incisal structure was intact (Figure 1).

Score 1 = marked wear facets in enamel; occlusal/incisal structure altered (Figure 2).

Score 2 = wear into dentin; dentin exposed occlusally/incisally and/or occlusal/incisal structure changed in shape (Figure 3).

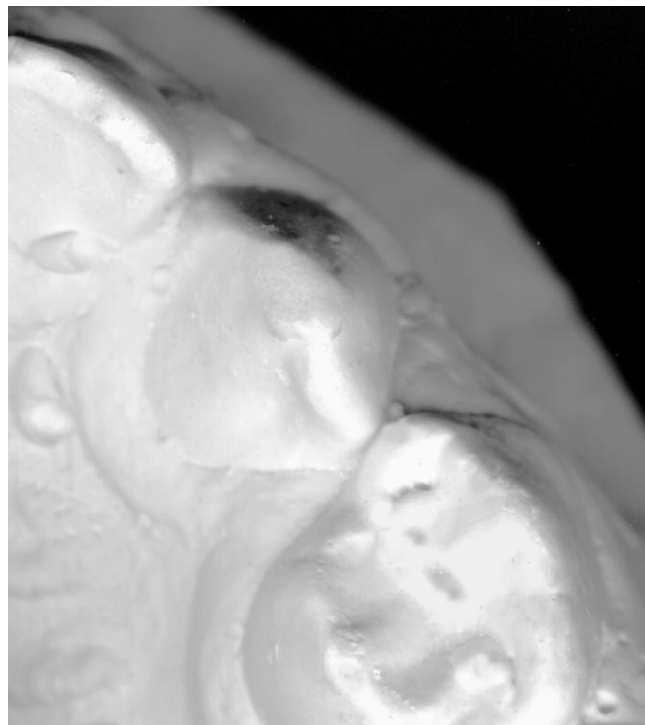
Score 3 = extensive wear into dentin; greater than 2 mm<sup>2</sup> of dentin was exposed occlusally/incisally; occlusal/incisal structure totally lost locally or generally.

The deciduous central and lateral incisors were not analyzed because they were never included in the crossbites.

The recorded data for CB, NCB, and NCBC were organized as follows for statistical evaluation:



**FIGURE 1.** Score 0 = no obvious wear facets in enamel. Occlusal/incisal structure intact.



**FIGURE 2.** Score 1 = marked wear facets in enamel. Occlusal/incisal structure altered.



**FIGURE 3.** Score 2 = wear into dentin. Dentin exposed occlusally/incisally and/or occlusal/incisal structure changed in shape.

- degree of abrasion of single teeth,
- degree of abrasion of single posterior segments of the dental arch (upper and lower posterior segments, each one consisting of the primary canine, the first primary molar, and the second primary molar),
- degree of abrasion of single sides, consisting of both upper and lower posterior segments of the dental arch (CB, NCB, NCBC).

#### Reproducibility error

Of the total of 74 dental casts, 15 subjects were randomly selected by another operator to be reevaluated by the original two raters without any knowledge of the subjects' identities. The second evaluations were performed two weeks later in the same room and lighting conditions as were the first evaluations. Scores of the first and the second observations were statistically compared by means of a kappa test with Yates's correction in order to calculate the degree of reproducibility in judgment. The result (0.94) expressed a high rate of reproducibility.

#### Statistical analysis

Descriptive statistics comprising prevalence rates for different abrasion scores were calculated. The categorical values for abrasion ratings were compared by means of a Chi-square test ( $P < .05$ ). The following comparisons were performed: CB vs NCB, CB vs NCBC, and NCB vs NCBC. All comparisons contrasted the degree of abrasion for single teeth, single arch segments, and single sides.

## RESULTS

Descriptive statistics and comparisons for all examined groups are given in Table 1. No tooth presented with an abrasion score of three. The comparison of the degree of abrasion for single teeth showed no significant differences between CB, NCB, and NCBC for upper and lower first and second primary molars or for the lower primary canine. The upper primary canines showed significantly less abrasion in CB than in NCB and NCBC. Absence of abrasion for the upper primary canine (score = 0) showed a prevalence rate of 40.7% in CB, 22% in NCB, and only 1.9% in NCBC.

A significant difference was assessed in the comparisons of the degree of abrasion in the upper posterior segment of the dental arch in CB when contrasted with NCB and with NCBC, and in NCB when contrasted with NCBC. The comparisons for the degree of abrasion in single sides exhibited similar results. We have also observed that the primary first molars were more abraded in all groups.

## DISCUSSION

The degree of abrasion in posterior deciduous teeth in subjects with unilateral crossbite in the primary dentition has not been investigated extensively in the literature. Most of the authors have studied functional and morphological aspects of the occlusion in patients with unilateral posterior crossbite in the deciduous dentition.<sup>19,20</sup> Information regarding the possible relationship between degree of abrasion of posterior deciduous teeth and unilateral crossbite is lacking. There are only some clinical observations on the association between pointed-shaped deciduous canines and occlusal interference.<sup>6</sup> Experimental studies concerning abrasion were performed in subjects in the mixed dentition without evaluating the influence or presence of crossbite.<sup>22</sup> The aim of the present study was to analyze the association between degree of abrasion and presence of unilateral posterior crossbite in the deciduous dentition.

A crucial methodological concern was represented by the choice of a reliable analysis for tooth abrasion on dental casts. The procedure described by Knight et al<sup>21</sup> for tooth wear scoring is advantageous in this regard because it does not require special instruments and possesses a high degree of reproducibility.

In the present study, the degree of tooth abrasion ranged from zero to two. No tooth wear with a score of three was recorded. Knight and coworkers<sup>21</sup> reported a very low percentage (2.7%) of teeth with a score of three in their sample, which consisted of older subjects (age range 6.3 to 15.2 years). It must be considered, however, that the method proposed by Knight et al<sup>21</sup> for scoring abrasion was elaborated to study patients in mixed and permanent dentitions. They also described a significant positive relationship between age and abrasion. The findings of the present study indicated that subjects with unilateral crossbite in the deciduous dentition show a significantly smaller degree of dental abrasion in the

**TABLE 1.** Categorical Values for Abrasion Ratings for Single Teeth, Single Posterior Arch Segments, and Single Sides<sup>a</sup>

	Abrasion Score			
	0	1	2	3
<b>CB (n = 54)</b>				
C superior AB	22 (40.7%)	26 (48.2%)	6 (11.1%)	0 (0%)
D superior	8 (14.8%)	30 (55.6%)	16 (29.6%)	0 (0%)
E superior	22 (40.7%)	30 (55.6%)	2 (3.7%)	0 (0%)
Upper segment AB	52 (32.1%)	86 (53.1%)	24 (16.8%)	0 (0%)
C inferior	26 (48.2%)	24 (44.4%)	4 (7.4%)	0 (0%)
D inferior	13 (24.1%)	26 (48.2%)	15 (27.7%)	0 (0%)
E inferior	27 (50%)	20 (37%)	7 (13%)	0 (0%)
Lower segment	66 (40.7%)	70 (43.2%)	26 (16.1%)	0 (0%)
Side AB	118 (36.4%)	156 (48.1%)	50 (15.5%)	0 (0%)
<b>NCB (n = 54)</b>				
C superior A	12 (22.2%)	29 (53.7%)	13 (24.1%)	0 (0%)
D superior	5 (9.3%)	33 (61.1%)	16 (29.6%)	0 (0%)
E superior	16 (29.6%)	36 (66.7%)	2 (3.7%)	0 (0%)
Upper segment AC	33 (20.4%)	98 (60.5%)	31 (19.1%)	0 (0%)
C inferior	23 (42.5%)	26 (48.2%)	5 (9.3%)	0 (0%)
D inferior	12 (22.2%)	22 (40.7%)	20 (37%)	0 (0%)
E inferior	18 (33.3%)	30 (55.6%)	6 (11.1%)	0 (0%)
Lower segment	53 (32.7%)	78 (48.2%)	31 (19.1%)	0 (0%)
Side AC	86 (26.5%)	176 (54.3%)	62 (19.2%)	0 (0%)
<b>NCBC (n = 20)</b>				
C superior B	1 (5%)	10 (50%)	9 (45%)	0 (0%)
D superior	0 (0%)	10 (50%)	10 (50%)	0 (0%)
E superior	4 (20%)	14 (70%)	2 (10%)	0 (0%)
Upper segment BC	5 (8.3%)	34 (56.7%)	21 (35%)	0 (0%)
C inferior	4 (20%)	12 (60%)	4 (20%)	0 (0%)
D inferior	4 (20%)	6 (30%)	10 (50%)	0 (0%)
E inferior	5 (25%)	11 (55%)	4 (20%)	0 (0%)
Lower segment	13 (21.7%)	29 (48.3%)	18 (30%)	0 (0%)
Side BC	18 (15%)	63 (52.5%)	39 (32.5%)	0 (0%)

<sup>a</sup> A, significant difference between CB and NCB; B, significant difference between CB and NCBC; C, significant difference between NCB and NCBC.

crossbite side when compared with both the opposite side and control group sides. The lack of abrasion in crossbite sides was primarily due to a significantly lesser degree of abrasion of the upper deciduous canines.

The degree of abrasion has been addressed in many anthropological studies as an evaluation factor for masticatory function. Epidemiological studies<sup>3,23</sup> have defined the presence of abrasion as a physiological feature in the deciduous dentition. There is a positive correlation between masticatory function and tooth wear.<sup>24,25</sup> In the present study, crossbite sides in the deciduous dentition exhibited significantly lesser abrasion than both the contralateral side and the control group. This can be interpreted as a sign of lack of function in crossbite sides. Moreover, the significantly smaller degree of tooth abrasion in the noncrossbite side of subjects affected by unilateral crossbite when compared with the dentition of subjects with normal occlusion in the deciduous dentition suggests an alteration of function on the side without crossbite as well. These findings confirm previous observations by Ben-Bassat et al,<sup>19</sup> who demonstrated that a child affected by unilateral posterior crossbite in the deciduous dentition might present with alteration of masticatory function in both sides of the arches.

With regard to the possible clinical implications, the results of the present investigation suggest that the grinding of unabraded canines can be beneficial in the interceptive treatment of unilateral posterior crossbite in the deciduous dentition.<sup>8-11</sup> The target of early treatment of the malocclusion by tooth grinding is to eliminate occlusal interference due to unabraded teeth, which can lead to a functional lateral shift of the mandible in centric occlusion.<sup>11</sup> The reduced amount of physiological abrasion of the upper deciduous canine on the side affected by posterior crossbite appears to be significantly involved in the establishment of the occlusal interference, and therefore it should be evaluated as one of the possible objectives for interceptive grinding therapy.

## CONCLUSIONS

The findings of the present study indicate that subjects with unilateral crossbite in the deciduous dentition showed a significantly smaller degree of dental abrasion in the crossbite side when compared with both the opposite side and control group sides. The lack of abrasion in crossbite sides was primarily due to a significantly lesser degree of abrasion of the upper deciduous canines.

## ACKNOWLEDGMENTS

The authors would like to thank Dr Lorenzo Franchi and Dr Tiziano Baccetti for their assistance in statistical analysis and Dr Robert S. Corruccini for his insights on the anthropological aspects of the deciduous dentition.

## REFERENCES

1. Van Der Linden FPGM, Duterloo HS. *Development of the Human Dentition, An Atlas*. Hagerstown, Md: Harper and Row; 1976.

2. Moyers RE. *Handbook of Orthodontics*, 4th ed. Chicago, Ill: Year Book Medical Publishers; 1988.
3. Hugoson A, Ekfeldt A, Koch G, Hallonsten AL. Incisal and occlusal tooth wear in children and adolescents in a Swedish population. *Acta Odontol Scand*. 1996;54:263–270.
4. Madlena M, Keszthelyi G, Alberth M, Nagy A. The attrition of deciduous teeth. *Fogorv Sz*. 1989;82:273–276.
5. Muller H. *Introduction à la Pratique de l'Ortopédie Dentofaciale et de l'Orthodontie*. Paris, France: Ed Ageco; 1970.
6. Baccetti T, Vichi M, Tollaro I. *Role of Dentition in Early Developmental Phases of Occlusion and Malocclusion in Aspects of Dental Biology, Palaeontology, Anthropology and Evolution*. J Moggi-Cecchi, ed. Florence, Italy: Florence International Institute for the Study of Men; 1995.
7. Moyers RE, Wainright R. Skeletal contributions to occlusal development. In: McNamara JA Jr, ed. *The Biology of Occlusal Development*, Monograph 7. Craniofacial Growth Series. Ann Arbor, Mich: Center for Human Growth and Development, University of Michigan; 1977:89–111.
8. Holm AK. A longitudinal study of dental health in Swedish children aged 3–5 years. *Community Dent Oral Epidemiol*. 1975;3:222–236.
9. Kisling E, Krebs G. Patterns of occlusion in 3-year old Danish children. *Commun Dent Oral Epidemiol*. 1976;4:152–159.
10. Ravn JJ. Occlusion in primary dentition in three-year-old children. *Scan J Dent Res*. 1975;83:123–130.
11. Thilander B, Wahlund S, Lennartsson B. The effect of early interceptive therapy in children with posterior cross-bite. *Eur J Orthod*. 1984;6:25–34.
12. Foster TD, Hamilton MC. Occlusion in the primary dentition. *Br Dent J*. 1969;21:76–79.
13. Hanson ML, Barnard LW, Case JL. Tongue thrust in preschool children. Part II: dental occlusal patterns. *Am J Orthod*. 1970;57:15–22.
14. Helm S. Prevalence of malocclusion in relation to development of dentition. *Acta Odontol Scand*. 1970;28(suppl):58.
15. Järvinen S. Need for preventive and interceptive intervention for malocclusion in 3–5 year old Finnish children. *Commun Dent Oral Epidemiol*. 1981;9:1–4.
16. Kutin G, Hawes RR. Posterior cross-bite in deciduous and mixed dentitions. *Am J Orthod*. 1969;57:491–504.
17. Köhler L, Holst K. Malocclusion and sucking habits of four-year-old children. *Acta Paediatr Scand*. 1973;62:373–379.
18. Larsson E. Dummy and finger sucking habits of 4-year-olds. *Swed Dent J*. 1975;68:219–224.
19. Ben-Bassat Y, Yaffe A, Brin I, Freeman J, Ehrlich Y. Functional and morphological-occlusal aspects in children treated for unilateral posterior cross-bite. *Eur J Orthod*. 1993;15:57–63.
20. De Boer M, Rteenks MH. Functional unilateral posterior cross-bite. Orthodontic and functional aspects. *J Oral Rehabil*. 1977;24:614–623.
21. Knight DJ, Leroux BG, Zhu C, Almond J, Ramsay DS. A longitudinal study of tooth wear in orthodontically treated patients. *Am J Orthod Dentofac Orthop*. 1997;112:194–202.
22. Almond JR, Leroux BG, Knight DJ, Ramsay DS. Craniofacial morphology and tooth wear: a longitudinal study of orthodontic patients. *Angle Orthod*. 1999;69:7–13.
23. Alamoudi N. The prevalence of crowding, attrition, midline discrepancies and premature tooth loss in the primary dentition of children in Jeddah, Saudi Arabia. *J Clin Pediatr Dent*. 1999;24:53–58.
24. Corruccini RS, Whitley LD. Occlusal variation in a rural Kentucky community. *Am J Orthod*. 1981;79:250–262.
25. Corruccini RS, Townsend GC, Brown T. Occlusal variation in Australian aboriginals. *Am J Phys Anthropol*. 1990;82:257–265.