

The Role of Opioid Systems on Orthodontic Tooth Movement in Cholestatic Rats

Dorri Nilforoushan, DMD^a; Mohsen Shirazi, DMD, MSc^b; Ahmad-Reza Dehpour, PhD^c

Abstract: Endogenous opioids have been reported to accumulate in the plasma of cholestatic subjects. Another report showed that human osteoblast-like cells, MG-63, express 3 types of opioid receptors. In our laboratory we noticed that orthodontic tooth movement (OTM) is enhanced in cholestatic rats. Therefore, we suggest a possible role of opioid systems in bone remodeling and raising the rate of OTM in cholestatic conditions. To investigate this hypothesis, rat models were established and divided into 5 study groups. An orthodontic appliance, consisting of a 5 mm nickel-titanium closed coil spring, was ligated between the maxillary right incisor and first molar of each rat to deliver an initial force of 60 g. The bile duct ligated (BDL) group underwent a bile duct ligation operation and received orthodontic appliance 7 days after surgery. Another group underwent a sham operation and orthodontic appliances were inserted just as in the BDL group protocol. Surgery was performed the BDL + naltrexone group and orthodontic appliances were inserted 7 days after surgery. This group received daily subcutaneous injections of naltrexone HCl (an opioid antagonist) at 20 mg/kg at 24-hour intervals from the day of force application until the end of the study period. Another group, the naltrexone group, received naltrexone injections like the BDL + naltrexone group. A fifth control group neither underwent surgery nor received injections. Orthodontic tooth movement was measured 14 days after appliance insertion. The bile duct ligated group showed significantly increased OTM compared to all other study groups ($P < .001$). The difference between the OTM in the BDL + naltrexone and control groups was insignificant. This study suggests a role for opioid systems in OTM in cholestasis conditions. (*Angle Orthod* 2002;72:476–480.)

Key Words: Orthodontic tooth movement, Cholestasis, Opioid, Naltrexone, Rat

INTRODUCTION

Orthodontic tooth movement (OTM) is caused by a gradual remodeling of supporting alveolar bone.¹ Following orthodontic force application on the tooth, the alveolar bone on the pressure side undergoes successive cycles of bone resorption and formation, while the bone on the tension side predominantly undergoes continuous bone formation.² Systemic conditions influencing the above cycles may alter the rate of OTM.

We have previously reported on the effect of chronic renal insufficiency and hyperthyroidism on the rate of OTM

in rats.^{3,4} Cholestasis, which is impaired bile secretion, causes several systemic complications such as metabolic bone disorders.⁵ Bone loss and reduced osteoblast function has been reported in patients with cholestatic liver disease.⁶ In a previous unpublished study in our laboratory, enhanced OTM was evident in cholestatic rats. The exact mechanism affecting the bone remodeling cycle in cholestasis is still being investigated.

Endogenous opioids have been reported to accumulate in the plasma of cholestatic subjects.⁷ There is now increasing evidence for a role of opioids in the pathophysiology and manifestations of cholestasis.^{8–10} Another report showed that human osteoblast-like cells, MG-63, express 3 types of opioid receptors.¹¹ Therefore, we suggest that high levels of endogenous opioids in the plasma of cholestatic subjects may act on osteoblast-like cells and interfere with the bone remodeling cycle, increasing OTM in cholestasis. According to this hypothesis, inhibiting opioids in cholestatic subjects may influence their effect on bone and, therefore, inhibit the enhancement of OTM in cholestasis.

Several studies suggest an interaction between endogenous opioids and the nitric oxide system in the pathophysiology of many cholestatic conditions.^{12,13} In a recent study

^a Research Assistant, Department of Orthodontics, School of Dentistry, Tehran University of Medical Sciences, Tehran, Iran.

^b Associate Professor, Department of Orthodontics, School of Dentistry, Tehran University of Medical Sciences, Tehran, Iran.

^c Professor, Department of Pharmacology, School of Medicine, Tehran University of Medical Sciences, Tehran, Iran.

Corresponding author: Professor AR Dehpour, Department of Pharmacology, School of Medicine, Tehran University of Medical Sciences, PO Box: 13145–784, Tehran, Iran (e-mail: Dehpour@medscape.com).

Accepted: January 2002. Submitted: March 2002.

© 2002 by The EH Angle Education and Research Foundation, Inc.

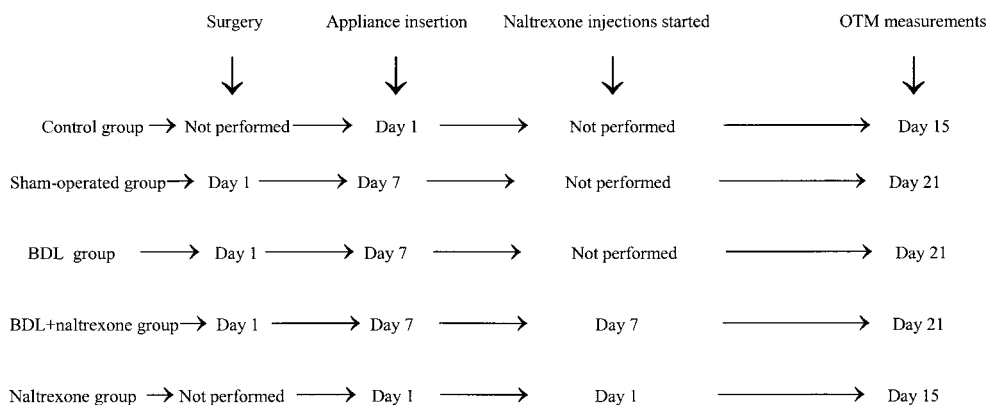


FIGURE 1. Timetable for surgery, appliance insertion, and naltrexone injections in each study group.

we suggested a role for nitric oxide in OTM in rats.¹⁴ The interaction between these 2 systems may lead to opioids influencing OTM in cholestatic conditions when opioids accumulate in plasma. The aim of the present study was to examine the effect of opioid antagonist naltrexone HCl on the rate of OTM in cholestatic rats.

MATERIALS AND METHODS

Animals

Forty male Sprague-Dawley rats with an average weight of 250 ± 20 grams were obtained from the Razi Institute (Tehran, Iran) for use in this study. The animals were acclimatized for 1 week in plastic cages with a standard 12-hour light-dark cycle. The animals were fed a diet of soft laboratory food to minimize any discomfort to the animal after orthodontic appliance insertion and to minimize the risk of appliance displacement. The study conformed to the Guide for the Care and Use of Laboratory Animals published by US National Institutes of Health (NIH Publication No 85-23, revised 1985).

This study was performed as a split-mouth design with the contralateral side of each animal serving as its own control. All the study groups received orthodontic treatment. The rats were randomly divided into 5 study groups ($N = 8$ in each group). The 5 groups were: (1) a control group that received neither an operation nor an injection; (2) a bile duct ligated (BDL) group on which bile duct ligation operation was performed; (3) a sham-operated group that underwent a sham operation; (4) a naltrexone HCl treated group that received daily subcutaneous naltrexone HCl injections of 20 mg/kg (Sigma, St Louis, Mo) from the day of force application until the end of study period¹⁵; and (5) a bile duct ligated and naltrexone HCl (BDL + naltrexone) group that underwent bile duct ligation surgery and received naltrexone HCl with the same protocol as the naltrexone group. An orthodontic appliance was placed 7 days after surgery in all groups. Figure 1 shows the timetable for surgery, appliance insertion, and naltrexone injections in each study group.

Surgery

Bile duct ligation was performed as previously described.¹⁶ Briefly, the rats in the BDL, BDL + Nal, and sham-operated groups were anesthetized with an intraperitoneal injection of ketamine 50 mg/kgbw (Ketamine Hydrochloride, Gedeon Richter Ltd, Budapest) and xylazine HCl 6 mg/kgbw (Rompoun, Bayer, Leverkusen). In the BDL and BDL + Nal groups, a laparotomy was performed on each rat and the bile duct was identified and doubly ligated so that bile could not be eliminated via the bile duct in these mentioned groups. In the sham-operated group, the bile duct was identified and manipulated, but not ligated. The abdominal wall was closed in 2 layers in all the operated groups.

Orthodontic treatment and OTM measurements

All 5 study groups received orthodontic treatment. Orthodontic appliances were placed 7 days after surgery in the BDL and BDL + Nal and sham-operated groups. Each rat was anesthetized with an intraperitoneal injection of ketamine 50 mg/kgbw and xylazine HCl 6 mg/kgbw. The orthodontic appliance used was a replication of the appliance presented by King and Fischlschweiger.¹⁷ An orthodontic force was applied with a 5.0 mm length of nickel-titanium closed-coil spring (NiTi, 3M Unitek, Monrovia, Calif, Hitek, 0.006×0.022 inch) running between the right upper first molar and incisor. The spring was fixed in place via ligature wires (Dentaurum Steel Ligature Wire 0.010 inch, Dentaurum Group, Ispringen, Germany) that surrounded the molar tooth and the incisor. Due to a lack of undercut in the incisor area, a cervical groove was prepared on the tooth where the ligature wire was seated and secured by composite resin (Self cure Degufill, Degussa AG, Frankfurt, Germany) on both incisors. Each spring was activated once to produce 60g of force. Two weeks after appliance insertion, the animals were sacrificed using an ether overdose. An additional silicone impression (President; Liechtenstein) was made and poured with ultra strength dental stone (Gildand; Germany) before removing the appliance to prevent

TABLE 1. Orthodontic Tooth Movement in the Five Study Groups*

Study Groups	Orthodontic Tooth Movement (mm)
Control	.240 ± .012
BDL**	.446 ± .015†
Sham-operated	.259 ± .015‡
BDL + Naltrexone	.271 ± .009‡
Naltrexone	.305 ± .014§ ¶

*Data are shown as mean ± standard error of mean. Sample size was eight in each study group.

** BDL indicates bile duct ligated.

† $P < .001$ compared to all other study groups.

‡ $P > .05$ compared to control group.

§ $P > .05$ compared to sham-operated group ($P = .21$).

|| $P > .05$ compared to BDL + naltrexone group ($P = .874$).

¶ $P < .05$ compared to control group ($P = .018$).

any potential relapse of tooth movement. Orthodontic tooth movements were measured on the plaster replica using a Filler Gauge (Mituto Co, Japan) to reveal the distance between the first and second right molar. This distance was initially zero. The same operator performed all measurements.

Naltrexone Injections

Naltrexone HCl was dissolved in deionized distilled water. The drug was freshly prepared on the day of injections. The naltrexone and BDL + naltrexone groups received naltrexone HCl subcutaneous injections (20 mg/kgbw) at 24-hour intervals from the first day of force application until the end of study period.¹⁵ We started the injections from the first day of force application (day 7 after BDL surgery in the BDL + naltrexone group) because it was reported

that a significant accumulation of endogenous opioids are present 5 days after BDL.⁷ Therefore, we chose day 7 to start the injections to be sure that the rise had occurred. The other groups did not receive any injection.

Statistical Analysis

Data are shown as mean ± standard error of the mean (SEM). Statistical evaluation of the data was done with the analysis of variance (ANOVA) followed by the Newman-Keuls test for multiple comparisons. A value of $P < .05$ was considered statistically significant.

RESULTS

Induction of cholestasis

Two days after bile duct ligation, the animals showed signs of cholestasis (jaundice, dark urine, and steatorrhea). These manifestations were not seen in any animal in the sham-operated group.

Orthodontic tooth movement measurements

All appliance-treated molars showed evidence of tooth movement. No tooth movement was noted in the nonappliance side. Orthodontic tooth movement measurements for all the study groups are shown in Table 1 and Figure 2.

DISCUSSION

Tooth movement in the BDL group was significantly increased compared to the control, naltrexone-treated, sham-operated, and BDL + naltrexone groups ($P < .001$). The differences between the amount of OTM in the sham-op-

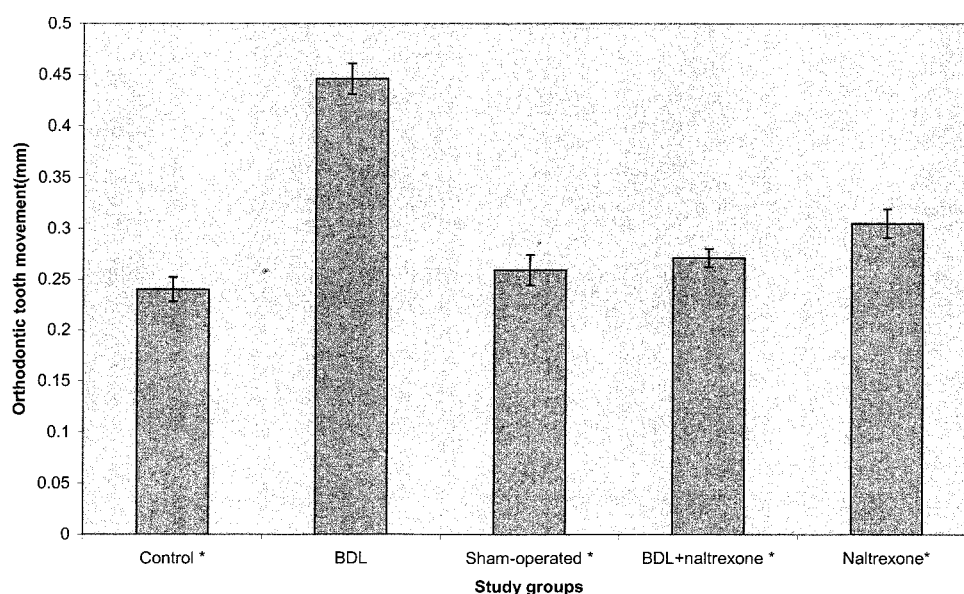


FIGURE 2. Orthodontic tooth movement measurements in 5 study groups. * $P < .001$ for control, sham-operated, naltrexone, BDL + naltrexone groups measurements compared to BDL group. Data are shown as mean ± SEM. Sample size was 8 in each study group.

erated and the BDL + naltrexone groups compared to the control animals as well as naltrexone-treated group were insignificant ($P > .05$).

Since there was no significant difference between the OTM of the control and sham-operated groups, the operation itself does not affect OTM. These results show that bile duct ligation (cholestasis) enhances OTM. Insignificant difference between OTM of control and BDL + naltrexone groups reveals the possible role of naltrexone in inhibiting the rise in OTM caused by cholestasis.

Jaundice, dark urine, and steatorrhea are signs of cholestasis in rats. Other investigators observed the same signs after bile duct ligation.^{12,13} Cholestatic liver disease is associated with osteopenia and impairment of bone remodeling mechanisms.¹⁸ Since cholestasis results in intraluminal deficiency of bile salts in the small bowel, and because these bile salts are essential for vitamin D absorption, early investigators thought that the osteopenia in cholestatic patients was most likely osteomalacia. However, in randomized clinical trials long-term vitamin D therapy with maintenance of normal serum levels was ineffective in the treatment of cholestasis-induced osteopenia.^{19,20} In addition, no defect in mineralization has been found in cholestatic osteopenia.¹⁸ The underlying mechanism of bone defect in cholestasis is unknown, but reduced osteoblast function and decrease of insulin-like growth factor 1 levels have been reported in patients with cholestatic liver disease.^{6,21}

It has been suggested that cholestatic liver disease is associated with increased neurotransmission mediated by an opioid system. Observations compatible with this hypothesis include precipitation of an opioid withdrawal-like syndrome in patients with cholestasis as well as in the mice model of cholestasis by administration of an opioid antagonist²²⁻²⁴ and a global down regulation of μ -opioid receptors in the brain of BDL rats.²⁵ It has been shown that cholestasis in rats is associated with naloxone-reversible antinociception²⁶ and plasma total opioid activity was 3 times greater in BDL rats than in sham-operated control animals.⁷ The precise reason for increased opioid activity in cholestasis is not completely understood, but it is likely that both overproduction of endogenous opioids and protection of these peptides from degradation may contribute to the elevation of total opioid activity.^{7,27} Adrenal production of proenkephalin A mRNA and BAM-22p (an adrenal-derived potent opioid agonist) is significantly increased in cholestatic rats,²⁷ while protection of methionine-enkephalin from degradation may be another factor contributing to the increased plasma level of methionine-enkephalin found in cholestatic subjects.⁷

The activity of both exogenous and endogenous opioids is mediated through specific cell surface receptors that have been classified into 3 main groups termed mu, delta, and kappa.^{28,29,30} Although the presence of opioid receptors is better known in the central nervous system,^{29,30} its occurrence has also been described in other tissues.^{29,31,32} Rosen

et al³³ demonstrated that Proenkephalin- (PENK) derived peptides inhibited the activity of alkaline phosphatase in the rat osteosarcoma-derived cell line reactive oxygen species (ROS) 17/2.8, suggesting the existence of opioid receptors in osteoblasts. Later these authors demonstrated the presence of specific mRNA of kappa receptors in rat osteoblasts.³⁴

A recent study showed that human osteoblast-like cells, MG-63, also present immunohistochemical reactivity of mu, delta, and kappa opioid receptors and express the 3 types of opioid receptor genes. This study found that a high concentration of morphine inhibits the 1,25 (OH)₂D₃-induced osteocalcin secretion. Furthermore, the reduction in osteocalcin synthesis was abolished when osteoclastic cells were incubated simultaneously with high concentrations of morphine and naloxone.¹¹

The present study shows that orthodontic tooth movement is increased in cholestatic condition, but naltrexone injections will inhibit this increase. This may suggest that higher opioid amounts in cholestatic subjects act on either osteoblasts or osteoblast-like cell receptors for opioids to alter bone remodeling and, therefore, lead to an increased rate of tooth movement. Our results are compatible with this possible interaction. While the rate of OTM of the naltrexone treated group didn't change significantly compared to the sham-operated and BDL + naltrexone groups, it was increased significantly compared to the control group ($P = .018$). This reveals that naltrexone injections are not the cause of the decreased rate of OTM in the BDL + naltrexone group as compared to the BDL group. However, it may suggest a possible role for naltrexone in OTM and bone remodeling in normal subjects, which is completely different from its effect in cholestasis. A similar effect was previously observed in our laboratory.¹² These effects deserve further studies.

CONCLUSION

Orthodontic tooth movement was significantly increased in cholestatic rats. By administering an opioid antagonist (naltrexone) to cholestatic rats, this increase did not take place and OTM did not show any significant differences compared to the control group.

REFERENCES

1. Norevall LI, Forsgren S, Matson L. Expression of neuropeptides during and after orthodontic tooth movement in rat. *Eur J Orthod.* 1995;17:311-325.
2. Kobayashi Y, Sakai H, Mataka S, Kato Y. Effects of local administration of osteocalcin on experimental tooth movement. *Angle Orthod.* 1998;68:259-265.
3. Shirazi M, Khosrowshahi M, Dehpour AR. The effect of chronic renal insufficiency on orthodontic tooth movement in rats. *Angle Orthod.* 2001;71:494-498.
4. Shirazi M, Dehpour AR, Jafari F. The effect of thyroid hormone on orthodontic tooth movement in rats. *Clin Pediatr Dent.* 1999; 23:259-264.

5. Guanabens N, Pares A, Marinoso L, Brancos MA, Piera C, Serano S, Rivera F, Rodes J. Factors influencing the development of metabolic bowel disease in primary biliary cirrhosis. *Am J Gastroenterol.* 1990;85:1356-1362.
6. Hodgson SF, Dickson ER, Wahner HW, Johnson KA, Mann KG, Riggs BL. Bone loss and reduced osteoblast function in primary cirrhosis. *Ann Intern Med.* 1985;103:855-860.
7. Swain MG, Rothman RB, Xu H, Vergalla H, Bergasa NV, Jones EA. Endogenous opioids accumulate in plasma in a rat model of acute cholestasis. *Gastroenterology.* 1992;103:630-635.
8. Dehpour AR, Mani AR, Amanlou M, Nahavandi A, Amanpour S, Bahadori M. Naloxone is protective against indomethacin-induced gastric damage in cholestatic rats. *J Gastroenterol.* 1999;34:178-181.
9. Dehpour AR, Rastegar H, Jorjani M, Roushanzamir F, Joharchi K, Ahmadiani A. Subsensitivity to opioids is receptor-specific in isolated guinea pig ileum and mouse *vas deferens* after obstructive cholestasis. *J Pharmacol Exp Ther.* 2000;293:946-951.
10. Jones EA, Bergasa NV. Evolving concepts of the pathogenesis and treatment of the pruritus of cholestasis. *Can J Gastroenterol.* 2000;14:33-40.
11. Perez-Castrillon JL, Olmos JM, Gomez JJ, Barrallo A, Riancho JA, Perera L, Valero C, Amado JA, Gonzalez-Macias J. Expression of opioid receptors in osteoblast-like MG-63 cells, and osteocalcin secretion by these cells. *Neuroendocrinology.* 2000;72:187-194.
12. Namiranian K, Samini M, Ejtemaei Mehr S, Gaskari SA, Rastegar H, Homayoun H, Dehpour AR. Mesenteric vascular bed responsiveness in bile duct-ligated rats: roles of opioid and nitric oxide systems. *Eur J Pharmacol.* 2001;423:185-193.
13. Nahavandi A, Mani AR, Homayounfar H, Akbari MR, Dehpour AR. The role of the interaction between endogenous opioids and nitric oxide in the pathophysiology of ethanol-induced gastric damage in cholestatic rats. *Fundam Clin Pharmacol.* 2001;15:181-187.
14. Shirazi M, Nilforoushan D, Dehpour AR. The role of nitric oxide on orthodontic tooth movement in rats. *Angle Orthod.* 2002;72:211-215.
15. Way WL, Fields HL, Way LW. Opioid analgesics and antagonists. In: Katzung BG, ed. *Basic and Clinical Pharmacology.* 7th ed. Norwalk, Conn: Appleton & Lange;1998:496-515.
16. Nahavandi A, Dehpour AR, Mani AR, Homayounfar H, Abdoli A. N(ω)-nitro-L-arginine methylester is protective against ethanol-induced gastric damage in cholestatic rats. *Eur J Pharmacol.* 1999;370:283-286.
17. King GJ, Fischlschweiger W. The effect of force magnitude on extractable bone resorptive activity and cemental cratering in orthodontic tooth movement. *J Dent Res.* 1982;61:775-779.
18. Hay JE. Bone disease in cholestatic liver disease. *Gastroenterology.* 1995;108:276-283.
19. Long RG, Meihard E, Skinner RK, Varghese Z, Wills MR, Sherlock S. Clinical, biochemical and histological studies of osteomalacia, osteoporosis, and parathyroid function in chronic liver disease. *Gut.* 1978;19:85-90.
20. Herlong HF, Becker RR, Maddrey WC. Bone disease in primary biliary cirrhosis: histologic features and response to 25-hydroxy vitamin D. *Gastroenterology.* 1982;83:103-108.
21. Bucuvalace JC, Cutfield W, Horn J, Sperling MA, Heubi JE, Campigne B, Chaemausek SD. Resistance to the growth-promoting and metabolic effects of growth hormone in children with chronic liver disease. *J Pediatr.* 1990;117:397-402.
22. Thornton JR, Losowsky MS. Opioid peptides and primary biliary cirrhosis. *Brit Med J.* 1988;297:1501-1504.
23. Ghafourifar P, Dehpour AR, Akbarloo N. Inhibition by L-NA, a nitric oxide synthase inhibitor, of naloxone-precipitated withdrawal signs in a mouse model cholestasis. *Life Sci.* 1997;60:265-270.
24. Dehpour AR, Meysami F, Ebrahimi-Daryani N, Akbarloo N. Inhibition by lithium of opioid withdrawal-like syndrome and physical dependency in a model of acute cholestasis in mice. *Hum Psychopharmacol Clin Exp.* 1998;13:407-412.
25. Bergasa NV, Rothman RB, Vergalla J, Xu H, Swain MG, Jones EA. Central mu-opioid receptors are down-regulated in rat model of cholestasis. *J Hepatol.* 1992;15:220-225.
26. Bergasa NV, Alling DW, Vergalla J, Xu H, Swain MG, Jones EA. Cholestasis in the male rat is associated with naloxone-reversible antinociception. *J Hepatol.* 1994;20:85-90.
27. Swain MG, MacArthur L, Vergalla J, Jones EA. Adrenal secretion of BAM-22P, a potent opioid peptide, is enhanced in rats with acute cholestasis. *Am J Physiol.* 1994;266:G201-G205.
28. Holt V. Opioid peptide genes: Structure and regulation. In: Almeida OF, Shippenberg TS, eds. *Neurobiology of Opioids.* Berlin: Springer Verlag; 1991:11-51.
29. Simon EJ. Multiple opioid receptors. I: *Neurobiology of opioids.* Almeida OFX, Shippenberg TS, eds. Berlin: Springer Verlag; 1991:75-88.
30. Brownstien MJ. A brief history of opiate, opioid peptides, and opioid receptors. *Proc Natl Acad Sci USA.* 1993;90:5391-5393.
31. Mansson E, Bare L, Yang D. Isolation of a human kappa opioid receptor cDNA from placenta. *Biochem Biophys Res Commun.* 1994;202:1431-1437.
32. Barrallo A, Gonzalez-Sarmiento R, Santos MV, Rodriguez R. RT-PCR detection of opioid receptor mRNA in different tissues. *Analgesia.* 1995;1:272-277.
33. Rosen H, Polakiewicz RD, Benzakine S, Bar-Shavit ZB. Proenkephaline A in bone-derived cells. *Proc Natl Acad Sci USA.* 1991;88:3705-3709.
34. Rosen H, Metzger E, Benzakine S, Bar-Shavit Z. Functional opioid receptors on skeletal cells. *J Bone Miner Res.* 1997;12(suppl):411.