



## ERRATUM

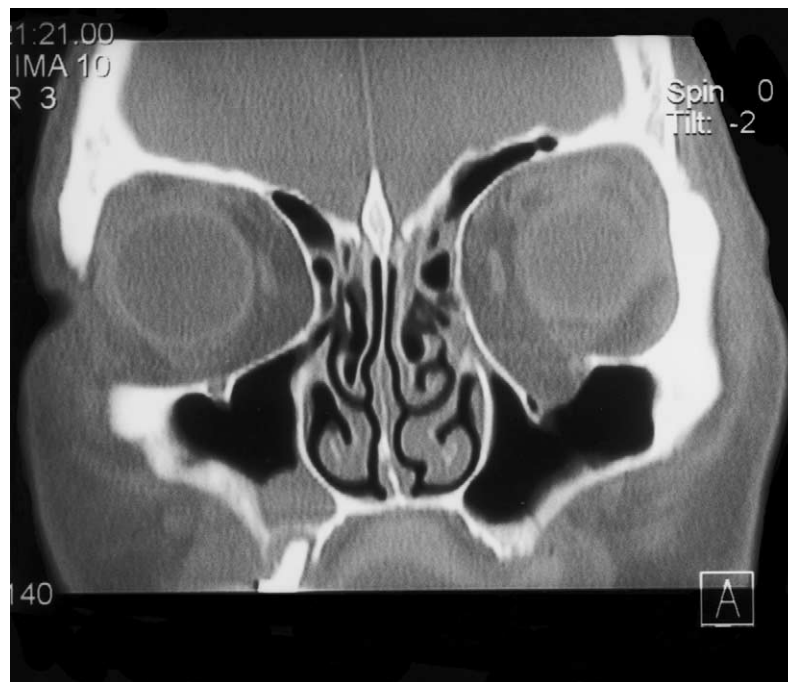
### The custom-made titanium orbital floor prosthesis in reconstruction for orbital floor fractures.

[Br J Oral Maxillofac Surg 2003; 41: 50–53]<sup>☆</sup>

C. W. Hughes,<sup>\*</sup> K. Page,<sup>†</sup> R. Bibb,<sup>‡</sup> J. Taylor,<sup>§</sup> P. Revington<sup>¶</sup>

<sup>\*</sup>Specialist Registrar; <sup>†</sup>Chief Maxillofacial Technician, Frenchay Hospital, Bristol BS16 1LE, UK; <sup>‡</sup>Research Fellow – Medical Applications, The National Centre for Product Design and Development Research (PDR), Cardiff, UK; <sup>§</sup>Superintendent CT Radiographer; <sup>¶</sup>Consultant, Frenchay Hospital, Bristol BS16 1LE, UK

The Publisher would like to apologise for printing Fig. 1 (on page 51) incorrectly. The figure should have appeared as follows:



**Fig. 1** Coronal computed tomogram showing classic orbital blow-out fracture.

<sup>☆</sup> doi of original article 10.1016/S0266-4356(02)00249-8.