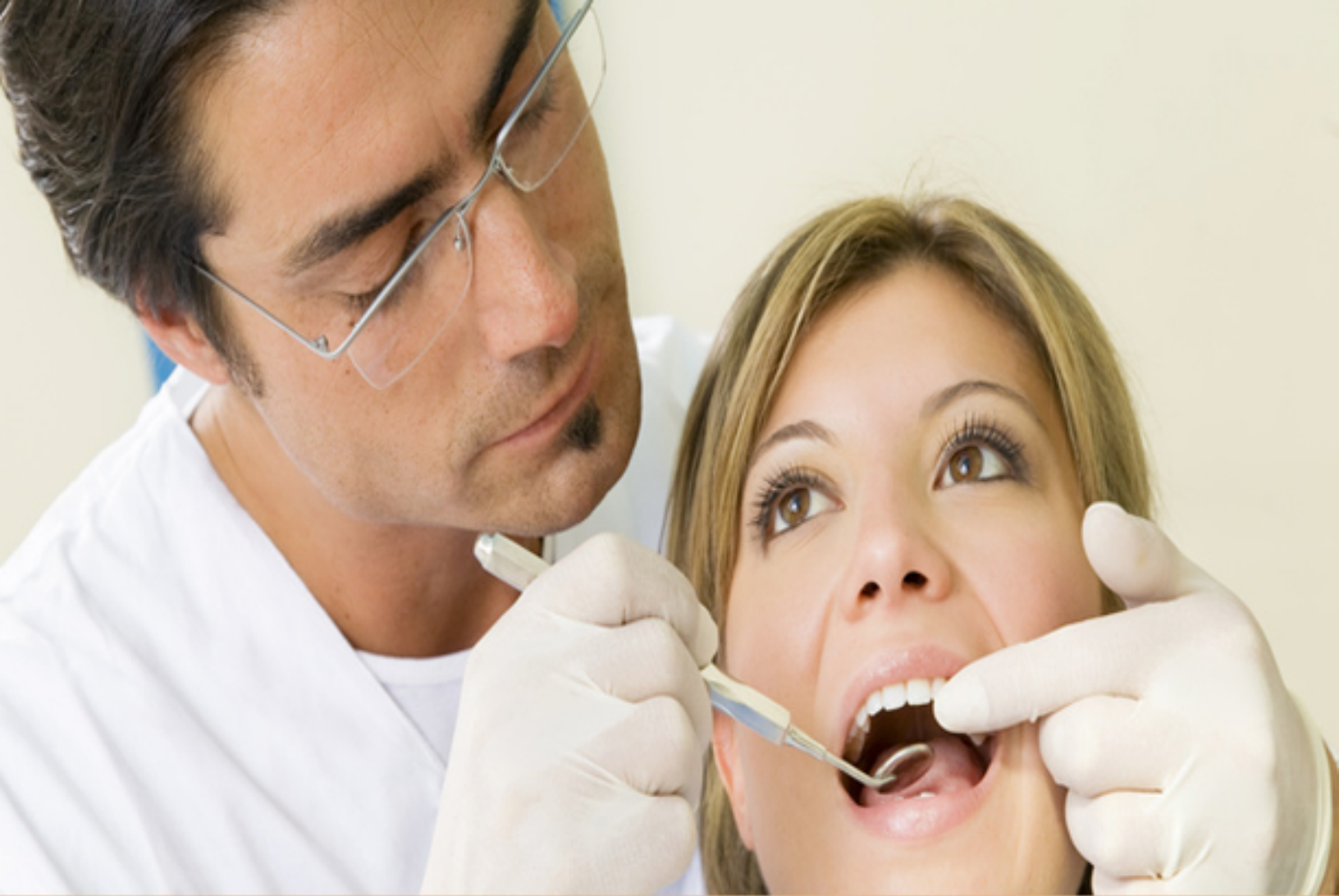



Oral Pathology and Dentistry

Iola Labelle

Marin Winstead

First Edition, 2012

ISBN 978-81-323-1425-7

© All rights reserved.

Published by:

College Publishing House

4735/22 Prakashdeep Bldg,

Ansari Road, Darya Ganj,

Delhi - 110002

Email: info@wtbooks.com

Table of Contents

Chapter 1 - Mouth Disease

Chapter 2 - Mumps

Chapter 3 - Aphthous Ulcer

Chapter 4 - Oral Cancer

Chapter 5 - Ameloblastoma

Chapter 6 - Dental Caries

Chapter 7 - Gingivitis

Chapter 8 - Leukoplakia and Mucous Cyst of the Oral Mucosa

Chapter 9 - Periodontitis

Chapter 10 - Warthin's Tumor

Chapter 11 - Dentistry

Chapter 12 - Crown (Dentistry)

Chapter 13 - Dental Restorative Materials

Chapter 14 - Dental Restoration

Chapter 15 - Dental Braces

Chapter 16 - Dental Drill

Chapter 17 - Dental Extraction

Chapter 18 - Dental Implant

Chapter 1

Mouth Disease

Mouth disease	
ICD-10	K00.-K14.
ICD-9	520-529
MeSH	D009057

Stomatognathic disease or **mouth disease** refers to the diseases of the mouth ("stoma") and jaw ("gnath"). The etymology is similar to that of the term Gnathostomata. It is the term used by MeSH (along with the synonym **dental diseases**), but other organizations use different terms.

The mouth is an important organ with many different functions. It is also prone to a variety of medical and dental disorders.

The American Dental Association uses the term "oral and maxillofacial pathology", and describes it as "the specialty of dentistry and pathology which deals with the nature, identification, and management of diseases affecting the oral and maxillofacial regions. It is a science that investigates the causes, processes and effects of these diseases."

The World Health Organization uses the term "Diseases of oral cavity, salivary glands and jaws."

Salivary glands

There are both major-major and minor-minor salivary gland in the mouth which secrete saliva and a variety of enzymes to help process foods and make swallowing easy. These salivary glands can get infected or inflamed and can also be very painful; sometimes the salivary glands also develop benign and malignant cancers. However, the most common problem with salivary gland is formation of stones in the small ducts which prevent free flowing of saliva. The gland swells as they cannot empty and often get infected. While most stones in the duct may resolve, sometimes surgery and antibiotics are required.

Mumps

Mumps of the salivary glands is a viral infection of the parotid glands. This results in painful swelling at the sides of the mouth in both adults and children. The infection is quite contagious. Today mumps is prevented by getting vaccinated in infancy. There is no specific treatment for mumps except for hydration and Tylenol. Sometimes mumps can cause inflammation of the brain, testicular swelling or hearing loss.

Bad breath

Bad breath (halitosis) has many causes including smoking, alcohol, poor care of dentures, gum disease, chronic lung disease, breathing through the mouth, sinusitis, liver disease, diabetes, pregnancy, not brushing or flossing on a regular basis. Medications that cause dryness in the mouth can also cause bad breath. These include antidepressants, anti histamines and antipsychotics. The best way to prevent bad breath is to brush teeth frequently, clean the tongue, keep the nose and sinus clean and drink adequate water.

Canker sores

Canker sores are small ulcers that appear on the inside of the mouth, lips and on tongue. Most small canker sores disappear within 10-14 days. Canker sores are most common in young and middle aged individuals. Sometimes individuals with allergies are more prone to these sores. Besides an awkward sensation, these sores can also cause tingling or a burning sensation. Unlike herpes sores, canker sores are always found inside the mouth and are usually less painful. Good oral hygiene does help but sometime one may have to use a topical corticosteroid.

Fungus infections

Candida is a very common infection of the mouth in immunocompromised individuals. Individuals who have undergone a transplant, HIV, cancer or use corticosteroids commonly develop candida of the mouth and oral cavity. The typical signs are a white patch that may be associated with burning, soreness, irritation or a white cheesy like appearance. Once the diagnosis is made, candida can be treated with a variety of anti fungal drugs.

Herpes

Another very common disorder of the oral cavity is herpes simplex infection (HSV). This virus causes blisters and sores around the mouth and lips. HSV infections are not only annoying but also painful and may keep on recurring. Although many people get infected with the virus, only 10% actually develop the sores. The sores may last anywhere from 3-10 days and are very infectious. Some people have recurrences either in the same location or at a nearby site. Recurrent infections tend to be mild in nature and may be brought on by stress, sun, menstrual periods, trauma or physical stress.

Burning mouth

Burning mouth syndrome (BMS) is a very painful annoying disorder that causes a sensation of burning on the lips, tongue, mouth and gums. The disorder can affect anyone but tends to occur most often in middle aged women. BMS has been linked to a variety of dental and medical disorders like menopause, dry mouth and allergies. Some individual develop one episode of BMS and others develop recurrent episodes which last months or years. Other features of this distressing disorder include anxiety, depression and social isolation. There is no cure for this disorder and treatment includes use of hydrating agents, pain medications, vitamin supplements or the usage of antidepressants.

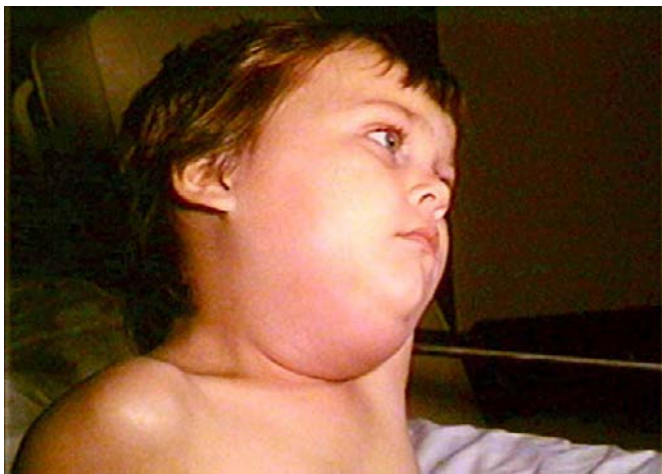Cancers

Oral cancer may occur on the lips, tongue, gums, floor of the mouth or inside the cheeks. The majority of cancers of the mouth are known as squamous cell cancers. Oral cancers are usually painless in the initial stages or may appear like an ulcer. Causes of oral cancer include smoking, excessive alcohol consumption, exposure to sunlight (lip cancer), chewing tobacco, and infection with the human Human papillomavirus. The earlier the oral cancer is diagnosed, the better the chances for full recovery. If you have a suspicious mass or ulcer on the mouth which has been persistent, then you should always get a dentist to look at it. Diagnosis is usually made with a biopsy and the treatment depends on the exact type of cancer, where it is situated, and extent of spreading.

Chapter 2

Mumps

Mumps



Child with mumps.

ICD-10	B26.
ICD-9	072
DiseasesDB	8449
MedlinePlus	001557
eMedicine	emerg/324 emerg/391 ped/1503
MeSH	D009107

Mumps and **epidemic parotitis** is a viral disease of the human species, caused by the mumps virus. Before the development of vaccination and the introduction of a vaccine, it was a common childhood disease worldwide. It is still a significant threat to health in the third world, and outbreaks still occur sporadically in developed countries.

Painful swelling of the salivary glands (classically the parotid gland) is the most typical presentation. Painful testicular swelling (orchitis) and rash may also occur. The symptoms are generally not severe in children. In teenage males and men, complications such as infertility or subfertility are more common, although still rare in absolute terms. The disease is generally self-limited, running its course before receding, with no specific treatment apart from controlling the symptoms with pain medication.

Signs and symptoms

The more common symptoms of mumps are:

- Parotid inflammation (or parotitis) in 60–70% of infections and 95% of patients with symptoms. Parotitis causes swelling and local pain, particularly when chewing. It can occur on one side (unilateral) but is more common on both sides (bilateral) in about 90% of cases.
- Fever
- Headache
- Orchitis, referring to painful inflammation of the testicle. Males past puberty who develop mumps have a 30 percent risk of orchitis.

Other symptoms of mumps can include dry mouth, sore face and/or ears and occasionally in more serious cases, loss of voice. In addition, up to 20% of persons infected with the mumps virus do not show symptoms, so it is possible to be infected and spread the virus without knowing it.

Prodrome

Fever and headache are prodromal symptoms of mumps, together with malaise and anorexia.

Cause

Mumps is a contagious disease that is spread from person to person through contact with respiratory secretions such as saliva from an infected person. When an infected person coughs or sneezes, the droplets aerosolize and can enter the eyes, nose, or mouth of another person. Mumps can also be spread by sharing food and drinks. The virus can also survive on surfaces and then be spread after contact in a similar manner. A person infected with mumps is contagious from approximately 6 days before the onset of symptoms until about 9 days after symptoms start. The incubation period (time until symptoms begin) can be from 14–25 days but is more typically 16–18 days.

Diagnosis

A physical examination confirms the presence of the swollen glands. Usually the disease is diagnosed on clinical grounds and no confirmatory laboratory testing is needed. If there is uncertainty about the diagnosis, a test of saliva, or blood may be carried out; a newer

diagnostic confirmation, using real-time nested polymerase chain reaction (PCR) technology, has also been developed. An estimated 20%-30% of cases are asymptomatic. As with any inflammation of the salivary glands, serum amylase is often elevated.

Prevention

The most common preventative measure against mumps is immunization with a mumps vaccine, invented by Maurice Hilleman at Merck. The vaccine may be given separately or as part of the MMR immunization vaccine which also protects against measles and rubella. In the US, MMR is now being supplanted by MMRV, which adds protection against chickenpox. The WHO (World Health Organization) recommends the use of mumps vaccines in all countries with well-functioning childhood vaccination programmes. In the United Kingdom it is routinely given to children at age 15 months. The American Academy of Pediatrics recommends the routine administration of MMR vaccine at ages 12–15 months and at 4–6 years. In some locations, the vaccine is given again between 4 to 6 years of age, or between 11 and 12 years of age if not previously given. The efficacy of the vaccine depends on the strain of the vaccine, but is usually around 80%. The Jeryl Lynn strain is most commonly used in developed countries but has been shown to have reduced efficacy in epidemic situations. The Leningrad-Zagreb strain commonly used in developing countries appears to have superior efficacy in epidemic situations.

Because of the outbreaks within college and university settings, many governments have established vaccination programs to prevent large-scale outbreaks. In Canada, provincial governments and the Public Health Agency of Canada have all participated in awareness campaigns to encourage students ranging from grade 1 to college and university to get vaccinated.

Some anti-vaccine activists protest against the administration of a vaccine against mumps, claiming that the attenuated vaccine strain is harmful, and/or that the wild disease is beneficial. There is very little evidence to support the claim that the wild disease is beneficial, or that the MMR vaccine is harmful. Claims have been made that the MMR vaccine is linked to autism and inflammatory bowel disease, including one study by Andrew Wakefield (paper retracted in 2010) that indicated a link between gastrointestinal disease, autism, and the MMR vaccine. However, all further studies since that time have indicated no link between vaccination with the MMR and autism. Since the dangers of the disease are well known, while the dangers of the vaccine are quite minimal, most doctors recommend vaccination.

The WHO, the American Academy of Pediatrics, the Advisory Committee on Immunization Practices of the Centers for Disease Control and Prevention, the American Academy of Family Physicians, the British Medical Association and the Royal Pharmaceutical Society of Great Britain currently recommend routine vaccination of children against mumps. The British Medical Association and Royal Pharmaceutical Society of Great Britain had previously recommended against general mumps vaccination, changing that recommendation in 1987. In 1988 it became United Kingdom

government policy to introduce mass child mumps vaccination programmes with the MMR vaccine, and MMR vaccine is now routinely administered in the UK.

Before the introduction of the mumps vaccine, the mumps virus was the leading cause of viral meningoencephalitis in the United States. However, encephalitis occurs rarely (less than 2 per 100,000). In one of the largest studies in the literature, the most common symptoms of mumps meningoencephalitis were found to be fever (97%), vomiting (94%) and headache (88.8%). The mumps vaccine was introduced into the United States in December 1967: since its introduction there has been a steady decrease in the incidence of mumps and mumps virus infection. There were 151,209 cases of mumps reported in 1968. Since 2001, the case average was only 265 per year, excluding an outbreak of >6000 cases in 2006 attributed largely to university contagion in young adults.

Treatment

There is no specific treatment for mumps. Symptoms may be relieved by the application of intermittent ice or heat to the affected neck/testicular area and by acetaminophen/paracetamol (Tylenol) for pain relief. Aspirin is not used due to a hypothetical link with Reye's syndrome. Warm salt water gargles, soft foods, and extra fluids may also help relieve symptoms. According to the Department of Health of Minnesota there is no effective post-exposure recommendation to prevent secondary transmission, as well as the post-exposure use of vaccine or Immune Globulin is not effective.

Patients are advised to avoid fruit juice or any acidic foods, since these stimulate the salivary glands, which can be painful.

Prognosis

Death is very unusual. The disease is self-limiting, and general outcome is good, even if other organs are involved.

Known complications of mumps include:

- Infection of other organ systems
- Mumps viral infections in adolescent and adult males carry an up to 30% risk that the testes may become infected (orchitis or epididymitis), which can be quite painful; about half of these infections result in testicular atrophy, and in rare cases sterility can follow.
- Spontaneous abortion in about 27% of cases during the first trimester of pregnancy.
- Mild forms of meningitis in up to 10% of cases (40% of cases occur without parotid swelling)
- Oophoritis (inflammation of ovaries) in about 5% of adolescent and adult females, but fertility is rarely affected.
- Pancreatitis in about 4% of cases, manifesting as abdominal pain and vomiting

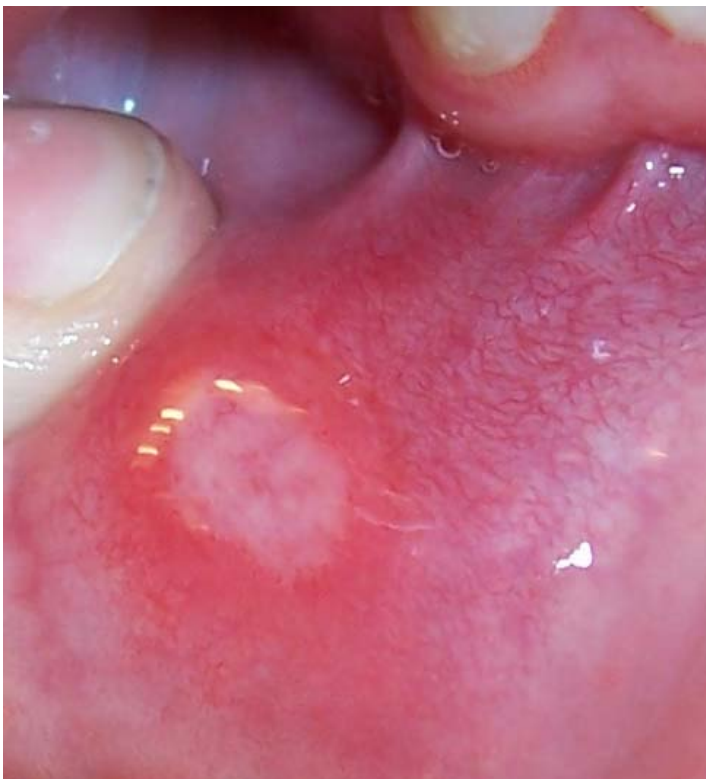- Encephalitis (very rare, and fatal in about 1% of the cases when it occurs)
- Profound (91 dB or more) but rare sensorineural hearing loss, uni- or bilateral.
Acute unilateral deafness occurs in about 0.005% of cases.

After the illness, life-long immunity to mumps generally occurs; reinfection is possible but tends to be mild and atypical.

Chapter 3

Aphthous Ulcer

Aphthous ulcer



Mouth ulcer on the lower lip

ICD-10	K12.0
ICD-9	528.2
MedlinePlus	000998
eMedicine	ent/700 derm/486 ped/2672
MeSH	D013281

An **aphthous ulcer** also known as a **canker sore**, is a type of mouth ulcer, appears as a painful open sore inside the mouth or upper throat characterized by a break in the mucous membrane. Its cause is unknown, but they are not contagious. The condition is also known as **aphthous stomatitis**, and alternatively as **Sutton's Disease**, especially in the case of major, multiple, or recurring ulcers.

The term ***aphtha*** means **ulcer**; it has been used for many years to describe areas of ulceration on mucous membranes. Aphthous stomatitis is a condition characterized by recurrent discrete areas of ulceration that are almost always painful. Recurrent aphthous stomatitis (RAS) can be distinguished from other diseases with similar-appearing oral lesions, such as certain oral bacteria or herpes simplex, by their tendency to recur, and their multiplicity and chronicity. Recurrent aphthous stomatitis is one of the most common oral conditions. At least 10% of the population has it, and women are more often affected than men. About 30–40% of patients with recurrent aphthae report a family history.

Classification

Aphthous ulcers are classified according to the diameter of the lesion.

Minor ulceration

"Minor aphthous ulcers" indicate that the lesion size is between 3 mm (0.1 in)-10 mm (0.4 in). The appearance of the lesion is that of an erythematous halo with yellowish or grayish color. Pain that affects quality of life is the obvious characteristic of the lesion. When the ulcer is white or grayish, the ulcer will be extremely painful and the affected lip may swell. They may last about 2 weeks.

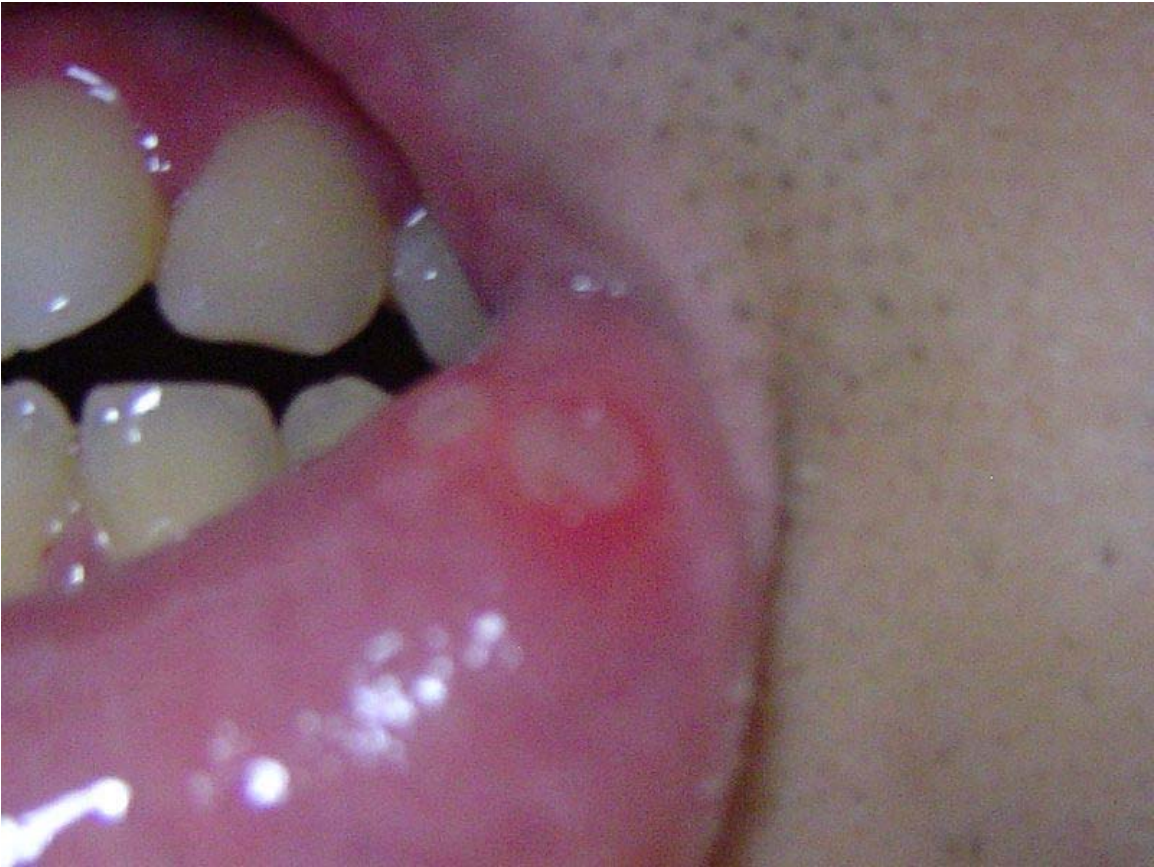Major ulcerations

Major aphthous ulcers have the same appearance as minor ulcerations, but are greater than 10 mm in diameter and are extremely painful. They usually take more than a month to heal, and frequently leave a scar. These typically develop after puberty with frequent recurrences. They occur on movable non-keratinizing oral surfaces, but the ulcer borders may extend onto keratinized surfaces.

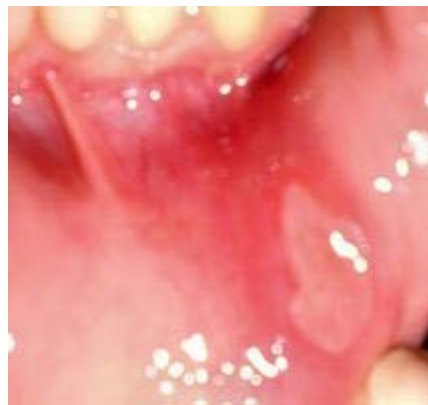Herpetiform ulcerations

This is the most severe form. It occurs more frequently in females, and onset is often in adulthood. It is characterized by small, numerous, 1–3 mm lesions that form clusters. They typically heal in less than a month without scarring. Supportive treatment is almost always necessary.

Signs and symptoms



Aphthous ulcer



Large aphthous ulcer on the lower lip

Aphthous ulcers usually begin with a tingling or burning sensation at the site of the future aphthous ulcer. In a few days, they often progress to form a red spot or bump, followed by an open ulcer.

The aphthous ulcer appears as a white or yellow oval with an inflamed red border. Sometimes a white circle or halo around the lesion can be observed. The gray-, white-, or yellow-colored area within the red boundary is due to the formation of layers of fibrin, a protein involved in the clotting of blood. The ulcer, which itself is often extremely painful, especially when agitated, may be accompanied by a painful swelling of the lymph nodes below the jaw, which can be mistaken for toothache; another symptom is fever. A sore on the gums may be accompanied by discomfort or pain in the teeth.

Causes

The exact cause of many aphthous ulcers is unknown but citrus fruits (e.g., oranges and lemons), physical trauma, stress, lack of sleep, sudden weight loss, food allergies, immune system reactions, and deficiencies in vitamin B₁₂, iron, and folic acid may contribute to their development. Nicorandil and certain types of chemotherapy are also linked to aphthous ulcers. One recent study showed a strong correlation with allergies to cow's milk. Aphthous ulcers are a major manifestation of Behçet disease, and are also common in people with Crohn's disease.

Trauma to the mouth is the most common trigger. Physical trauma, such as that caused by toothbrush abrasions, laceration with sharp or abrasive foods (such as toast, potato chips or other objects, like toothbrushes), accidental biting (particularly common with sharp canine teeth), after losing teeth, or dental braces can cause aphthous ulcers by breaking the mucous membrane. Other factors, such as chemical irritants or thermal injury, may also lead to the development of ulcers. Using a toothpaste without sodium lauryl sulfate (SLS) may reduce the frequency of aphthous ulcers. One smaller study found no connection between SLS in toothpaste and aphthous ulcers. Celiac disease has been suggested as a cause of aphthous ulcers; small studies of patients (33% or 1 out of 3) with Celiac disease did demonstrate a conclusive link between the disease and aphthous ulcers vs control group (23%) but some patients benefited from eliminating gluten from their diets.

There is no indication that aphthous ulcers are related to menstruation, pregnancy, and menopause. Smokers appear to be affected less often.

Prevention

Oral and dental measures

- Regular use of non-alcoholic mouthwash may help prevent or reduce the frequency of sores. In fact, informal studies suggest that mouthwash may help to temporarily relieve pain.
- In some cases, switching toothpastes can prevent aphthous ulcers from occurring, with research looking at the role of sodium dodecyl sulfate (sometimes called sodium lauryl sulfate, or with the acronyms SDS or SLS), a detergent found in most toothpastes. Using toothpaste free of this compound has been found in several studies to help reduce the amount, size, and recurrence of ulcers.

- Dental braces are a common physical trauma that can lead to aphthous ulcers and the dental bracket can be covered with wax to reduce abrasion of the mucosa. Avoidance of other types of physical and chemical trauma will prevent some ulcers, but, since such trauma is usually accidental, this type of prevention is not usually practical.

Nutritional therapy

- Zinc deficiency has been reported in people with recurrent aphthous ulcers. The few small studies looking into the role of zinc supplementation have mostly reported positive results particularly for those people with deficiency, although some research has found no therapeutic effect.

Treatment

A number of different treatments exist for aphthous ulcers including: analgesics, anesthetics agents, antiseptics, anti-inflammatory agents, steroids, sucralfate, tetracycline suspension, and silver nitrate.

Amlexanox paste has been found to speed healing and alleviate pain.

Vitamin B₁₂ has been found to be effective in treating recurrent aphthous ulcers, regardless of whether there is a vitamin deficiency present.

While dietary supplements of L-lysine can be effective in treating cold sores/herpetic lesions, there is no evidence of an impact on canker sores.

Suggestions to reduce the pain caused by an ulcer include: avoiding spicy food, rinsing with salt water or over-the-counter mouthwashes, proper oral hygiene and non-prescription local anesthetics. Active ingredients in the latter generally include benzocaine, benzydamine or choline salicylate.

Anesthetic mouthwashes containing benzydamine hydrochloride have not been shown to reduce the number of new ulcers or significantly reduce pain, and evidence supporting the use of other topical anesthetics is very limited, though some individuals may find them effective. In general, their role is limited; their duration of effectiveness is, in general, short and does not provide pain control throughout the day. Such medications may also cause complications in children.

Evidence is limited for the use of antimicrobial mouthwashes but suggests that they may reduce the painfulness and duration of ulcers and increase the number of days between ulcerations, without reducing the number of new ulcers.

Milk of magnesia is useful against aphthous ulcers when used topically.

Corticosteroid preparations containing hydrocortisone hemisuccinate or triamcinolone acetonide to control symptoms are effective in treating aphthous ulcers.

The application of silver nitrate will cauterize the sore; a single treatment decreases pain but does not affect healing time though in children it can cause tooth discoloration if the teeth are still developing. The use of tetracycline is controversial, as is treatment with levamisole, colchicine, gamma-globulin, dapsone, estrogen replacement and monoamine oxidase inhibitors.

While commonly used, Magic mouthwash, a combination of a number of ingredients including viscous lidocaine, benzocaine, milk of magnesia, kaolin-pectate, chlorhexidine, or diphenhydramine, has little evidence to support its use in the treatment of aphthous ulcers.

There is the hypothesis that pasteurized goat milk can help with disease symptoms. At the current time, a clinical trial is conducted to check these claims.

Epidemiology

Canker sores are a very common oral lesion. Epidemiological studies show an average prevalence between 15% and 30%. Canker sores tend to afflict women more than men and people less than 45 years old. Canker sores occur most frequently among 16- to 25-year-olds, and they rarely occur in anyone over 55. The frequency of canker sores varies from less than 4 episodes per year (85% of all cases) to more than one episode per month (10% of all cases) including people suffering from continuous RAS.

Chapter 4

Oral Cancer

Oral cancer

ICD-10 C00.-C08.

ICD-9 140-146

DiseasesDB 9288

Oral cancer is a subtype of head and neck cancer, is any cancerous tissue growth located in the oral cavity. It may arise as a primary lesion originating in any of the oral tissues, by metastasis from a distant site of origin, or by extension from a neighboring anatomic structure, such as the nasal cavity or the maxillary sinus. Oral cancers may originate in any of the tissues of the mouth, and may be of varied histologic types: teratoma, adenocarcinoma derived from a major or minor salivary gland, lymphoma from tonsillar or other lymphoid tissue, or melanoma from the pigment producing cells of the oral mucosa. There are several types of oral cancers, but around 90% are squamous cell carcinomas, originating in the tissues that line the mouth and lips. Oral or mouth cancer most commonly involves the tongue. It may also occur on the floor of the mouth, cheek lining, gingiva (gums), lips, or palate (roof of the mouth). Most oral cancers look very similar under the microscope and are called squamous cell carcinoma. These are malignant and tend to spread rapidly.

Signs and symptoms

Skin lesion, lump, or ulcer:

- On the tongue, lip, or other mouth areas
- Usually small
- Most often pale colored, may be dark or discolored
- Early sign may be a white patch (leukoplakia) or a red patch (erythroplakia) on the soft tissues of the mouth
- Usually painless initially
- May develop a burning sensation or pain when the tumor is advanced

Additional symptoms that may be associated with this disease:

- Tongue problems
- Swallowing difficulty
- Mouth sores that do not resolve in 14 days
- Pain and paraesthesia are late symptoms.

Causes

Oncogenes are activated as a result of mutation of the DNA. The exact cause is often unknown. Regardless of the cause, treatment is the same: surgery, radiation with or without chemotherapy. Risk factors that predispose a person to oral cancer have been identified in epidemiological studies. India being member of International Cancer Genome Consortium is leading efforts to map oral cancer's complete genome.

In many Asian cultures chewing betel, paan and Areca is known to be a strong risk factor for developing oral cancer. In India where such practices are common, oral cancer represents up to 40% of all cancers, compared to just 4% in the UK.

Some oral cancers begin as leukoplakia a white patch (lesion), red patches, (erythroplakia) or non healing sores that have existed for more than 14 days. In the US oral cancer accounts for about 8 percent of all malignant growths. Men are affected twice as often as women, particularly men older than 40/60. In Indian subcontinent Oral submucous fibrosis is very common. This condition is characterized by limited opening of mouth and burning sensation on eating of spicy food. This is a progressive lesion in which the opening of the mouth becomes progressively limited, and later on even normal eating becomes difficult. It occurs almost exclusively in India and Indian communities living abroad.

Tobacco

Smoking and other tobacco use are associated with about 75 percent of oral cancer cases, caused by irritation of the mucous membranes of the mouth from smoke and heat of cigarettes, cigars, and pipes. Tobacco contains over 60 known carcinogens, and the combustion of it, and by products from this process, is the primary mode of involvement. Use of chewing tobacco or snuff causes irritation from direct contact with the mucous membranes.

Alcohol

Alcohol use is another high-risk activity associated with oral cancer. There is known to be a very strong synergistic effect on oral cancer risk when a person is both a heavy smoker and drinker. The risk is greatly increased compared to a heavy smoker, or a heavy drinker alone. Recent studies in Australia, Brazil and Germany point to alcohol-containing mouthwashes as also being etiologic agents in the oral cancer risk family. Constant exposure to these alcohol containing rinses, even in the absence of smoking and

drinking, lead to significant increases in the development of oral cancer. A 2008 study suggests that acetaldehyde (a break-down product of alcohol) is implicated in oral cancer.

Human papillomavirus

Infection with human papillomavirus (HPV), particularly type 16 (there are over 120 types), is a known risk factor and independent causative factor for oral cancer. (Gilsion et al. Johns Hopkins) A fast growing segment of those diagnosed does not present with the historic stereotypical demographics. Historically that has been people over 50, blacks over whites 2 to 1, males over females 3 to 1, and 75% of the time people who have used tobacco products or are heavy users of alcohol. This new and rapidly growing sub population between 20 and 50 years old is predominantly non smoking, white, and males slightly outnumber females. Recent research from Johns Hopkins indicates that HPV is the primary risk factor in this new population of oral cancer victims. HPV16 (along with HPV18) is the same virus responsible for the vast majority of all cervical cancers and is the most common sexually transmitted infection in the US. Oral cancer in this group tends to favor the tonsil and tonsillar pillars, base of the tongue, and the oropharynx. Recent data suggest that individuals that come to the disease from this particular etiology have some slight survival advantage.

Diagnosis

An examination of the mouth by the health care provider or dentist shows a visible and/or palpable (can be felt) lesion of the lip, tongue, or other mouth area. As the tumor enlarges, it may become an ulcer and bleed. Speech/talking difficulties, chewing problems, or swallowing difficulties may develop. A feeding tube is often necessary to maintain adequate nutrition. This can sometimes become permanent as eating difficulties can include the inability to swallow even a sip of water.

There are a variety of screening devices that may assist dentists in detecting oral cancer, including the Velscope, Vizilite Plus and the identafi 3000. While a dentist, physician or other health professional may suspect a particular lesion is malignant, there is no way to tell by looking alone - since benign and malignant lesions may look identical to the eye. A non-invasive brush biopsy (BrushTest) can be performed to rule out the presence of dysplasia (pre-cancer) and cancer on areas of the mouth that exhibit an unexplained color variation or lesion. The only definitive method for determining if cancerous or precancerous cells are present is through biopsy and microscopic evaluation of the cells in the removed sample. A tissue biopsy, whether of the tongue or other oral tissues and microscopic examination of the lesion confirm the diagnosis of oral cancer or precancer.

Management

Surgical excision (removal) of the tumor is usually recommended if the tumor is small enough, and if surgery is likely to result in a functionally satisfactory result. Radiation therapy with or without chemo is often used in conjunction with surgery, or as the

definitive radical treatment, especially if the tumour is inoperable. Surgeries for oral cancers include

- Maxillectomy (can be done with or without Orbital exenteration)
- Mandibulectomy (removal of the mandible or lower jaw or part of it)
- Glossectomy (tongue removal, can be total, hemi or partial)
- Radical neck dissection
- Moh's procedure or CCPDMA
- Combinational e.g. glossectomy and laryngectomy done together.
- Feeding tube to sustain nutrition.

Owing to the vital nature of the structures in the head and neck area, surgery for larger cancers is technically demanding. Reconstructive surgery may be required to give an acceptable cosmetic and functional result. Bone grafts and surgical flaps such as the radial forearm flap are used to help rebuild the structures removed during excision of the cancer. An oral prosthesis may also be required. Most oral cancer patients depend on a feeding tube for their hydration and nutrition. Some will also get a port for the chemo to be delivered. Many oral cancer patients are disfigured and suffer from many long term after effects. The after effects often include fatigue, speech problems, trouble maintaining weight, thyroid issues, swallowing difficulties, inability to swallow, memory loss, weakness, dizziness, high frequency hearing loss and sinus damage.

Survival rates for oral cancer depend on the precise site, and the stage of the cancer at diagnosis. Overall, survival is around 50% at five years when all stages of initial diagnosis are considered. Survival rates for stage 1 cancers are 90%, hence the emphasis on early detection to increase survival outcome for patients.

Following treatment, rehabilitation may be necessary to improve movement, chewing, swallowing, and speech. speech and language pathologists may be involved at this stage.

Chemotherapy is useful in oral cancers when used in combination with other treatment modalities such as radiation therapy. It is not used alone as a monotherapy. When cure is unlikely it can also be used to extend life and can be considered palliative but not curative care. Biological agents, such as Cetuximab have recently been shown to be effective in the treatment of squamous cell head and neck cancers, and are likely to have an increasing role in the future management of this condition when used in conjunction with other treatments.

Treatment of oral cancer will usually be by a multidisciplinary team, with treatment professionals from the realms of radiation, surgery, chemotherapy, nutrition, dental professionals, and even psychology all possibly involved with diagnosis, treatment, rehabilitation, and patient care.

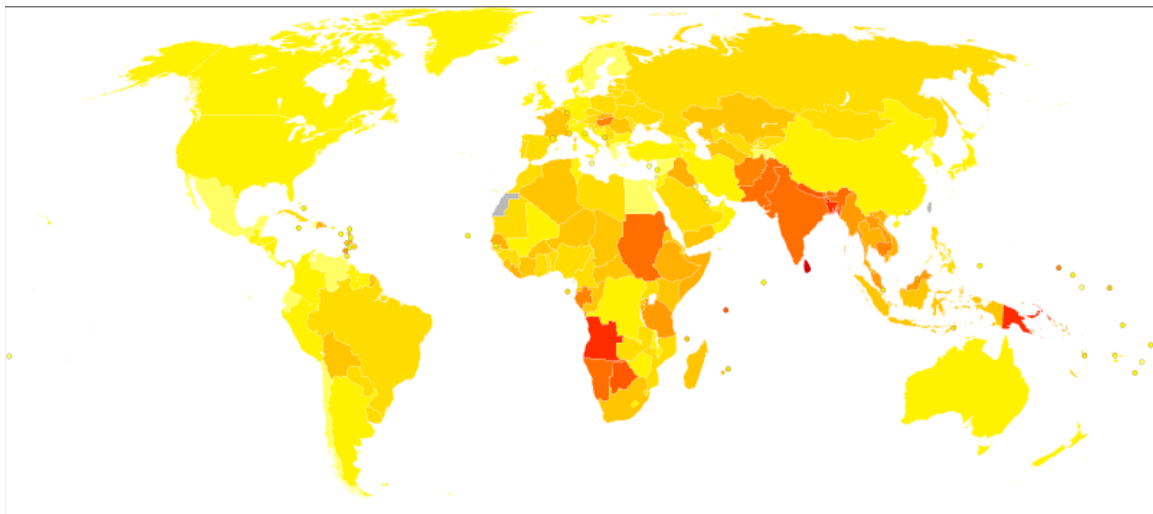
The Oral Cancer Foundation is a website devoted to in depth medical information about all oral cancers including treatment, side effects and even lists of the nation's best cancer treatment centers. The Oral Cancer Foundation has a forum where patients and their

caregivers assist each other. It is monitored by the founder and administrators who ensure accurate up to date information is exchanged. This website has the most comprehensive amount of information devoted to oral cancer.


Prognosis

- Postoperative disfigurement of the face, head and neck
- Complications of radiation therapy, including dry mouth and difficulty swallowing
- Other metastasis (spread) of the cancer
- Significant weight loss

Epidemiology



Age-standardized death from oro-pharyngeal per 100,000 inhabitants in 2004.

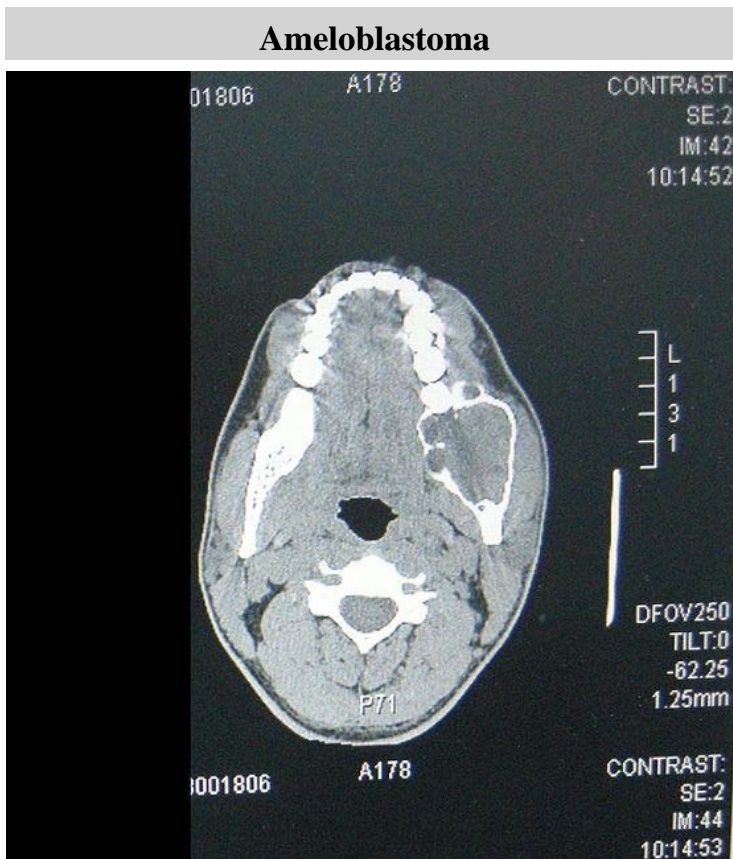


In 2008, in the United States alone, about 34,000 individuals were diagnosed with oral cancer. 66% of the time these will be found as late stage three and four disease. Low public awareness of the disease is a significant factor, but these cancers could be found at

early highly survivable stages through a simple, painless, 5 minute examination by a trained medical or dental professional.

Chapter 5

Ameloblastoma



A CT scan of a patient suffering from an ameloblastoma

ICD-10	D16.5
ICD-9	213.1
ICD-O:	9310/0
DiseasesDB	31676
MeSH	D000564

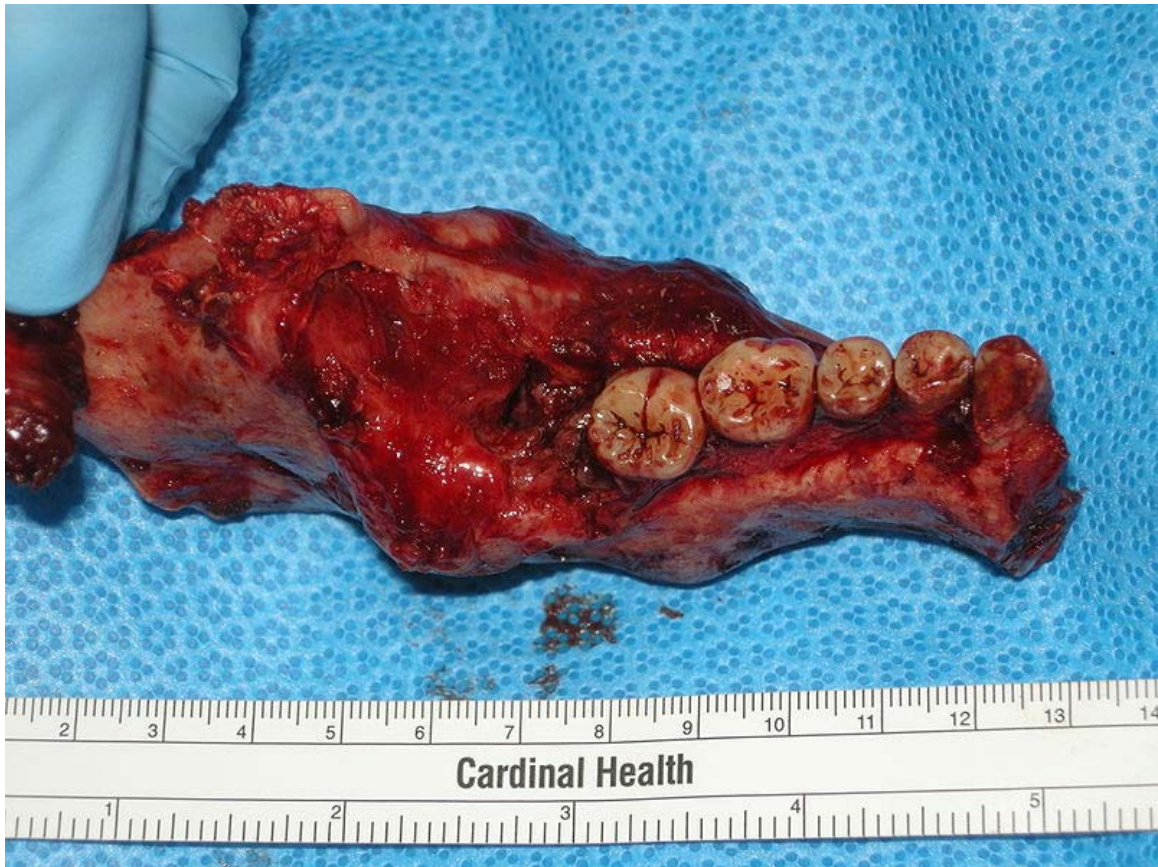Ameloblastoma (from the early English word *amel*, meaning enamel + the Greek word *blastos*, meaning germ) is a rare, benign tumor of odontogenic epithelium (ameloblasts, or outside portion, of the teeth during development) much more commonly appearing in the mandible than the maxilla. It was recognized in 1827 by Cusack. This type of odontogenic neoplasm was designated as an *adamantinoma* in 1885 by the French physician Louis-Charles Malassez. It was finally renamed to the modern name *ameloblastoma* in 1930 by Ivey and Churchill.

While these tumors are rarely malignant or metastatic (that is, they rarely spread to other parts of the body), and progress slowly, the resulting lesions can cause severe abnormalities of the face and jaw. Additionally, because abnormal cell growth easily infiltrates and destroys surrounding bony tissues, wide surgical excision is required to treat this disorder.

Subtypes

There are three main clinical subtypes of ameloblastoma: unicystic, multicystic, peripheral. The peripheral subtype composes 2% of all ameloblastomas. Of all ameloblastomas in younger patients, unicystic ameloblastomas represent 6% of the cases. A fourth subtype, malignant, has been considered by some oncologic specialists, however, this form of the tumor is rare and may be simply a manifestation of one of the three main subtypes. Ameloblastoma also occurs in long bones, and another variant is Craniopharyngioma (Rathke's pouch tumour, Pituitary Ameloblastoma.)

Clinical features



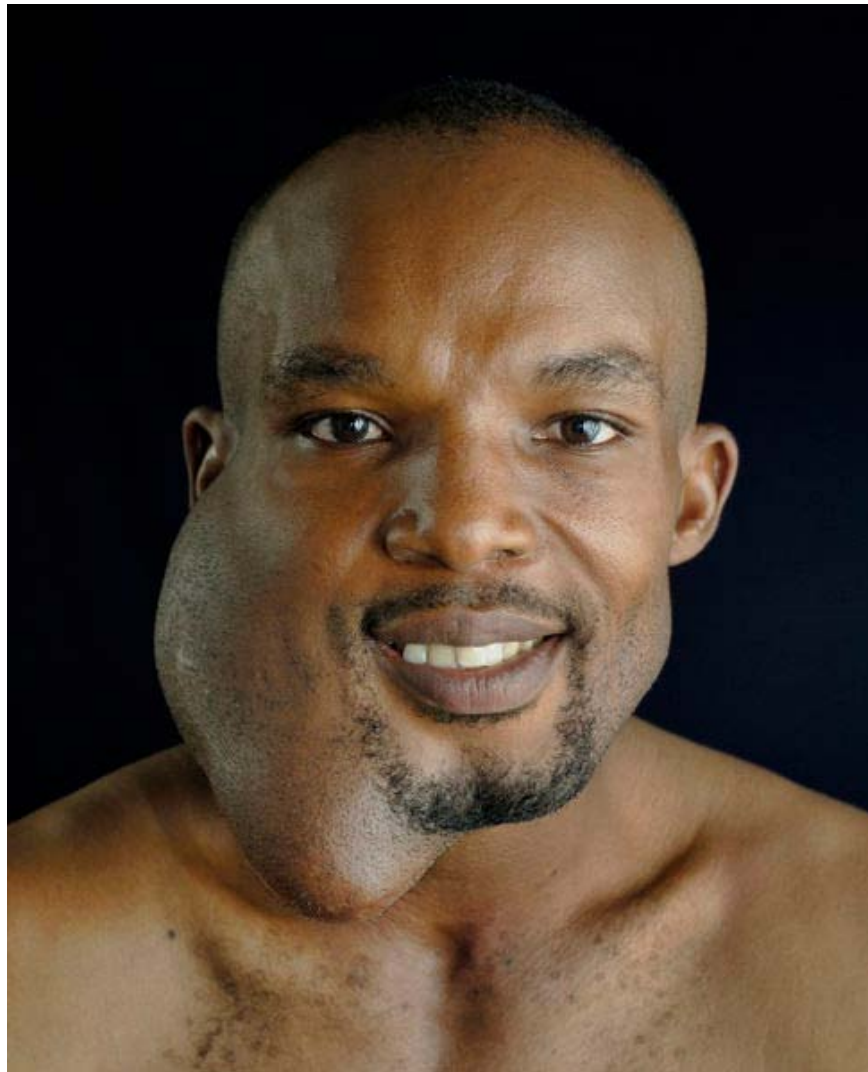
The resected left half of a mandible containing an ameloblastoma, initiated at the third molar

Ameloblastomas are often associated with the presence of unerupted teeth. Symptoms include painless swelling, facial deformity if severe enough, pain if the swelling impinges on other structures, loose teeth, ulcers, and periodontal (gum) disease. Lesions will occur in the mandible and maxilla, although 75% occur in the ascending ramus area and will result in extensive and grotesque deformities of the mandible and maxilla. In the maxilla it can extend into the maxillary sinus and floor of the nose. The lesion has a tendency to expand the bony cortices because slow growth rate of the lesion allows time for periosteum to develop thin shell of bone ahead of the expanding lesion. This shell of bone cracks when palpated and this phenomenon is referred to as "Egg Shell Cracking" or crepitus, an important diagnostic feature. Ameloblastoma is tentatively diagnosed through radiographic examination and must be confirmed by histological examination (e.g., biopsy). Radiographically, it appears as a lucency in the bone of varying size and features—sometimes it is a single, well-demarcated lesion whereas it often demonstrates as a multiloculated "soap bubble" appearance. Resorption of roots of involved teeth can be seen in some cases, but is not unique to ameloblastoma. The disease is most often found in the posterior body and angle of the mandible, but can occur anywhere in either the maxilla or mandible.

Ameloblastoma is often associated with bony-impacted wisdom teeth—one of the many reasons dentists recommend having them extracted.

Histopathology

Histopathology will show cells that have the tendency to move the nucleus away from the basement membrane. This process is referred to as "Reverse Polarization". The follicular type will have outer arrangement of columnar or palisaded ameloblast like cells and inner zone of triangular shaped cells resembling stellate reticulum in bell stage. The central cells sometimes degenerate to form central microcysts. The plexiform type has epithelium that proliferates in a "Fish Net Pattern". The plexiform ameloblastoma shows epithelium proliferating in a 'cord like fashion', hence the name 'plexiform'. There are layers of cells in between the proliferating epithelium with a well-formed desmosomal junctions, simulating spindle cell layers.



Ameloblastoma

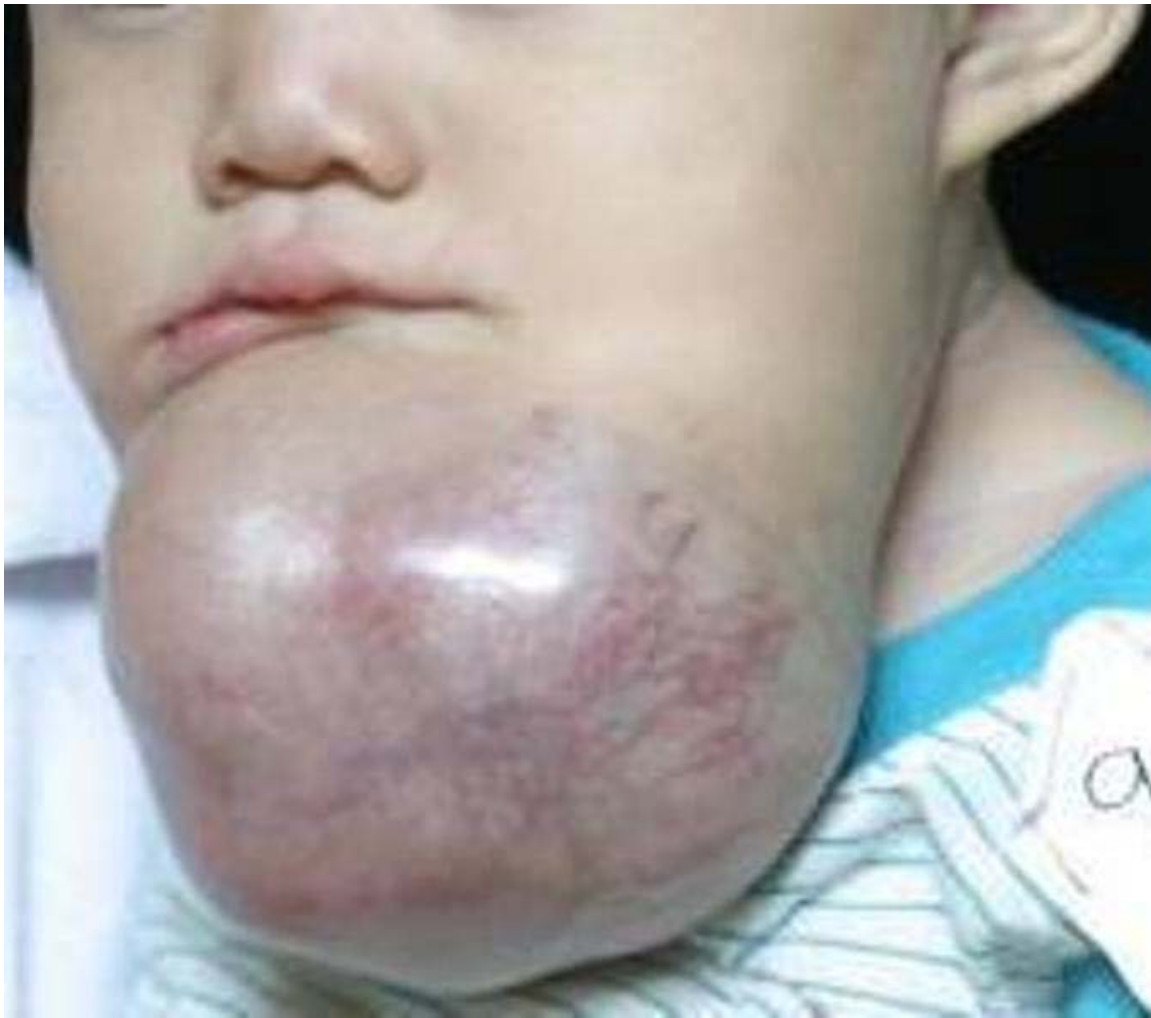Variants

The six different histopathological variants of ameloblastoma are desmoplastic, granular cell, basal cell, plexiform, follicular, and acanthomatous.

The acanthomatous variant is extremely rare.

One-third of ameloblastomas are plexiform, one-third are follicular. Other variants such as acanthomatous occur in older patients. In one center, desmoplastic ameloblastomas represented about 9% of all ameloblastomas encountered.

Treatment



Tracheal intubation is anticipated to be difficult in this child with a massive ameloblastoma

While chemotherapy, radiation therapy, curettage and liquid nitrogen have been effective in some cases of ameloblastoma, surgical resection or enucleation remains the most

definitive treatment for this condition. In a detailed study of 345 patients, chemotherapy and radiation therapy seemed to be contraindicated for the treatment of ameloblastomas. Thus, surgery is the most common treatment of this tumor. Because of the invasive nature of the growth, excision of normal tissue near the tumor margin is often required. Some have likened the disease to basal cell carcinoma (a skin cancer) in its tendency to spread to adjacent bony and sometimes soft tissues without metastasizing. While not a cancer that actually invades adjacent tissues, ameloblastoma is suspected to spread to adjacent areas of the jaw bone via marrow space. Thus, wide surgical margins that are clear of disease are required for a good prognosis. This is very much like surgical treatment of cancer. Often, treatment requires excision of entire portions of the jaw.

Radiation is ineffective in many cases of ameloblastoma. There have also been reports of sarcoma being induced as the result of using radiation to treat ameloblastoma. Chemotherapy is also often ineffective. However, there is some controversy regarding this and some indication that some ameloblastomas might be more responsive to radiation than previously thought.

While the Mayo Clinic recommends surgery for almost all ameloblastomas, there are situations in which a Mayo Clinic physician might recommend radiation therapy. These include malignancy, inability to completely remove the ameloblastoma, recurrence, unacceptable loss of function, and unacceptable cosmetic damage. In the case of radiotherapy, oncologists at the Mayo Clinic would use intensity-modulated radiotherapy.

Molecular biology

There is evidence that suppression of matrix metalloproteinase-2 may inhibit the local invasiveness of ameloblastoma, however, this was only demonstrated *in vitro*. There is also some research suggesting that $\alpha_5\beta_1$ integrin may participate in the local invasiveness of ameloblastomas.

Recurrence

Recurrence is common, although the recurrence rates for block resection followed by bone graft are lower than those of enucleation and curettage. Follicular variants appear to recur more than plexiform variants. Unicystic tumors recur less frequently than "non-unicystic" tumors. Persistent follow-up examination is essential for managing ameloblastoma. Follow up should occur at regular intervals for at least 10 years. Follow up is important, because 50% of all recurrences occur within 5 years postoperatively. Recurrence within a bone graft (following resection of the original tumor) does occur, but is less common. Seeding to the bone graft is suspected as a cause of recurrence. The recurrences in these cases seem to stem from the soft tissues, especially the adjacent periosteum. Recurrence has been reported to occur as many as 36 years after treatment.

To reduce the likelihood of recurrence within grafted bone, meticulous surgery with attention to the adjacent soft tissues is required.

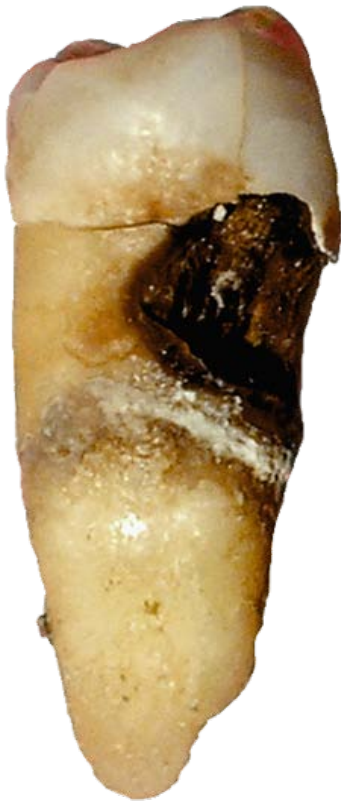Epidemiology

The annual incidence rates per million for ameloblastomas are 1.96, 1.20, 0.18 and 0.44 for black males, black females, white males and white females respectively. Ameloblastomas account for about one percent of all oral tumors and about 18% of odontogenic tumors. Men and women tend to be equally affected, although women tend to be 4 years younger than men when tumors first occur and tumors appear to be larger in females.

Chapter 6

Dental Caries

Dental caries



Destruction of a tooth by cervical decay from dental caries. This type of decay is also known as root decay.

ICD-10 K02.

ICD-9 521.0

DiseasesDB 29357

MedlinePlus 001055

Dental caries, also known as **tooth decay** or a **cavity**, is a disease where bacterial processes damage hard tooth structure (enamel, dentin, and cementum). These tissues progressively break down, producing dental caries (cavities, holes in the teeth). Two groups of bacteria are responsible for initiating caries: *Streptococcus mutans* and *Lactobacillus*. If left untreated, the disease can lead to pain, tooth loss, infection, and, in severe cases, death. Today, caries remains one of the most common diseases throughout the world. Cariology is the study of dental caries.

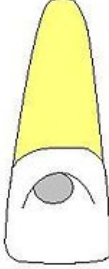
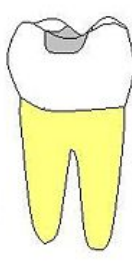
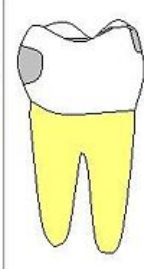
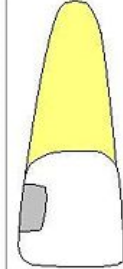
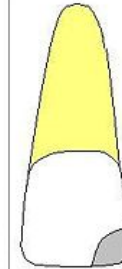
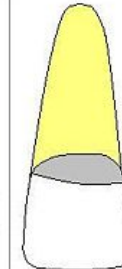
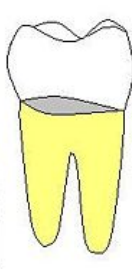
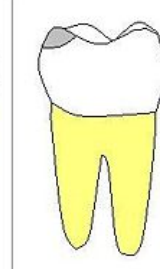
The presentation of caries is highly variable; however, the risk factors and stages of development are similar. Initially, it may appear as a small chalky area that may eventually develop into a large cavitation. Sometimes caries may be directly visible, however other methods of detection such as radiographs are used for less visible areas of teeth and to judge the extent of destruction.

Tooth decay is caused by specific types of acid-producing bacteria that cause damage in the presence of fermentable carbohydrates such as sucrose, fructose, and glucose. The mineral content of teeth is sensitive to increases in acidity from the production of lactic acid. Specifically, a tooth (which is primarily mineral in content) is in a constant state of back-and-forth demineralization and remineralization between the tooth and surrounding saliva. When the pH at the surface of the tooth drops below 5.5, demineralization proceeds faster than remineralization (meaning that there is a net loss of mineral structure on the tooth's surface). This results in the ensuing decay. Depending on the extent of tooth destruction, various treatments can be used to restore teeth to proper form, function, and aesthetics, but there is no known method to regenerate large amounts of tooth structure, though stem cell related research suggests one possibility. Instead, dental health organizations advocate preventive and prophylactic measures, such as regular oral hygiene and dietary modifications, to avoid dental caries.

Classification

Caries can be classified by location, etiology, rate of progression, and affected hard tissues. These forms of classification can be used to characterize a particular case of tooth decay in order to more accurately represent the condition to others and also indicate the severity of tooth destruction.

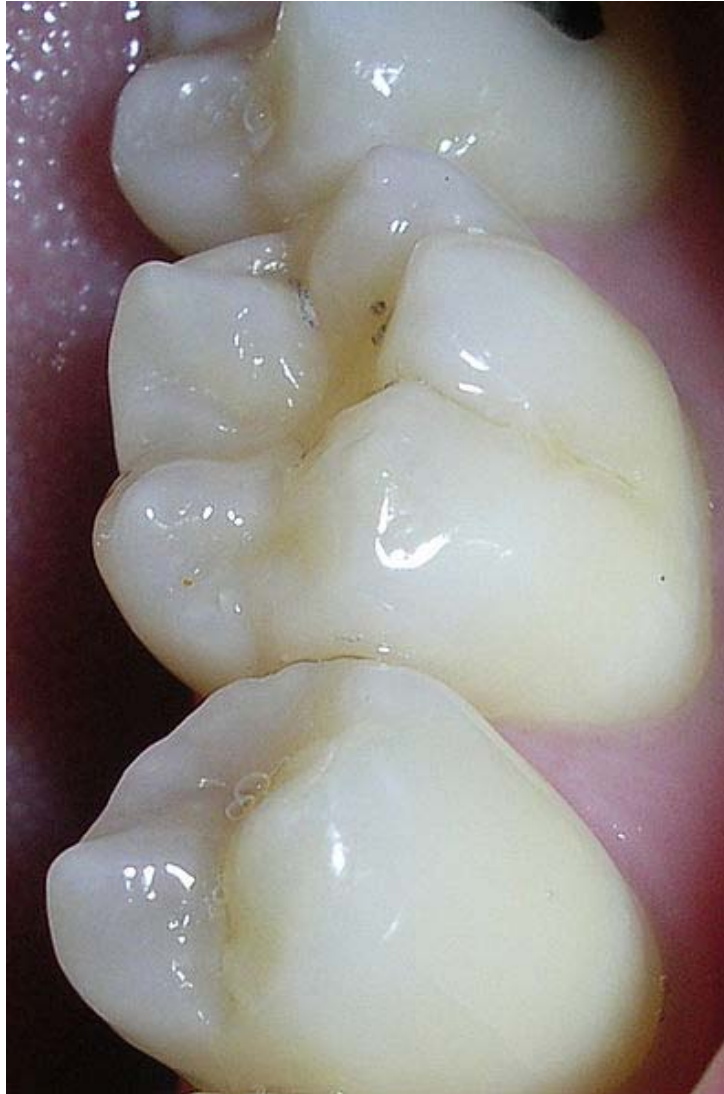Jessica R. Martin

G.V. Black							
L	B/L	B/L	F	F	F/L	B/L	B/L
							
Class I		Class II		Class III	Class IV	Class V	
						Class VI	

G.V. Black Classification of Restorations

Location

Generally, there are two types of caries when separated by location: caries found on smooth surfaces and caries found in pits and fissures. The location, development, and progression of smooth-surface caries differ from those of pit and fissure caries. G.V. Black created a classification system that is widely used and based on the location of the caries on the tooth. The original classification distinguished caries into five groups, indicated by the word "Class", and a Roman numeral. Pit and fissure caries is indicated as Class I; smooth surface caries is further divided into Class II, Class III, Class IV, and Class V. A Class VI was added onto Black's Classification of Caries Lesions and also represents a smooth-surface carious lesion.



The pits and fissures of teeth provide a location for caries formation

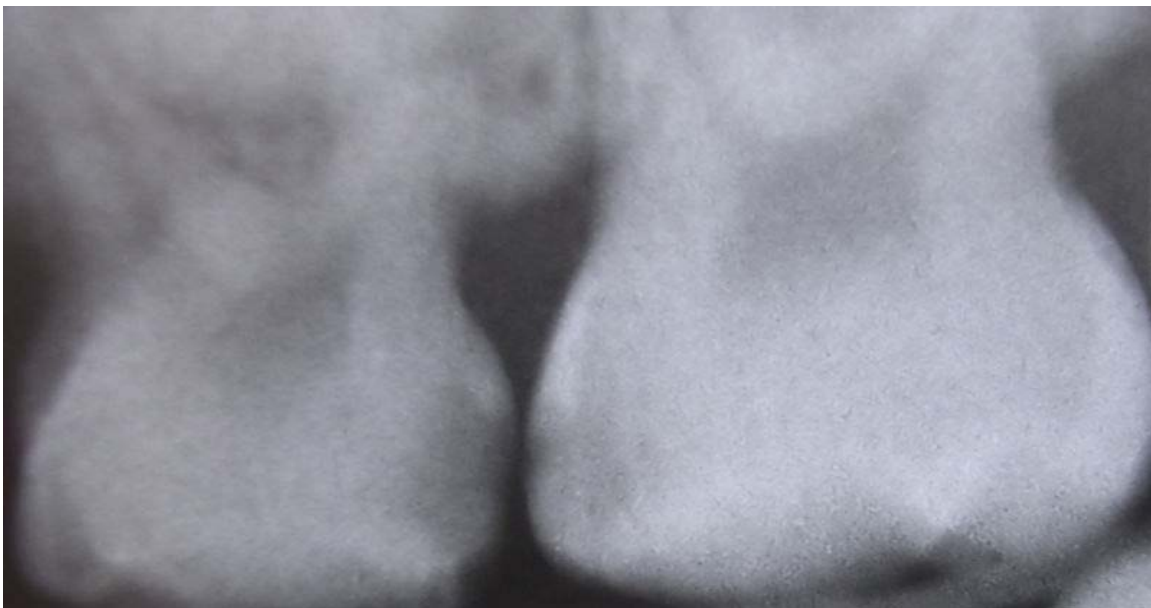Pit and fissure caries (class I dental caries)

Pits and fissures are anatomic landmarks on a tooth where the enamel folds inward. Fissures are formed during the development of grooves but the enamel in the area is not fully fused. As a result, a deep linear depression forms in the enamel's surface structure, which forms a location for dental caries to develop and flourish. Fissures are mostly located on the occlusal (chewing) surfaces of posterior (rear) teeth and palatal surfaces of maxillary anterior (front) teeth. Pits are small, pinpoint depressions that are most commonly found at the ends or cross-sections of grooves. In particular, buccal pits are found on the facial surfaces of molars. For all types of pits and fissures, the deep infolding of enamel makes oral hygiene along these surfaces difficult, allowing dental caries to develop more commonly in these areas.

The occlusal surfaces of teeth represent 12.5% of all tooth surfaces but are the location of over 50% of all dental caries. Among children, pit and fissure caries represent 90% of all dental caries. Pit and fissure caries can sometimes be difficult to detect. As the decay progresses, caries in enamel nearest the surface of the tooth spreads gradually deeper. Once the caries reaches the dentin at the dentino-enamel junction (DEJ), the decay quickly spreads laterally. Within the dentin, the decay follows a triangle pattern that points to the tooth's pulp. This pattern of decay is typically described as two triangles (one triangle in enamel, and another in dentin) with their bases conjoined to each other at the DEJ. This base-to-base pattern is typical of pit and fissure caries, unlike smooth-surface caries (where base and apex of the two triangles join).

Smooth-surface caries

There are three types of smooth-surface caries. Proximal caries, also called interproximal caries, form on the smooth surfaces between adjacent teeth. Root caries form on the root surfaces of teeth. The third type of smooth-surface caries occur on any other smooth tooth surface.



In this radiograph, the dark spots in the adjacent teeth show proximal caries

Proximal caries are the most difficult type to detect. Frequently, this type of caries cannot be detected visually or manually with a dental explorer. Proximal caries form cervically (toward the roots of a tooth) just under the contact between two teeth. As a result, radiographs are needed for early discovery of proximal caries. Under Black's classification system, proximal caries on posterior teeth (premolars and molars) are designated as Class II caries. Proximal caries on anterior teeth (incisors and canines) are indicated as Class III if the incisal edge (chewing surface) is not included and Class IV if the incisal edge is included.

Root caries, which are sometimes described as a category of smooth-surfaces caries, are the third most common type of caries and usually occur when the root surfaces have been exposed due to gingival recession. When the gingiva is healthy, root caries is unlikely to develop because the root surfaces are not as accessible to bacterial plaque. The root surface is more vulnerable to the demineralization process than enamel because cementum begins to demineralize at 6.7 pH, which is higher than enamel's critical pH. Regardless, it is easier to arrest the progression of root caries than enamel caries because roots have a greater reuptake of fluoride than enamel. Root caries are most likely to be found on facial surfaces, then interproximal surfaces, then lingual surfaces. Mandibular molars are the most common location to find root caries, followed by mandibular premolars, maxillary anteriors, maxillary posteriors, and mandibular anteriors.

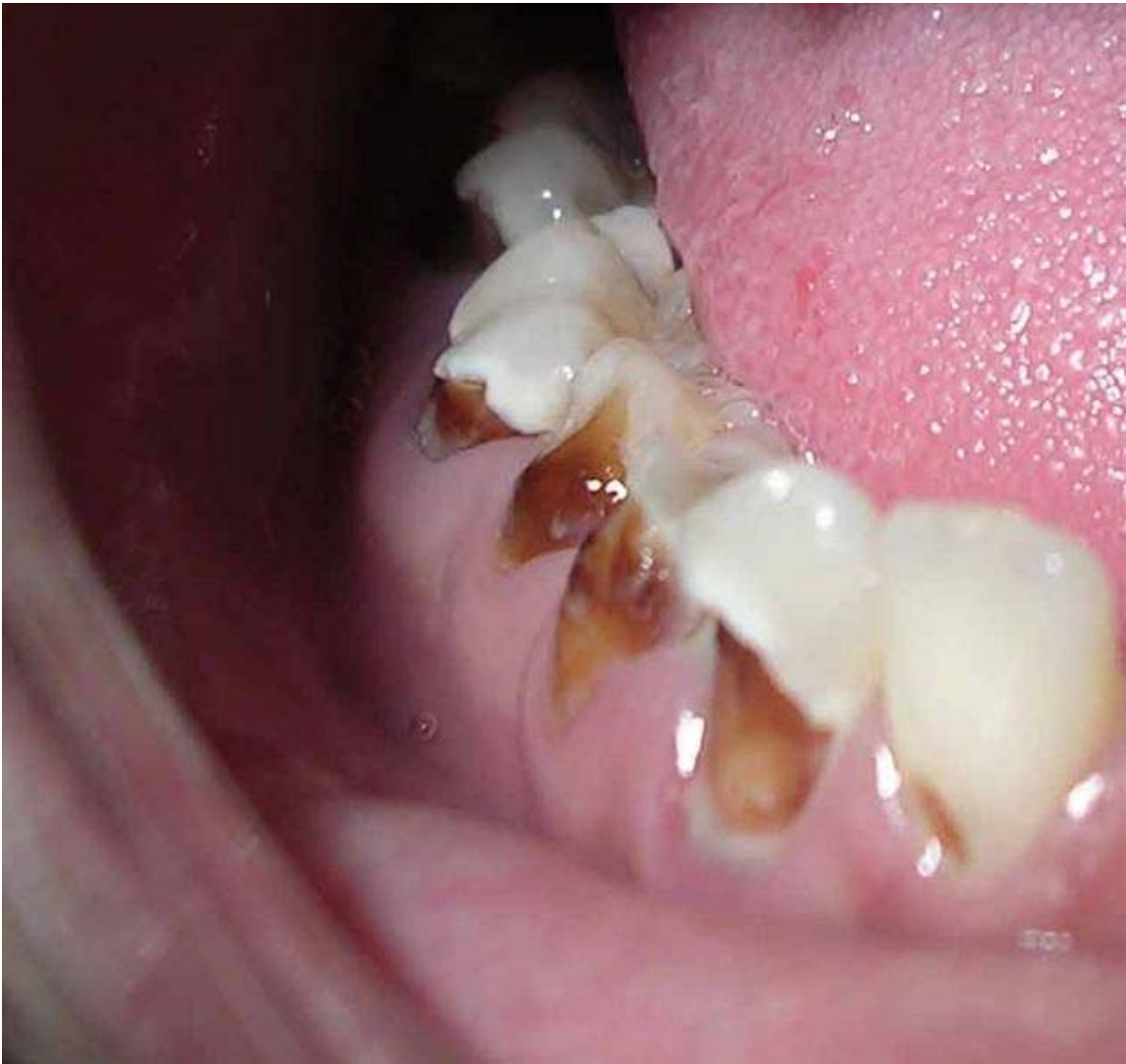Lesions on other smooth surfaces of teeth are also possible. Since these occur in all smooth surface areas of enamel except for interproximal areas, these types of caries are easily detected and are associated with high levels of plaque and diets promoting caries formation. Under Black's classification system, caries near the gingiva on the facial or lingual surfaces is designated Class V. Class VI is reserved for caries confined to cusp tips on posterior teeth or incisal edges of anterior teeth.

Other general descriptions

Besides the two previously mentioned categories, carious lesions can be described further by their location on a particular surface of a tooth. Caries on a tooth's surface that are nearest the cheeks or lips are called "facial caries", and caries on surfaces facing the tongue are known as "lingual caries". Facial caries can be subdivided into buccal (when found on the surfaces of posterior teeth nearest the cheeks) and labial (when found on the surfaces of anterior teeth nearest the lips). Lingual caries can also be described as palatal when found on the lingual surfaces of maxillary teeth because they are located beside the hard palate.

Caries near a tooth's cervix—the location where the crown of a tooth and its roots meet—are referred to as cervical caries. Occlusal caries are found on the chewing surfaces of posterior teeth. Incisal caries are caries found on the chewing surfaces of anterior teeth. Caries can also be described as "mesial" or "distal." Mesial signifies a location on a tooth closer to the median line of the face, which is located on a vertical axis between the eyes, down the nose, and between the contact of the central incisors. Locations on a tooth further away from the median line are described as distal.

Etiology



Rampant caries

In some instances, caries are described in other ways that might indicate the cause. "Baby bottle caries", "early childhood caries", or "baby bottle tooth decay" is a pattern of decay found in young children with their deciduous (baby) teeth. The teeth most likely affected are the maxillary anterior teeth, but all teeth can be affected. The name for this type of caries comes from the fact that the decay usually is a result of allowing children to fall asleep with sweetened liquids in their bottles or feeding children sweetened liquids multiple times during the day. Another pattern of decay is "rampant caries", which signifies advanced or severe decay on multiple surfaces of many teeth. Rampant caries may be seen in individuals with xerostomia, poor oral hygiene, stimulant use (due to drug-induced dry mouth), and/or large sugar intake. If rampant caries is a result of previous radiation to the head and neck, it may be described as radiation-induced caries. Problems can also be caused by the self destruction of roots and whole tooth resorption when new teeth erupt or later from unknown causes. Dr. Miller stated in 1887 that

"Dental decay is chemico-parasitic process consisting of two stages, the decalcification of enamel, which results in its total destruction and the decalcification of dentin as a preliminary stage followed by dissolution of the softened residue." In his hypothesis, Dr. Miller assigned essential roles to three factors:

1. Carbohydrate substrate.
2. Acid which caused dissolution of tooth minerals.
3. Oral micro organisms which produce acid and also cause proteolysis.

Rate of progression

Temporal descriptions can be applied to caries to indicate the progression rate and previous history. "Acute" signifies a quickly developing condition, whereas "chronic" describes a condition which has taken an extended time to develop where thousands of meals and snacks, many causing some acid demineralisation that is not remineralized and eventually results in cavities. Fluoride treatment can help recalcification of tooth enamel.

Recurrent caries, also described as secondary, are caries that appears at a location with a previous history of caries. This is frequently found on the margins of fillings and other dental restorations. On the other hand, incipient caries describes decay at a location that has not experienced previous decay. Arrested caries describes a lesion on a tooth which was previously demineralized but was remineralized before causing a cavitation. Using fluoride treatments can help with recalcification.

Affected hard tissue

Depending on which hard tissues are affected, it is possible to describe caries as involving enamel, dentin, or cementum. Early in its development, caries may affect only enamel. Once the extent of decay reaches the deeper layer of dentin, "dentin caries" is used. Since cementum is the hard tissue that covers the roots of teeth, it is not often affected by decay unless the roots of teeth are exposed to the mouth. Although the term "cementum caries" may be used to describe the decay on roots of teeth, very rarely does caries affect the cementum alone. Roots have a very thin layer of cementum over a large layer of dentin, and thus most caries affecting cementum also affects dentin.

Signs and symptoms



The tip of a dental explorer, which is used for caries diagnosis

A person experiencing caries may not be aware of the disease. The earliest sign of a new carious lesion is the appearance of a chalky white spot on the surface of the tooth, indicating an area of demineralization of enamel. This is referred to as incipient decay. As the lesion continues to demineralize, it can turn brown but will eventually turn into a cavitation ("cavity"). Before the cavity forms, the process is reversible, but once a cavity forms, the lost tooth structure cannot be regenerated. A lesion which appears brown and shiny suggests dental caries were once present but the demineralization process has stopped, leaving a stain. A brown spot which is dull in appearance is probably a sign of active caries.

As the enamel and dentin are destroyed, the cavity becomes more noticeable. The affected areas of the tooth change color and become soft to the touch. Once the decay passes through enamel, the dentinal tubules, which have passages to the nerve of the tooth, become exposed and causes pain in the tooth. The pain may worsen with exposure to heat, cold, or sweet foods and drinks. Dental caries can also cause bad breath and foul tastes. In highly progressed cases, infection can spread from the tooth to the surrounding soft tissues. Complications such as cavernous sinus thrombosis and Ludwig's angina can be life-threatening.

Causes

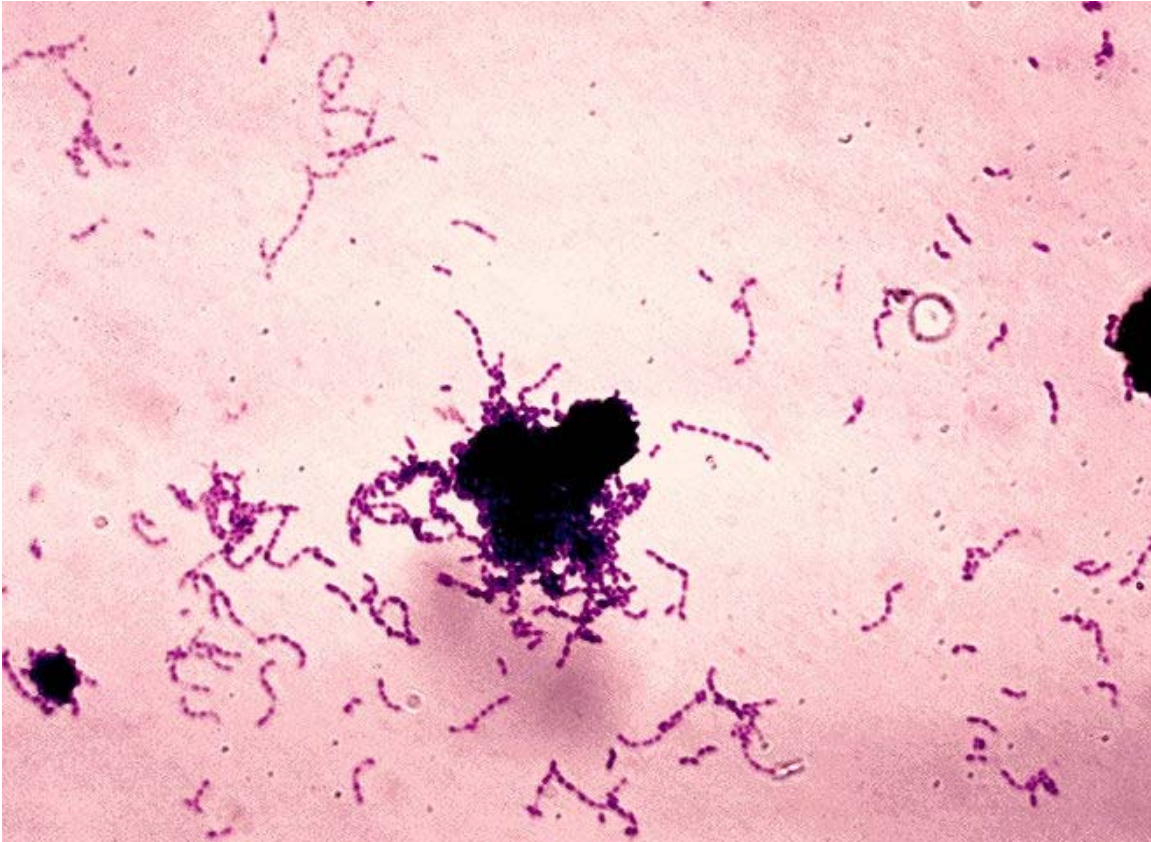
There are four main criteria required for caries formation: a tooth surface (enamel or dentin); caries-causing bacteria; fermentable carbohydrates (such as sucrose); and time. The caries process does not have an inevitable outcome, and different individuals will be susceptible to different degrees depending on the shape of their teeth, oral hygiene habits, and the buffering capacity of their saliva. Dental caries can occur on any surface of a tooth which is exposed to the oral cavity, but not the structures which are retained within the bone.

Teeth

There are certain diseases and disorders affecting teeth which may leave an individual at a greater risk for caries. Amelogenesis imperfecta, which occurs between 1 in 718 and 1 in 14,000 individuals, is a disease in which the enamel does not fully form or forms in insufficient amounts and can fall off a tooth. In both cases, teeth may be left more vulnerable to decay because the enamel is not able to protect the tooth.

In most people, disorders or diseases affecting teeth are not the primary cause of dental caries. Ninety-six percent of tooth enamel is composed of minerals. These minerals, especially hydroxyapatite, will become soluble when exposed to acidic environments. Enamel begins to demineralize at a pH of 5.5. Dentin and cementum are more susceptible to caries than enamel because they have lower mineral content. Thus, when root surfaces of teeth are exposed from gingival recession or periodontal disease, caries can develop more readily. Even in a healthy oral environment, however, the tooth is susceptible to dental caries.

The anatomy of teeth may affect the likelihood of caries formation. Where the deep grooves of teeth are more numerous and exaggerated, pit and fissure caries are more likely to develop. Also, caries are more likely to develop when food is trapped between teeth.



A gram stain image of *Streptococcus mutans*

Bacteria

The mouth contains a wide variety of oral bacteria, but only a few specific species of bacteria are believed to cause dental caries: *Streptococcus mutans* and *Lactobacilli* among them. *Lactobacillus acidophilus*, *Actinomyces viscosus*, *Nocardia spp.*, and *Streptococcus mutans* are most closely associated with caries, particularly root caries. Bacteria collect around the teeth and gums in a sticky, creamy-coloured mass called plaque, which serves as a biofilm. Some sites collect plaque more commonly than others. The grooves on the biting surfaces of molar and premolar teeth provide microscopic retention, as does the point of contact between teeth. Plaque may also collect along the gingiva.

Fermentable carbohydrates

Bacteria in a person's mouth convert glucose, fructose, and most commonly sucrose (table sugar) into acids such as lactic acid through a glycolytic process called fermentation. If left in contact with the tooth, these acids may cause demineralization, which is the dissolution of its mineral content. The process is dynamic, however, as remineralization can also occur if the acid is neutralized by saliva or mouthwash. Fluoride toothpaste or dental varnish may aid remineralization. If demineralization continues over time, enough mineral content may be lost so that the soft organic material

left behind disintegrates, forming a cavity or hole. The impact such sugars have on the progress of dental caries is called cariogenicity. Sucrose, although a bound glucose and fructose unit, is in fact more cariogenic than a mixture of equal parts of glucose and fructose. This is due to the bacteria utilising the energy in the saccharide bond between the glucose and fructose subunits. *S.mutans* adheres to the biofilm on the tooth by converting sucrose into an extremely adhesive substance called dextran polysaccharide by the enzyme dextransucranase.

Time

The frequency of which teeth are exposed to cariogenic (acidic) environments affects the likelihood of caries development. After meals or snacks, the bacteria in the mouth metabolize sugar, resulting in an acidic by-product which decreases pH. As time progresses, the pH returns to normal due to the buffering capacity of saliva and the dissolved mineral content of tooth surfaces. During every exposure to the acidic environment, portions of the inorganic mineral content at the surface of teeth dissolves and can remain dissolved for two hours. Since teeth are vulnerable during these acidic periods, the development of dental caries relies heavily on the frequency of acid exposure.

The carious process can begin within days of a tooth erupting into the mouth if the diet is sufficiently rich in suitable carbohydrates. Evidence suggests that the introduction of fluoride treatments have slowed the process. Proximal caries take an average of four years to pass through enamel in permanent teeth. Because the cementum enveloping the root surface is not nearly as durable as the enamel encasing the crown, root caries tends to progress much more rapidly than decay on other surfaces. The progression and loss of mineralization on the root surface is 2.5 times faster than caries in enamel. In very severe cases where oral hygiene is very poor and where the diet is very rich in fermentable carbohydrates, caries may cause cavities within months of tooth eruption. This can occur, for example, when children continuously drink sugary drinks from baby bottles.

Other risk factors

Reduced saliva is associated with increased caries since the buffering capability of saliva is not present to counterbalance the acidic environment created by certain foods. As result, medical conditions that reduce the amount of saliva produced by salivary glands, particularly the submandibular gland and parotid gland, are likely to lead to widespread tooth decay. Examples include Sjögren's syndrome, diabetes mellitus, diabetes insipidus, and sarcoidosis. Medications, such as antihistamines and antidepressants, can also impair salivary flow. Stimulants, most notoriously methylamphetamine, also occlude the flow of saliva to an extreme degree. Abusers of stimulants tend to have poor oral hygiene. Tetrahydrocannabinol, the active chemical substance in cannabis, also causes a nearly complete occlusion of salivation, known colloquially as "cotton mouth". Moreover, sixty-three percent of the most commonly prescribed medications in the United States list dry mouth as a known side effect. Radiation therapy of the head and neck may also damage the cells in salivary glands, increasing the likelihood of caries formation.

The use of tobacco may also increase the risk for caries formation. Some brands of smokeless tobacco contain high sugar content, increasing susceptibility to caries. Tobacco use is a significant risk factor for periodontal disease, which can cause the gingiva to recede. As the gingiva loses attachment to the teeth, the root surface becomes more visible in the mouth. If this occurs, root caries is a concern since the cementum covering the roots of teeth is more easily demineralized by acids than enamel. Currently, there is not enough evidence to support a causal relationship between smoking and coronal caries, but evidence does suggest a relationship between smoking and root-surface caries.

Intrauterine and neonatal lead exposure promote tooth decay. Besides lead, all atoms with electrical charge and ionic radius similar to bivalent calcium, such as cadmium, mimic the calcium ion and therefore exposure may promote tooth decay.

Salivary and dietary iodine seems to play an important role in pathogenesis of dental caries and in salivary glands physiology. Saliva is rich in peroxidase enzymes and has high secretion of iodides. Iodine is able to penetrate directly through intact enamel in dentine, pulp and periodontal tissues and according to some researchers it is able to prevent some dental pathologies directly with antibacterial action, and also indirectly with an antioxidant mechanism.

- Venturi S, Venturi M. (2009). Iodine in evolution of salivary glands and in oral health. *Nutr Health*. 2009;20(2):119-34.

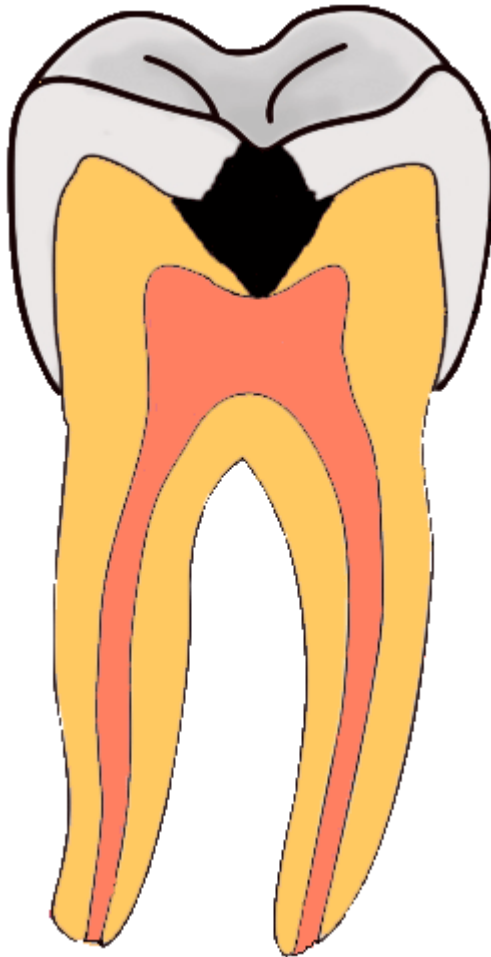
- Banerjee, R.K. and Datta, A.G. (1986). Salivary peroxidases. *Mol Cell Biochem*, 70, 21-9.

- Hardgrove, T.A.: ADA Booklet (1939). "Dental Caries" published in 1939 by the American Dental Association (ADA). (Lynch, Kettering, Gies, eds.).

- Bartelstone, H. J. (1951). Radioiodine penetration through intact enamel with uptake by bloodstream and thyroid gland. *J Dent Res.*, 5, 728–33.

- Bartelstone, H.J., Mandel, I.D., Oshry, E. and Seidlin, S.M. (1947). Use of Radioactive Iodine as a Tracer in the Study of the Physiology of Teeth. *Science*, 106, 132.

Pathophysiology



The progression of pit and fissure caries resembles two triangles with their bases meeting along the junction of enamel and dentin.

Enamel

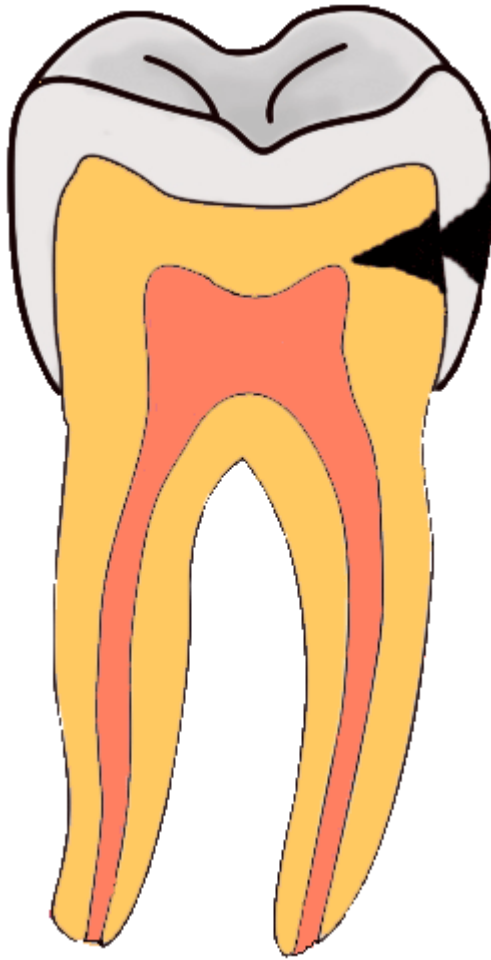
Enamel is a highly mineralized acellular tissue, and caries act upon it through a chemical process brought on by the acidic environment produced by bacteria. As the bacteria consume the sugar and use it for their own energy, they produce lactic acid. The effects of this process include the demineralization of crystals in the enamel, caused by acids, over time until the bacteria physically penetrate the dentin. Enamel rods, which are the basic unit of the enamel structure, run perpendicularly from the surface of the tooth to the dentin. Since demineralization of enamel by caries generally follows the direction of the enamel rods, the different triangular patterns between pit and fissure and smooth-surface caries develop in the enamel because the orientation of enamel rods are different in the two areas of the tooth.

As the enamel loses minerals, and dental caries progresses, the enamel develops several distinct zones, visible under a light microscope. From the deepest layer of the enamel to the enamel surface, the identified areas are the: translucent zone, dark zones, body of the lesion, and surface zone. The translucent zone is the first visible sign of caries and coincides with a one to two percent loss of minerals. A slight remineralization of enamel occurs in the dark zone, which serves as an example of how the development of dental caries is an active process with alternating changes. The area of greatest demineralization and destruction is in the body of the lesion itself. The surface zone remains relatively mineralized and is present until the loss of tooth structure results in a cavitation.

Dentin

Unlike enamel, the dentin reacts to the progression of dental caries. After tooth formation, the ameloblasts, which produce enamel, are destroyed once enamel formation is complete and thus cannot later regenerate enamel after its destruction. On the other hand, dentin is produced continuously throughout life by odontoblasts, which reside at the border between the pulp and dentin. Since odontoblasts are present, a stimulus, such as caries, can trigger a biologic response. These defense mechanisms include the formation of sclerotic and tertiary dentin.

In dentin from the deepest layer to the enamel, the distinct areas affected by caries are the translucent zone, the zone of destruction, and the zone of bacterial penetration. The translucent zone represents the advancing front of the carious process and is where the initial demineralization begins. The zones of bacterial penetration and destruction are the locations of invading bacteria and ultimately the decomposition of dentin.



The faster spread of caries through dentin creates this triangular appearance in smooth surface caries.

Sclerotic dentin

The structure of dentin is an arrangement of microscopic channels, called dentinal tubules, which radiate outward from the pulp chamber to the exterior cementum or enamel border. The diameter of the dentinal tubules is largest near the pulp (about $2.5\text{ }\mu\text{m}$) and smallest (about 900 nm) at the junction of dentin and enamel. The carious process continues through the dentinal tubules, which are responsible for the triangular patterns resulting from the progression of caries deep into the tooth. The tubules also allow caries to progress faster.

In response, the fluid inside the tubules bring immunoglobulins from the immune system to fight the bacterial infection. At the same time, there is an increase of mineralization of the surrounding tubules. This results in a constriction of the tubules, which is an attempt to slow the bacterial progression. In addition, as the acid from the bacteria demineralizes the hydroxyapatite crystals, calcium and phosphorus are released, allowing for the

precipitation of more crystals which fall deeper into the dentinal tubule. These crystals form a barrier and slow the advancement of caries. After these protective responses, the dentin is considered sclerotic.

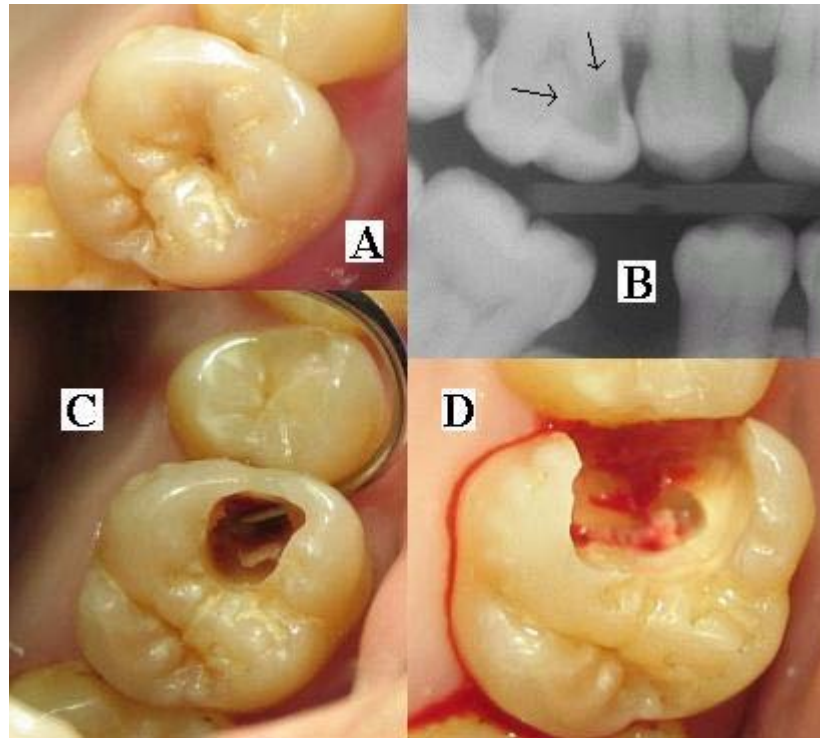
Fluids within dentinal tubules are believed to be the mechanism by which pain receptors are triggered within the pulp of the tooth. Since sclerotic dentin prevents the passage of such fluids, pain that would otherwise serve as a warning of the invading bacteria may not develop at first. Consequently, dental caries may progress for a long period of time without any sensitivity of the tooth, allowing for greater loss of tooth structure.

Tertiary dentin

In response to dental caries, there may be production of more dentin toward the direction of the pulp. This new dentin is referred to as tertiary dentin. Tertiary dentin is produced to protect the pulp for as long as possible from the advancing bacteria. As more tertiary dentin is produced, the size of the pulp decreases. This type of dentin has been subdivided according to the presence or absence of the original odontoblasts. If the odontoblasts survive long enough to react to the dental caries, then the dentin produced is called "reactionary" dentin. If the odontoblasts are killed, the dentin produced is called "reparative" dentin.

In the case of reparative dentin, other cells are needed to assume the role of the destroyed odontoblasts. Growth factors, especially TGF- β , are thought to initiate the production of reparative dentin by fibroblasts and mesenchymal cells of the pulp. Reparative dentin is produced at an average of 1.5 $\mu\text{m}/\text{day}$, but can be increased to 3.5 $\mu\text{m}/\text{day}$. The resulting dentin contains irregularly shaped dentinal tubules which may not line up with existing dentinal tubules. This diminishes the ability for dental caries to progress within the dentinal tubules.

Diagnosis



(A) A small spot of decay visible on the surface of a tooth. **(B)** The radiograph reveals an extensive region of demineralization within the dentin (arrows). **(C)** A hole is discovered on the side of the tooth at the beginning of decay removal. **(D)** All decay removed.

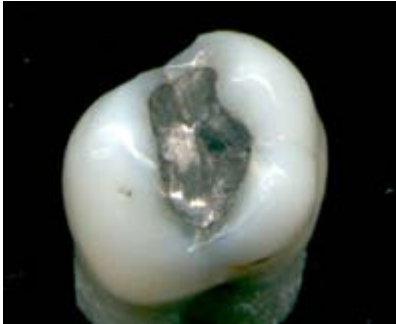Primary diagnosis involves inspection of all visible tooth surfaces using a good light source, dental mirror and explorer. Dental radiographs (X-rays) may show dental caries before it is otherwise visible, particularly caries between the teeth. Large dental caries are often apparent to the naked eye, but smaller lesions can be difficult to identify. Visual and tactile inspection along with radiographs are employed frequently among dentists, particularly to diagnose pit and fissure caries. Early, uncavitated caries is often diagnosed by blowing air across the suspect surface, which removes moisture and changes the optical properties of the unmineralized enamel.

Some dental researchers have cautioned against the use of dental explorers to find caries. In cases where a small area of tooth has begun demineralizing but has not yet cavitated, the pressure from the dental explorer could cause a cavity. Since the carious process is reversible before a cavity is present, it may be possible to arrest the caries with fluoride and remineralize the tooth surface. When a cavity is present, a restoration will be needed to replace the lost tooth structure.

At times, pit and fissure caries may be difficult to detect. Bacteria can penetrate the enamel to reach dentin, but then the outer surface may remineralize, especially if fluoride is present. These caries, sometimes referred to as "hidden caries", will still be visible on

x-ray radiographs, but visual examination of the tooth would show the enamel intact or minimally perforated.

Treatment

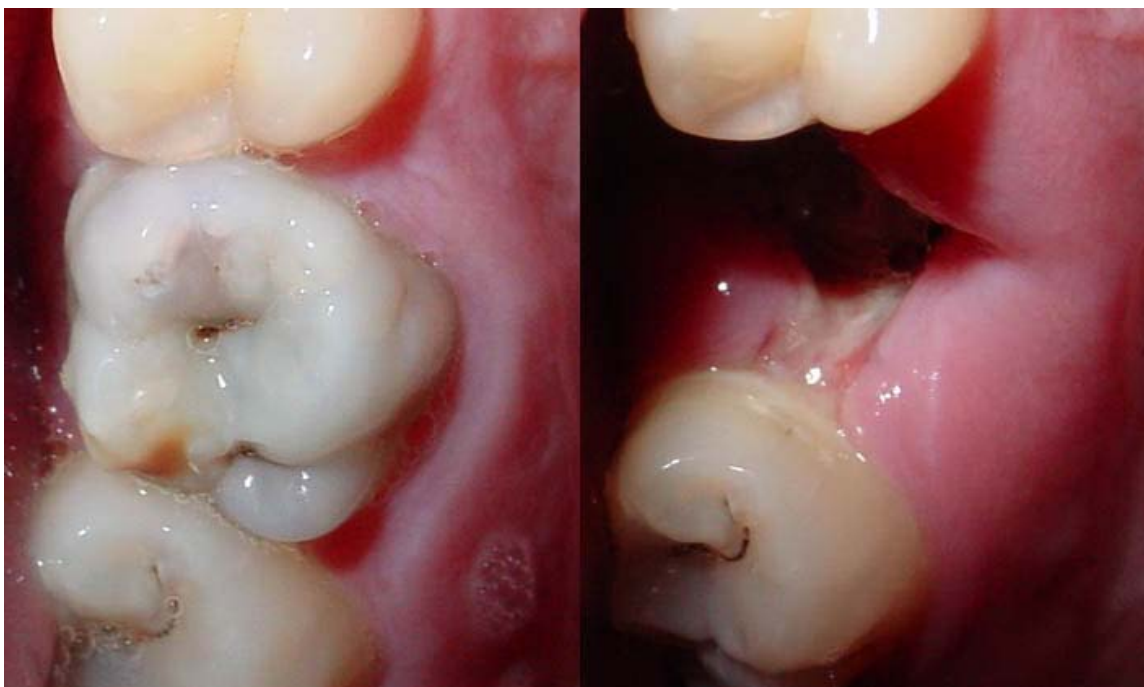

An amalgam used as a restorative material in a tooth

Destroyed tooth structure does not fully regenerate, although remineralization of very small carious lesions may occur if dental hygiene is kept at optimal level. For the small lesions, topical fluoride is sometimes used to encourage remineralization. For larger lesions, the progression of dental caries can be stopped by treatment. The goal of treatment is to preserve tooth structures and prevent further destruction of the tooth.

Generally, early treatment is less painful and less expensive than treatment of extensive decay. Anesthetics—local, nitrous oxide ("laughing gas"), or other prescription medications—may be required in some cases to relieve pain during or following treatment or to relieve anxiety during treatment. A dental handpiece ("drill") is used to remove large portions of decayed material from a tooth. A spoon, a dental instrument used to remove decay carefully, is sometimes employed when the decay in dentin reaches near the pulp. Once the decay is removed, the missing tooth structure requires a dental restoration of some sort to return the tooth to functionality and aesthetic condition.

Restorative materials include dental amalgam, composite resin, porcelain, and gold. Composite resin and porcelain can be made to match the color of a patient's natural teeth and are thus used more frequently when aesthetics are a concern. Composite restorations are not as strong as dental amalgam and gold; some dentists consider the latter as the only advisable restoration for posterior areas where chewing forces are great. When the decay is too extensive, there may not be enough tooth structure remaining to allow a restorative material to be placed within the tooth. Thus, a crown may be needed. This restoration appears similar to a cap and is fitted over the remainder of the natural crown of the tooth. Crowns are often made of gold, porcelain, or porcelain fused to metal.



A tooth with extensive caries eventually requiring extraction

In certain cases, endodontic therapy may be necessary for the restoration of a tooth. Endodontic therapy, also known as a "root canal", is recommended if the pulp in a tooth dies from infection by decay-causing bacteria or from trauma. During a root canal, the pulp of the tooth, including the nerve and vascular tissues, is removed along with decayed portions of the tooth. The canals are instrumented with endodontic files to clean and shape them, and they are then usually filled with a rubber-like material called gutta percha. The tooth is filled and a crown can be placed. Upon completion of a root canal, the tooth is now non-vital, as it is devoid of any living tissue.

An extraction can also serve as treatment for dental caries. The removal of the decayed tooth is performed if the tooth is too far destroyed from the decay process to effectively restore the tooth. Extractions are sometimes considered if the tooth lacks an opposing tooth or will probably cause further problems in the future, as may be the case for wisdom teeth. Extractions may also be preferred by patients unable or unwilling to undergo the expense or difficulties in restoring the tooth.

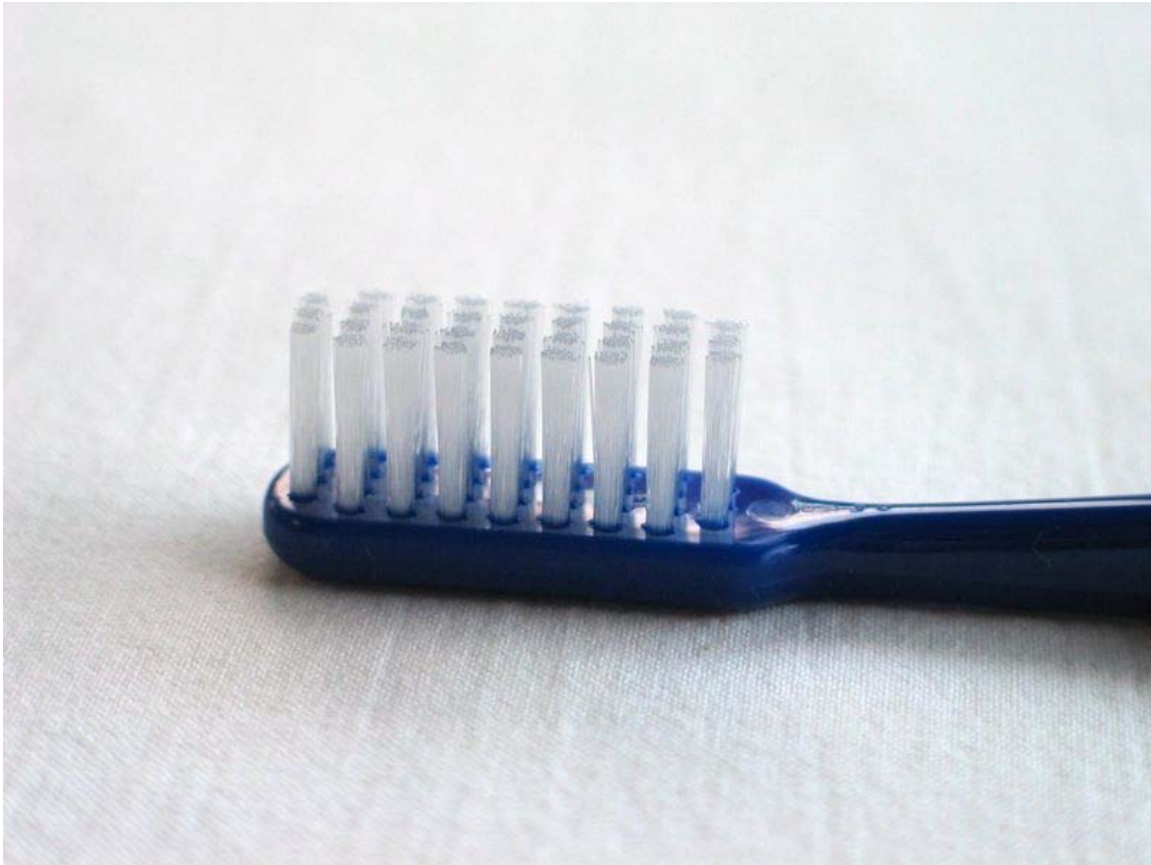Medicinal plants in the treatment of dental caries

S. No	Botanical Name	Part used	Inhibition Organisms
1.	Acacia leucophloea	Bark	Streptococcus mutans
2.	Albizia lebbeck	Bark	Streptococcus mutans
3.	Abies canadensis	Whole plant	Streptococcus mutans
4.	Aristolochia	Whole plant	Streptococcus mutans

	cymbifera		
5.	Annona senegalensis	Whole plant	Streptococcus mutans
6.	Albizia julibrissin	Whole plant	Streptococcus mutans
7.	Allium sativum	Bulbs	Streptococcus mutans
8.	Anacyclus pyrethrum	Root	Streptococcus mutans
9.	Areca catechu	Nuts	Streptococcus mutans
10.	Breynia nivosus	Whole plant	Streptococcus mutans
14.	Citrus medica	Roots	Streptococcus mutans
15.	Coptidis rhizoma	Whole plant	Streptococcus mutans
16.	Caesalpinia martius	Fruits	Streptococcus mutans, Streptococcus oralis, Lactobacillus casei
17.	Cocos nucifera	Whole plant	Streptococcus mutans
18.	Caesalpinia pyramidalis	Whole plant	Streptococcus mutans
19.	Chelidonium majus	Whole plant	Streptococcus mutans
20.	Drosera peltata	Whole plant	Streptococcus mutans, Streptococcus sobrinus
21.	Embelia ribes	Fruit	Streptococcus mutans
22.	Erythrina variegata	Root	Streptococcus mutans, Streptococcus sanguis
23.	Euclea natalensis	Whole plant	Streptococcus mutans
24.	Ficus microcarpa	Aerial part	Streptococcus mutans
25.	Gymnema Sylvester	Leaves,Roots	Streptococcus mutans
27.	Glycyrrhiza glabra	Root	Streptococcus mutans
28.	Hamamelis virginiana	Leaves	Preveotella spp., Actinomyces odontolyticus
29.	Harungana madagascariensis	Leaves	Actinomyces, Fusobacterium, Lactobacillus, Prevotella, Propionibacterium, Streptococcus spp.
30.	Helichrysum italicum	Whole plant	Streptococcus mutans, Streptococcus sanguis, Streptococcus sobrinus
31.	Ginkgo biloba	Whole plant	Streptococcus mutans
32.	Juniperus virginiana	Whole plant	Streptococcus mutans
33.	Kaempferia pandurata	Dried rhizomes, root	Streptococcus mutans
34.	Legenaria siceraria	Leaves	Streptococcus mutans
35.	Mentha arvensis	Leaves	Streptococcus mutans
36.	Mikania lavigata	Aerial parts	Streptococcus mutans, Streptococcus sobrinus
37.	Mikania glomerata	Whole plant	Streptococcus cricetus
38.	Melissa officinalis	Whole plant	Streptococcus mutans, Streptococcus sanguis

39.	<i>Magnolia grandiflora</i>	Whole plant	<i>Streptococcus mutans</i> , <i>Streptococcus sanguis</i>
40.	<i>Melissa officinalis</i>	Whole plant	<i>Streptococcus mutans</i> , <i>Streptococcus sanguis</i>
41.	<i>Magnolia grandiflora</i>	Whole plant	<i>Streptococcus mutans</i> , <i>Streptococcus sanguis</i>
42.	<i>Nicotiana tabacum</i>	leaves	<i>Streptococcus mutans</i>
43.	<i>Physalis angulata</i>	Flower	<i>Streptococcus mutans</i>
44.	<i>Pinus virginiana</i>	Whole plant	<i>Streptococcus mutans</i>
45.	<i>Pistacia lentiscus</i>	mastic gum	<i>Porphyromonas gingivalis</i>
46.	<i>Pistacia vera</i>	Whole plant	oral <i>Streptococci</i>
47.	<i>Piper cubeba</i>	Whole plant	periodontal pathogens
48.	<i>Polygonum cuspidatum</i>	Root	<i>Streptococcus mutans</i> , <i>Streptococcus sobrinus</i>
49.	<i>Rheedia brasiliensis</i>	Fruit	<i>Streptococcus mutans</i>
50.	<i>Rhus coriaria</i>	Whole plant	<i>Streptococcus mutans</i> , <i>Streptococcus sanguis</i>
51.	<i>Rhus coriaria</i>	Whole plant	<i>Streptococcus mutans</i> , <i>Streptococcus sanguis</i>
52.	<i>Rosmarinus officinalis</i>	Whole plant	<i>Streptococcus mutans</i>
53.	<i>Quercus infectoria</i>	Gall	<i>Streptococcus mutans</i>
54.	<i>Rhus coriaria</i>	Whole plant	<i>Streptococcus mutans</i> , <i>Streptococcus sanguis</i>
55.	<i>Syzygium cumini</i>	Bark	<i>Streptococcus mutans</i>
56.	<i>Sassafras albidum</i>	Whole plant	<i>Streptococcus mutans</i>
57.	<i>Solanum xathaocarpum</i>	Whole plant	<i>Streptococcus mutans</i>
58.	<i>Syzygium aromaticum</i>	Dried flower	<i>Staphylococcus aureus</i>
59.	<i>Thymus vulgaris</i>	Whole plant	<i>Streptococcus mutans</i> , <i>Streptococcus sanguis</i>
60.	<i>Tanacetum vulgare</i>	Whole plant	<i>Staphylococcus aureus</i>
61.	<i>Thuja plicata</i>	Whole plant	<i>Staphylococcus aureus</i>
62.	<i>Ziziphus joazeiro</i>	Whole plant	<i>Staphylococcus aureus</i>

Prevention



Toothbrushes are commonly used to clean teeth

Oral hygiene

Personal hygiene care consists of proper brushing and flossing daily. The purpose of oral hygiene is to minimize any etiologic agents of disease in the mouth. The primary focus of brushing and flossing is to remove and prevent the formation of plaque. Plaque consists mostly of bacteria. As the amount of bacterial plaque increases, the tooth is more vulnerable to dental caries when carbohydrates in the food are left on teeth after every meal or snack. A toothbrush can be used to remove plaque on accessible surfaces, but not between teeth or inside pits and fissures on chewing surfaces. When used correctly, dental floss removes plaque from areas which could otherwise develop proximal caries. Other adjunct hygiene aids include interdental brushes, water picks, and mouthwashes.

However oral hygiene is probably more effective at preventing gum disease than tooth decay. Food is forced inside pits and fissures under chewing pressure, leading to carbohydrate fueled acid demineralisation where the brush, fluoride toothpaste and saliva have no access to remove trapped food, neutralise acid or remineralise demineralised tooth like on other more accessible tooth surfaces food to be trapped. (Occlusal caries accounts for between 80 and 90 percent of caries in children (Weintraub, 2001). Chewing fibre like celery after eating, forces saliva inside trapped food to dilute any carbohydrate

like sugar, neutralise acid and remineralise demineralised tooth. (The teeth at highest risk for carious lesions are the first and second permanent molars.)

Professional hygiene care consists of regular dental examinations and cleanings. Sometimes, complete plaque removal is difficult, and a dentist or dental hygienist may be needed. Along with oral hygiene, radio-graphs may be taken at dental visits to detect possible dental caries development in high risk areas of the mouth.

Dietary modification

For dental health, frequency of sugar intake is more important than the amount of sugar consumed. In the presence of sugar and other carbohydrates, bacteria in the mouth produce acids which can demineralize enamel, dentin, and cementum. The more frequently teeth are exposed to this environment, the more likely dental caries are to occur. Therefore, minimizing snacking is recommended, since snacking creates a continual supply of nutrition for acid-creating bacteria in the mouth. Also, chewy and sticky foods (such as dried fruit or candy) tend to adhere to teeth longer, and consequently are best eaten as part of a meal. Brushing the teeth after meals is recommended. For children, the American Dental Association and the European Academy of Paediatric Dentistry recommend limiting the frequency of consumption of drinks with sugar, and not giving baby bottles to infants during sleep. Mothers are also recommended to avoid sharing utensils and cups with their infants to prevent transferring bacteria from the mother's mouth.

It has been found that milk and certain kinds of cheese like Cheddar can help counter tooth decay if eaten soon after the consumption of foods potentially harmful to teeth. Also, chewing gum containing xylitol (a sugar alcohol) is widely used to protect teeth in some countries, being especially popular in the Finnish candy industry. Xylitol's effect on reducing plaque is probably due to bacteria's inability to utilize it like other sugars. Chewing and stimulation of flavour receptors on the tongue are also known to increase the production and release of saliva, which contains natural buffers to prevent the lowering of pH in the mouth to the point where enamel may become demineralised.



Common dentistry trays used to deliver fluoride

Other preventive measures

The use of dental sealants is a means of prevention. A sealant is a thin plastic-like coating applied to the chewing surfaces of the molars. This coating prevents food being trapped inside pits and fissures in grooves under chewing pressure so resident plaque bacteria are deprived of carbohydrate that they change to acid demineralisation and thus prevents the formation of pit and fissure caries, the most common form of dental caries. Sealants are usually applied on the teeth of children, shortly after the molars erupt. Older people may also benefit from the use of tooth sealants, but their dental history and likelihood of caries formation are usually taken into consideration.

Calcium, as found in food such as milk and green vegetables, are often recommended to protect against dental caries. It has been demonstrated that calcium and fluoride supplements decrease the incidence of dental caries. Fluoride helps prevent decay of a tooth by binding to the hydroxyapatite crystals in enamel. The incorporated calcium makes enamel more resistant to demineralization and, thus, resistant to decay. Topical fluoride is also recommended to protect the surface of the teeth. This may include a fluoride toothpaste or mouthwash. Many dentists include application of topical fluoride solutions as part of routine visits.

Other products with little or less supportive scientific evidence for effectiveness for the purpose of remineralization include DCPD, ACP, calcium compounds, fluoride, and Enamelon.

Remineralization can also be performed professionally at the dentist.

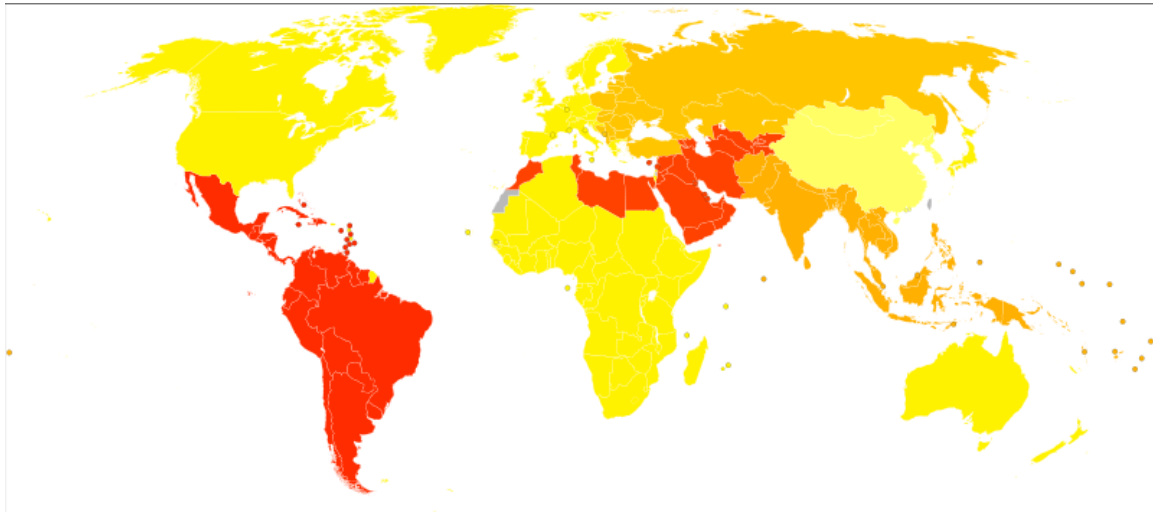
Furthermore, recent research shows that low intensity laser radiation of argon ion lasers may prevent the susceptibility for enamel caries and white spot lesions.

As bacteria are a major factor contributing to poor oral health, there is currently research to find a vaccine for dental caries. As of 2004, such a vaccine has been successfully tested on animals, and is in clinical trials for humans as of May 2006.

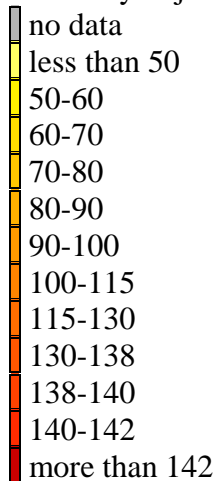
Chewing gum after eating promotes the flow of saliva which naturally reduces the acidic pH environment and promotes remineralization.

Xylitol lollies and gum also inhibit the growth of *Streptococcus mutans*.

Epidemiology



Disability-adjusted life year for dental caries per 100,000 inhabitants in 2004.



Worldwide, most children and an estimated ninety percent of adults have experienced caries, with the disease most prevalent in Asian and Latin American countries and least prevalent in African countries. In the United States, dental caries is the most common chronic childhood disease, being at least five times more common than asthma. It is the primary pathological cause of tooth loss in children. Between twenty-nine and fifty-nine percent of adults over the age of fifty experience caries.

The number of cases has decreased in some developed countries, and this decline is usually attributed to increasingly better oral hygiene practices and preventive measures such as fluoride treatment. Nonetheless, countries that have experienced an overall decrease in cases of tooth decay continue to have a disparity in the distribution of the disease. Among children in the United States and Europe, twenty percent of the population endures sixty to eighty percent of cases of dental caries. A similarly skewed distribution of the disease is found throughout the world with some children having none or very few caries and others having a high number. Australia, Nepal, and Sweden have a low incidence of cases of dental caries among children, whereas cases are more numerous in Costa Rica and Slovakia.

The classic "DMF" (decay/missing/filled) index is one of the most common methods for assessing caries prevalence as well as dental treatment needs among populations. This index is based on in-field clinical examination of individuals by using a probe, mirror and cotton rolls. Because the DMF index is done without X-ray imaging, it underestimates real caries prevalence and treatment needs.

History



An image from 1300s (A.D.) England depicting a dentist extracting a tooth with forceps

There is a long history of dental caries. Over a million years ago, hominids such as *Australopithecus* suffered from cavities. The largest increases in the prevalence of caries have been associated with dietary changes. Archaeological evidence shows that tooth decay is an ancient disease dating far into prehistory. Skulls dating from a million years ago through the neolithic period show signs of caries, excepting those from the Paleolithic and Mesolithic ages. The increase of caries during the neolithic period may be attributed to the increased consumption of plant foods containing carbohydrates. The beginning of rice cultivation in South Asia is also believed to have caused an increase in caries.

A Sumerian text from 5000 BC describes a "tooth worm" as the cause of caries. Evidence of this belief has also been found in India, Egypt, Japan, and China. Unearthed ancient skulls show evidence of primitive dental work. In Pakistan, teeth dating from around 5500 BC to 7000 BC show nearly perfect holes from primitive dental drills. The Ebers Papyrus, an Egyptian text from 1550 BC, mentions diseases of teeth. During the Sargonid dynasty of Assyria during 668 to 626 BC, writings from the king's physician specify the need to extract a tooth due to spreading inflammation. In the Roman Empire, wider consumption of cooked foods led to a small increase in caries prevalence. The Greco-Roman civilization, in addition to the Egyptian, had treatments for pain resulting from caries.

The rate of caries remained low through the Bronze Age and Iron Age, but sharply increased during the Middle Ages. Periodic increases in caries prevalence had been small in comparison to the 1000 AD increase, when sugar cane became more accessible to the Western world. Treatment consisted mainly of herbal remedies and charms, but sometimes also included bloodletting. The barber surgeons of the time provided services that included tooth extractions. Learning their training from apprenticeships, these health providers were quite successful in ending tooth pain and likely prevented systemic spread of infections in many cases. Among Roman Catholics, prayers to Saint Apollonia, the patroness of dentistry, were meant to heal pain derived from tooth infection.

There is also evidence of caries increase in North American Indians after contact with colonizing Europeans. Before colonization, North American Indians subsisted on hunter-gatherer diets, but afterwards there was a greater reliance on maize agriculture, which made these groups more susceptible to caries.

In the medieval Islamic world, Muslim physicians such as al-Gazzar and Avicenna (in *The Canon of Medicine*) provided the earliest known treatments for caries, though they also believed that it was caused by tooth worms as the ancients had. This was eventually proven false in 1200 by another Muslim dentist named Gaubari, who in his *Book of the Elite concerning the unmasking of mysteries and tearing of veils*, was the first to reject the idea of caries being caused by tooth worms, and he stated that tooth worms in fact do not even exist. The theory of the tooth worm was thus no longer accepted in the Islamic medical community from the 13th century onwards.

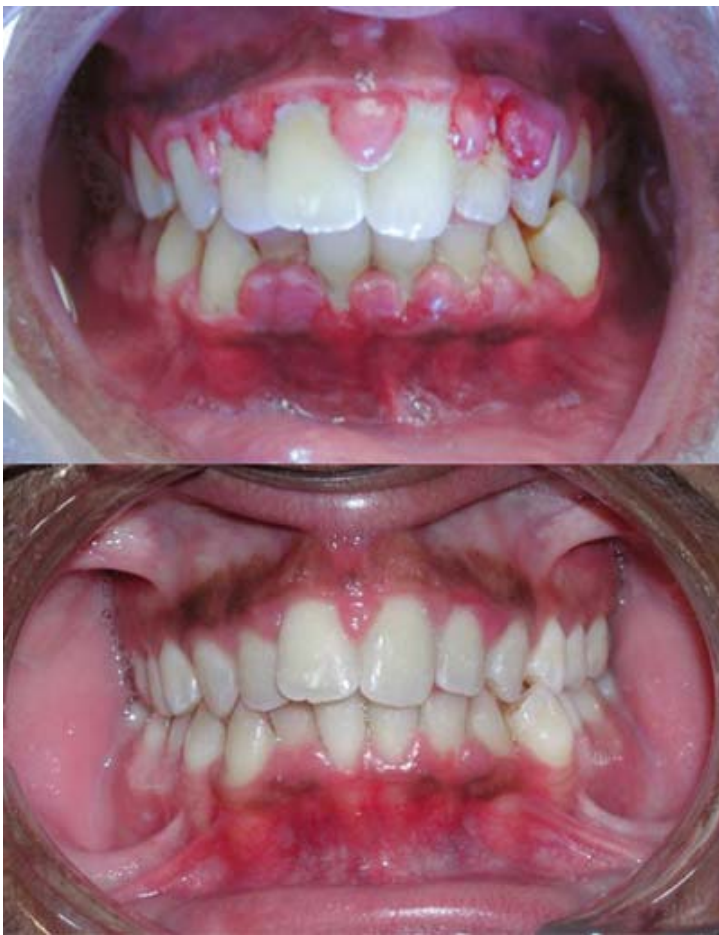During the European Age of Enlightenment, the belief that a "tooth worm" caused caries was also no longer accepted in the European medical community. Pierre Fauchard, known as the father of modern dentistry, was one of the first to reject the idea that worms caused tooth decay and noted that sugar was detrimental to the teeth and gingiva. In 1850, another sharp increase in the prevalence of caries occurred and is believed to be a result of widespread diet changes. Prior to this time, cervical caries was the most frequent type of caries, but increased availability of sugar cane, refined flour, bread, and sweetened tea corresponded with a greater number of pit and fissure caries.

In the 1890s, W.D. Miller conducted a series of studies that led him to propose an explanation for dental caries that was influential for current theories. He found that bacteria inhabited the mouth and that they produced acids which dissolved tooth structures when in the presence of fermentable carbohydrates. This explanation is known as the chemoparasitic caries theory. Miller's contribution, along with the research on plaque by G.V. Black and J.L. Williams, served as the foundation for the current explanation of the etiology of caries. Several of the specific strains of bacteria were identified in 1921 by Fernando E. Rodriguez Vargas.

Chapter 7

Gingivitis

Gingivitis



Severe gingivitis before (top) and after (bottom) a thorough mechanical debridement of the teeth and adjacent gum tissues.

ICD-10 K05.0-K05.1

ICD-9 523.0-523.1

DiseasesDB 34517

MedlinePlus

001056

MeSH

D005891

Gingivitis ("inflammation of the gum tissue") is a term used to describe non-destructive periodontal disease. The most common form of gingivitis is in response to bacterial biofilms (also called plaque) adherent to tooth surfaces, termed *plaque-induced gingivitis*, and is the most common form of periodontal disease. In the absence of treatment, gingivitis may progress to periodontitis, which is a destructive form of periodontal disease.

While in some sites or individuals, gingivitis never progresses to periodontitis, data indicates that periodontitis is always preceded by gingivitis.

Classification

As defined by the 1999 World Workshop in Clinical Periodontics, there are two primary categories of gingival diseases, each with numerous subgroups:

1. Dental plaque-induced gingival diseases
 1. Gingivitis associated with plaque only
 2. Gingival diseases modified by systemic factors
 3. Gingival diseases modified by medications
 4. Gingival diseases modified by malnutrition
2. Non-plaque-induced gingival lesions
 1. Gingival diseases of specific bacterial origin
 2. Gingival diseases of viral origin
 3. Gingival diseases of fungal origin
 4. Gingival diseases of genetic origin
 5. Gingival manifestations of systemic conditions
 6. Traumatic lesions
 7. Foreign body reactions
 8. Not otherwise specified

Signs and symptoms

The symptoms of gingivitis are somewhat non-specific and manifest in the gum tissue as the classic signs of inflammation:

- Swollen gums
- Bright red or purple gums
- Gums that are tender or painful to the touch
- Bleeding gums or bleeding after brushing

Additionally, the stippling that normally exists on the gum tissue of some individuals will often disappear and the gums may appear shiny when the gum tissue becomes swollen and stretched over the inflamed underlying connective tissue. The accumulation may also emit an unpleasant odor. When the gingiva are swollen, the epithelial lining of the gingival crevice becomes ulcerated and the gums will bleed more easily with even gentle brushing, and especially when flossing.

Cause

Because plaque-induced gingivitis is by far the most common form of gingival diseases, the following sections will deal primarily with this condition.

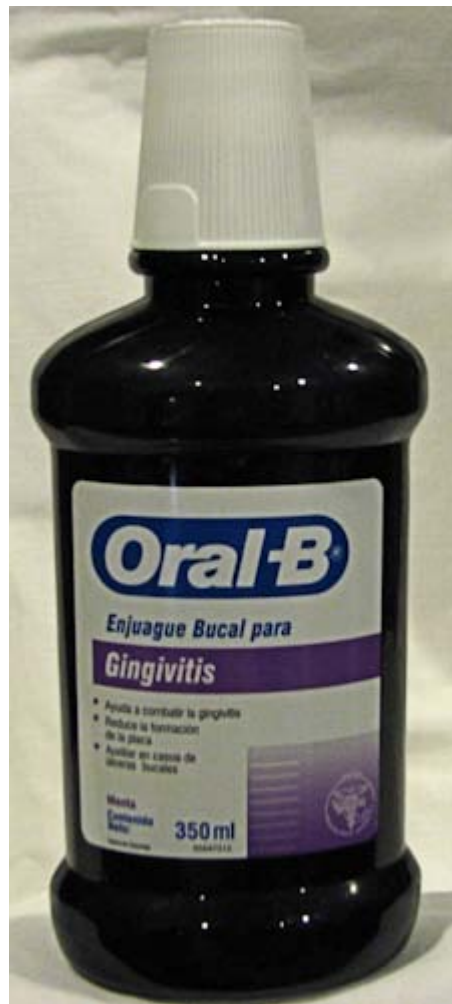The *etiology*, or cause, of plaque-induced gingivitis is bacterial plaque, which acts to initiate the body's host response. This, in turn, can lead to destruction of the gingival tissues, which may progress to destruction of the periodontal attachment apparatus. The plaque accumulates in the small gaps between teeth, in the gingival grooves and in areas known as *plaque traps*: locations that serve to accumulate and maintain plaque. Examples of plaque traps include bulky and overhanging restorative margins, clasps of removable partial dentures and calculus (tartar) that forms on teeth. Although these accumulations may be tiny, the bacteria in them produce chemicals, such as degradative enzymes, and toxins, such as lipopolysaccharide (LPS, otherwise known as endotoxin) or lipoteichoic acid (LTA), that promote an inflammatory response in the gum tissue. This inflammation can cause an enlargement of the gingiva and subsequent *pseudopocket* formation.

Diagnosis

It is recommended that a dental hygienist or dentist be seen after the signs of gingivitis appear. A dental hygienist or dentist will check for the symptoms of gingivitis, and may also examine the amount of plaque in the oral cavity. A dental hygienist or dentist will also look for signs of periodontitis using X-rays or periodontal probing as well as other methods.

If gingivitis is not responsive to treatment, referral to a periodontist (a specialist in diseases of the gingiva and bone around teeth and dental implants) for further treatment may be necessary.

Prevention



OTC anti-gingivitis mouthwash containing chlorhexidine from Mexico

Gingivitis can be prevented through regular oral hygiene that includes daily brushing and flossing. Interdental brushes are also useful in cleaning the teeth from plaque. Hydrogen peroxide, saline, alcohol or chlorhexidine mouth washes may also be employed. In a recent clinical study, the beneficial effect of hydrogen peroxide on gingivitis has been highlighted. Rigorous plaque control programs along with periodontal scaling and curettage also have proved to be helpful, although according to the American Dental Association, periodontal scaling and root planing are considered as a treatment to periodontal disease, not as a preventive treatment for periodontal disease. In a 1997 review of effectiveness data the U.S. Food and Drug Administration (FDA) found clear evidence which showed that toothpaste containing triclosan was effective in preventing gingivitis.

In many countries, such as the United States, mouthwashes containing chlorhexidine are available only by prescription.

Researchers analyzed government data on calcium consumption and periodontal disease indicators in nearly 13,000 U.S. adults. They found that men and women who had calcium intakes of fewer than 500 milligrams, or about half the recommended dietary allowance, were almost twice as likely to have gum disease, as measured by the loss of attachment of the gums from the teeth. The association was particularly evident for people in their 20s and 30s.

Preventing gum disease may also benefit a healthy heart. According to physicians with The Institute for Good Medicine at the Pennsylvania Medical Society, good oral health can reduce risk of cardiac events. Poor oral health can lead to infections that can travel within the bloodstream.

Treatment

The focus of treatment for gingivitis is removal of the etiologic (causative) agent, plaque. Therapy is aimed at the reduction of oral bacteria, and may take the form of regular periodic visits to a dental professional together with adequate oral hygiene home care. Thus, several of the methods used in the prevention of gingivitis can also be used for the treatment of manifest gingivitis, such as scaling, root planing, curettage, mouth washes containing chlorhexidine or hydrogen peroxide, and flossing. Interdental brushes also help remove any causative agents.

Recent scientific studies have also shown the beneficial effects of mouthwashes with essential oils.

Complications

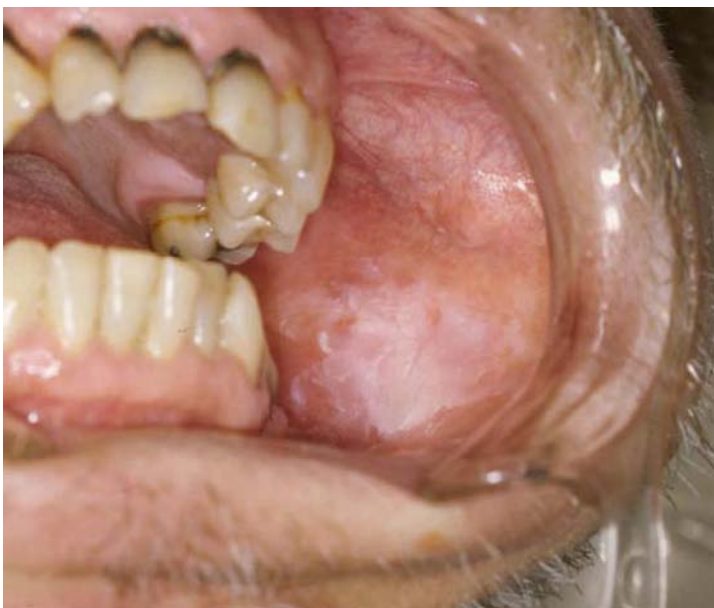- Tooth loss
- Recurrence of gingivitis
- Periodontitis
- Infection or abscess of the gingiva or the jaw bones
- Trench mouth (bacterial infection and ulceration of the gums)

Chapter 8

Leukoplakia and Mucous Cyst of the Oral Mucosa

Leukoplakia

Leukoplakia



The white lesion is an example of leukoplakia.

ICD-10 K13.2, N48.0, N88.0, N89.4, N90.4

ICD-9 528.6, 530.83, 607.0, 622.2, 623.1, 624.0

DiseasesDB 7438

MedlinePlus 001046

MeSH D007971

Leukoplakia is a clinical term used to describe patches of keratosis . It is visible as adherent white patches on the mucous membranes of the oral cavity, including the tongue, but also other areas of the gastro-intestinal tract, urinary tract and the genitals. The clinical appearance is highly variable. Leukoplakia is not a specific disease entity, but is diagnosis of exclusion. It must be distinguished from diseases that may cause similar white lesions, such as candidiasis or lichen planus.

It is sometimes described as precancerous.. It is also associated with smoking.

Tobacco, either smoked or chewed, is considered to be the main culprit in its development. (1998-2010 Mayo Foundation for Medical Education and Research (MFMER)).

The term "candidal leukoplakia" is sometimes used to describe certain types of oral candidiasis.

Although the term "leukoplakia" often applies to conditions of the mouth, it can also be used to describe conditions of the genitals and urinary tract.

Incidence and prevalence

Leukoplakic lesions are found in approximately 3% of the world's population. Like erythroplakia, leukoplakia is usually found in adults between 40 and 70 years of age, with a 2:1 male predominance.

Causes

Leukoplakia is primarily caused by the use of tobacco. Other possible etiological agents implicated are HPV's, Candida albicans and possibly alcohol. Simultaneously serum levels of patients with leukoplakia were found to be low in Vit A,B-12,C & folic acid,in a study conducted in India. Most result from chronic irritation of mucous membranes by carcinogens. Bloodroot, otherwise known as sanguinaria, is also believed to be associated with leukoplakia.

5% to 25% of leukoplakias are premalignant lesions; therefore, all leukoplakias should be treated as premalignant lesions by dentists and physicians - they require histologic evaluation or biopsy. Hairy leukoplakia, which is associated with HIV infection and other diseases of severe immune deficiency can go on to develop lymphoma when associated with HIV.

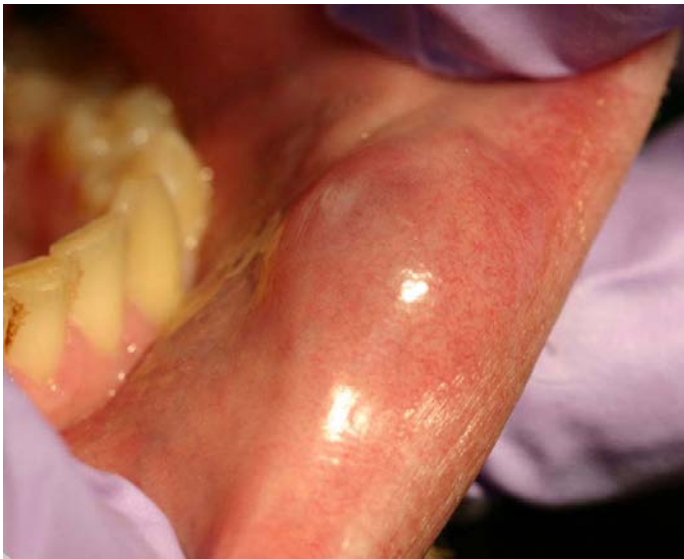Treatment

The treatment of leukoplakia mainly involves avoidance of predisposing factors — tobacco cessation, smoking, quitting betel chewing, abstinence from alcohol — and avoidance of chronic irritants, e.g., the sharp edges of teeth. A biopsy should be done, and the lesion surgically excised if pre-cancerous changes or cancer is detected.

Taking beta-carotene orally seems to induce remission in patients with oral leukoplakia. Further research is needed to confirm these results.

Mucous cyst of the oral mucosa

Mucous cyst of the oral mucosa



A mucocoele on the lower lip.

ICD-10	K11.6
ICD-9	527.6
DiseasesDB	30713
eMedicine	derm/274
MeSH	D009078

A "mucous cyst of the oral mucosa" (also known as a "mucocoele") is a clinical term that refers to two related phenomena: **mucus extravasation phenomenon**, and **mucus retention cyst**. The former is a swelling of connective tissue consisting of collected mucin due to a ruptured salivary gland duct usually caused by local trauma, in the case of mucus extravasation phenomenon, and an obstructed salivary duct in the case of a mucus retention cyst. The mucocoele has a bluish translucent color, and is more commonly found in children and young adults.

It can be considered a polyp or a cyst.

Locations

The most common location to find a mucocele is the surface of the lower lip. It can also be found on the inner side of the cheek (known as the buccal mucosa), on the anterior ventral tongue, and the floor of the mouth. When found on the floor of the mouth, the mucocele is referred to as a ranula. They are rarely found on the upper lip. As their name suggests they are basically mucus lined cysts and they can also occur in the Paranasal sinuses most commonly the frontal sinuses, the frontoethmoidal region and also in the maxillary sinus. Sphenoid sinus involvement is extremely rare. When the lumen of the vermiform appendix gets blocked due to any factor, again a mucocele can form.

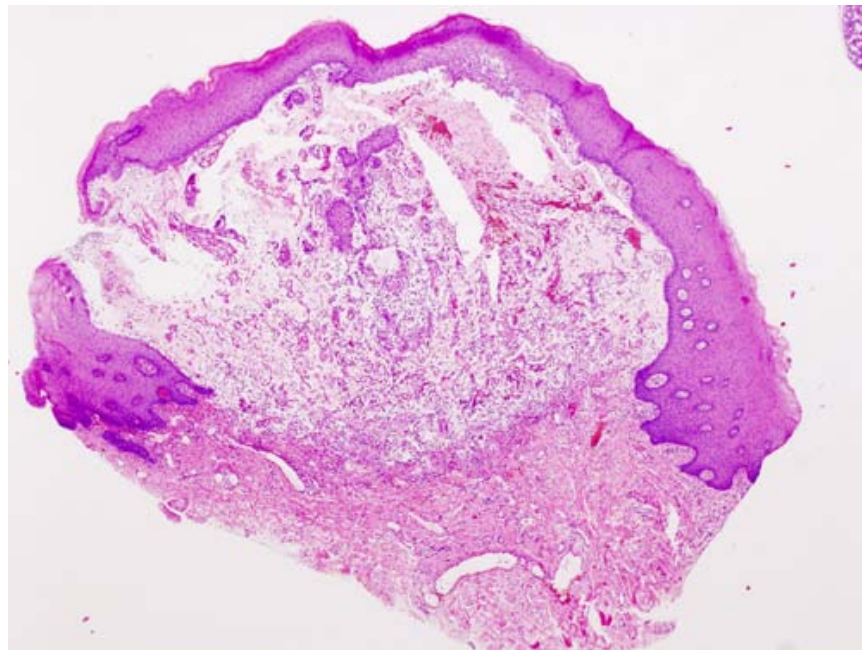
Characteristics

The size of oral mucoceles vary from 1 mm to several centimeters and they usually are slightly transparent with a blue tinge. On palpation, mucoceles may appear fluctuant but can also be firm. Their duration lasts from days to years, and may have recurrent swelling with occasional rupturing of its contents.

Variations

A variant of a mucocele is found on the palate, retromolar pad, and posterior buccal mucosa. Known as a "superficial mucocele", this type presents as single or multiple vesicles and bursts into an ulcer. Despite healing after a few days, superficial mucoceles recur often in the same location.

Histology



Histopathologic image of extravasation type mucocele of the lower lip. H & E stain.

Microscopically, mucocoeles appears as granulation tissue surrounding mucin. Since inflammation occurs concurrently, neutrophils and foamy histiocytes usually are present.

Treatment

Some mucocoeles spontaneously resolve on their own after a short time. Others are chronic and require surgical removal. Recurrence may occur, and thus the adjacent salivary gland is excised as a preventive measure.


Several types of procedures are available for the surgical removal of mucocoeles. These include laser and minimally-invasive techniques which means recovery times are reduced drastically.

A non-surgical option that may be effective for a small or newly identified mucocle is to rinse the mouth thoroughly with salt water (one tablespoon of salt per cup) four to six times a day for a few days. This may draw out the fluid trapped underneath the skin without further damaging the surrounding tissue. If the mucocoele persists, individuals should see a doctor to discuss further treatment.

Chapter 9

Periodontitis

Periodontal disease



This radiograph shows significant bone loss between the two roots of a tooth (black region). The spongy bone has receded due to infection under tooth, reducing the bony support for the tooth.

ICD-10	K05.4
DiseasesDB	29362
MedlinePlus	001059
MeSH	D010518

Periodontitis is a set of inflammatory diseases affecting the periodontium, i.e., the tissues that surround and support the teeth. Periodontitis involves progressive loss of the alveolar bone around the teeth, and if left untreated, can lead to the loosening and subsequent loss of teeth. Periodontitis is caused by microorganisms that adhere to and grow on the tooth's surfaces, along with an overly aggressive immune response against these microorganisms. A diagnosis of periodontitis is established by inspecting the soft

gum tissues around the teeth with a probe (i.e. a *clinical exam*) and by evaluating the patient's x-ray films (i.e. a *radiographic exam*), to determine the amount of bone loss around the teeth. Specialists in the treatment of periodontitis are periodontists; their field is known as "periodontology" or "periodontics".

The word "periodontitis" comes from *peri* ("around"), *odont* ("tooth") and *-itis* ("inflammation").

Classification

The 1999 classification system for periodontal diseases and conditions listed seven major categories of periodontal diseases, of which the last six are termed *destructive* periodontal disease because they are essentially irreversible. The seven categories are as follows:

1. Gingivitis
2. Chronic periodontitis
3. Aggressive periodontitis
4. Periodontitis as a manifestation of systemic disease
5. Necrotizing ulcerative gingivitis/periodontitis
6. Abscesses of the periodontium
7. Combined periodontic-endodontic lesions

Moreover, terminology expressing both the extent and severity of periodontal diseases are appended to the terms above to denote the specific diagnosis of a particular patient or group of patients.

Extent

The *extent* of disease refers to the proportion of the dentition affected by the disease in terms of percentage of sites. Sites are defined as the positions at which probing measurements are taken around each tooth and, generally, six probing sites around each tooth are recorded, as follows:

1. mesiobuccal
2. mid-buccal
3. distobuccal
4. mesiolingual
5. mid-lingual
6. distolingual

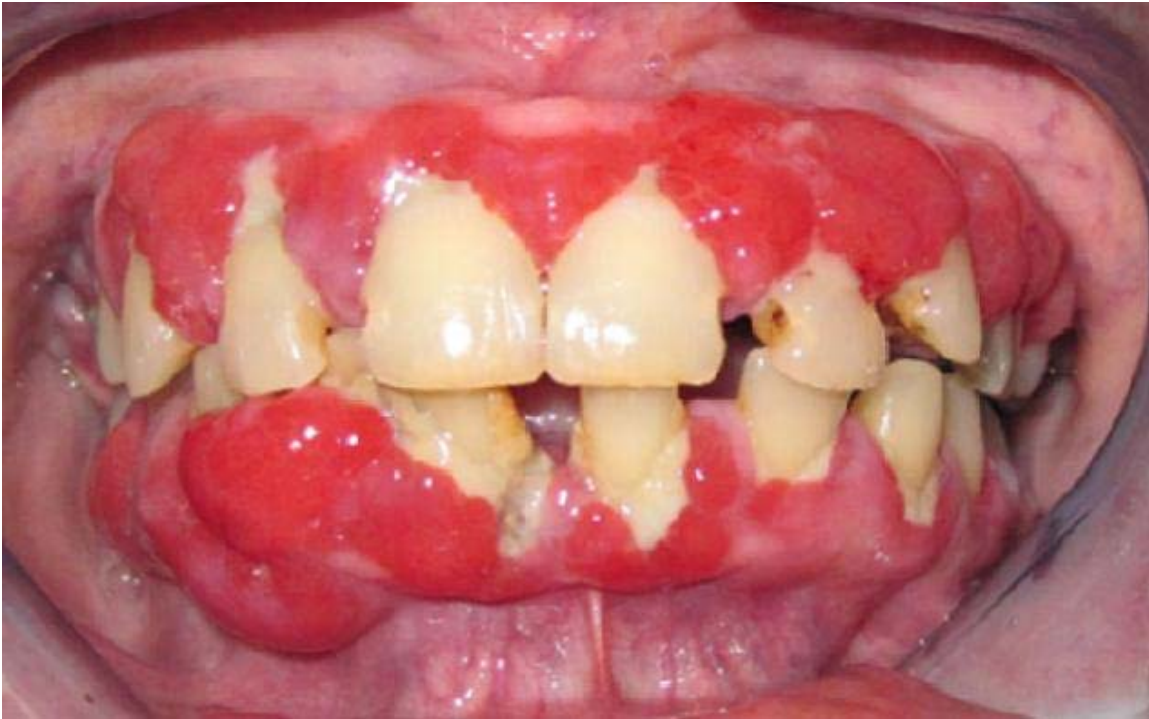If up to 30% of sites in the mouth are affected, the manifestation is classification as *localized*; for more than 30%, the term *generalized* is used.

Severity

The *severity* of disease refers to the amount of periodontal ligament fibers that have been lost, termed *clinical attachment loss*. According to the American Academy of Periodontology, the classification of severity is as follows:

- *Mild*: 1–2 mm of attachment loss
- *Moderate*: 3–4 mm of attachment loss
- *Severe*: ≥ 5 mm of attachment loss

Signs and symptoms



Periodontitis manifesting as painful, red, swollen gums, with abundant plaque

In the early stages, periodontitis has very few symptoms and in many individuals the disease has progressed significantly before they seek treatment. Symptoms may include the following:

- Redness or bleeding of gums while brushing teeth, using dental floss or biting into hard food (e.g. apples) (though this may occur even in gingivitis, where there is no attachment loss)
- Gum swelling that recurs
- Halitosis, or bad breath, and a persistent metallic taste in the mouth
- Gingival recession, resulting in apparent lengthening of teeth. (This may also be caused by heavy handed brushing or with a stiff tooth brush.)

- Deep pockets between the teeth and the gums (pockets are sites where the attachment has been gradually destroyed by collagen-destroying enzymes, known as *collagenases*)
- Loose teeth, in the later stages (though this may occur for other reasons as well)

Patients should realize that the gingival inflammation and bone destruction are largely painless. Hence, people may wrongly assume that painless bleeding after teeth cleaning is insignificant, although this may be a symptom of progressing periodontitis in that patient.

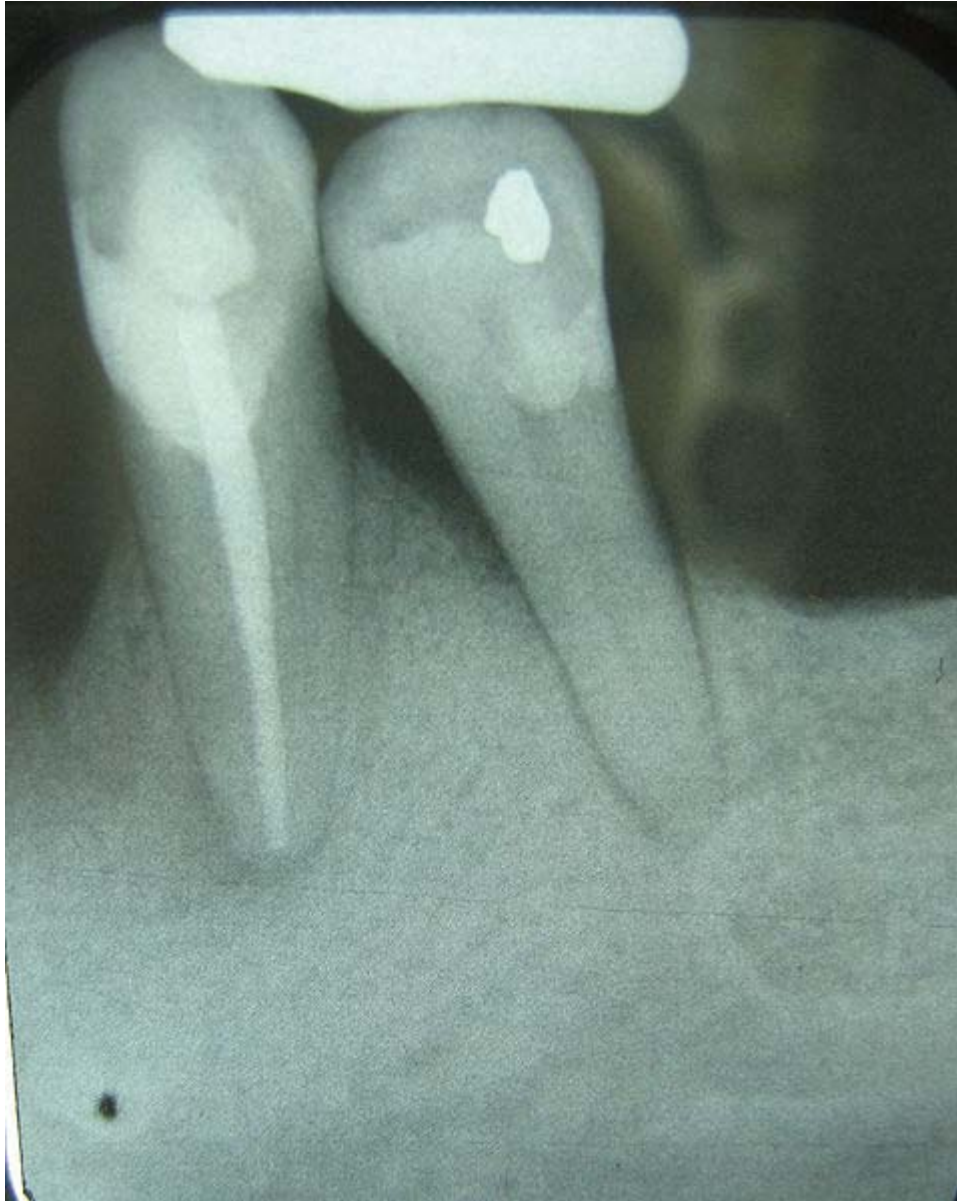Effects outside the mouth

Periodontitis has been linked to increased inflammation in the body such as indicated by raised levels of C-reactive protein and Interleukin-6. It is through this linked to increased risk of stroke, myocardial infarction, and atherosclerosis. It also linked in those over 60 years of age to impairments in delayed memory and calculation abilities.

Causes

Periodontitis is an inflammation of the periodontium, i.e., the tissues that support the teeth. The periodontium consists of four tissues:

- gingiva, or gum tissue;
- cementum, or outer layer of the roots of teeth;
- alveolar bone, or the bony sockets into which the teeth are anchored;
- periodontal ligaments (PDLs), which are the connective tissue fibers that run between the cementum and the alveolar bone.

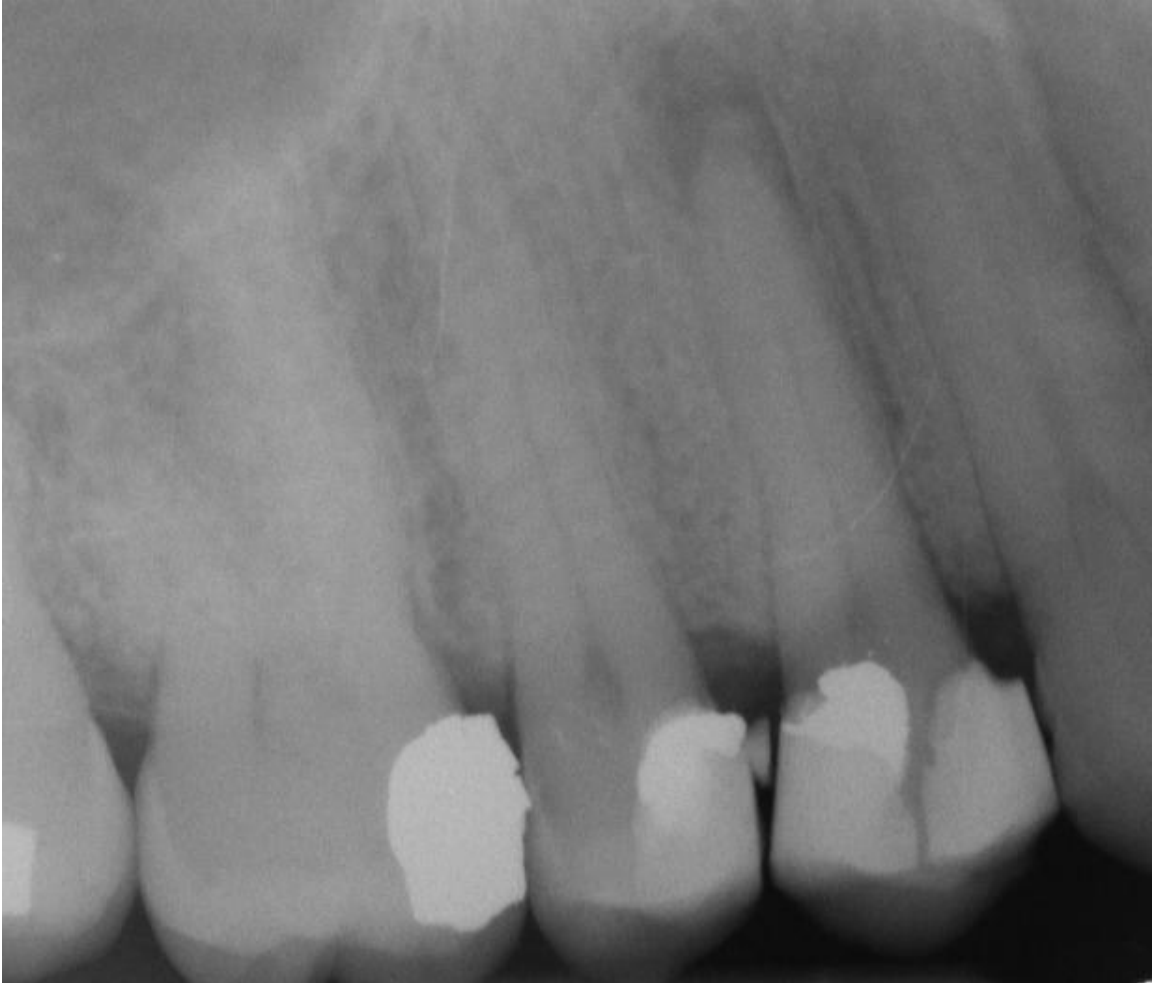

This X-ray film displays two lone-standing mandibular teeth, the lower left first premolar and canine, exhibiting severe bone loss of 30–50%. Widening of the periodontal ligament surrounding the premolar is due to secondary occlusal trauma.

The primary etiology (cause) of gingivitis is poor oral hygiene which leads to the accumulation of a mycotic and bacterial matrix at the gum line, called dental plaque. Other contributors are poor nutrition and underlying medical issues such as diabetes. New finger nick tests have been approved by the Food and Drug Administration in the US, and are being used in dental offices to identify and screen patients for possible contributory causes of gum disease such as diabetes.

In some people, gingivitis progresses to periodontitis - with the destruction of the gingival fibers, the gum tissues separate from the tooth and deepened sulcus, called a

periodontal pocket. Subgingival microorganism (those that exist under the gum line) colonize the periodontal pockets and cause further inflammation in the gum tissues and progressive bone loss. Examples of secondary etiology are those things that, by definition, cause microbial plaque accumulation, such as restoration overhangs and root proximity.



The excess restorative material that exceeds the natural contours of restored teeth, such as these, are termed "overhangs", and serve to trap microbial plaque, potentially leading to localized periodontitis.

Smoking is another factor that increases the occurrence of periodontitis, directly or indirectly, and may interfere with or adversely affect its treatment.

If left undisturbed, microbial plaque calcifies to form calculus, which is commonly called tartar. Calculus above and below the gum line must be removed completely by the dental hygienist or dentist to treat gingivitis and periodontitis. Although the primary cause of both gingivitis and periodontitis is the microbial plaque that adheres to the tooth surface, there are many other modifying factors. A very strong risk factor is one's genetic susceptibility. Several conditions and diseases, including Down syndrome, diabetes, and

other diseases that affect one's resistance to infection also increase susceptibility to periodontitis.

Another factor that makes periodontitis a difficult disease to study is that human host response can also affect the alveolar bone resorption. Host response to the bacterial-mycotic insult is mainly determined by genetics; however, immune development may play some role in susceptibility.

According to some researches periodontitis may be associated with higher stress.

Prevention

Daily oral hygiene measures to prevent periodontal disease include:

- Brushing properly on a regular basis (at least twice daily), with the patient attempting to direct the toothbrush bristles underneath the gum-line, to help disrupt the bacterial-mycotic growth and formation of subgingival plaque.
- Flossing daily and using interdental brushes (if there is a sufficiently large space between teeth), as well as cleaning behind the last tooth, the third molar, in each quarter.
- Using an antiseptic mouthwash. Chlorhexidine gluconate based mouthwash in combination with careful oral hygiene may cure gingivitis, although they cannot reverse any attachment loss due to periodontitis.
- Using a 'soft' tooth brush to prevent damage to tooth enamel and sensitive gums.
- Using periodontal trays to maintain dentist-prescribed medications at the source of the disease. The use of trays allows the medication to stay in place long enough to penetrate the biofilms where the microorganism are found.
- Regular dental check-ups and professional teeth cleaning as required. Dental check-ups serve to monitor the person's oral hygiene methods and levels of attachment around teeth, identify any early signs of periodontitis, and monitor response to treatment.

Typically dental hygienists (or dentists) use special instruments to clean (debride) teeth below the gumline and disrupt any plaque growing below the gumline. This is a standard treatment to prevent any further progress of established periodontitis. Studies show that after such a professional cleaning (periodontal debridement), microbic plaque tend to grow back to pre-cleaning levels after about 3–4 months. Hence, in theory, cleanings every 3–4 months might be expected to also prevent the initial onset of periodontitis. However, analysis of published research has reported little evidence either to support this or the intervals at which this should occur. Instead, it is advocated that the interval between dental check-ups should be determined specifically for each patient between every 3 to 24 months.

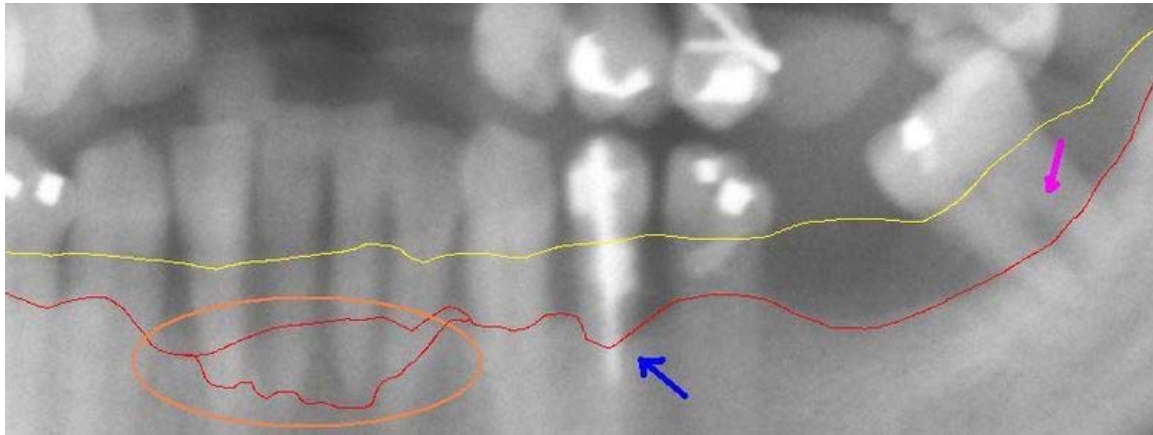
Nonetheless, the continued stabilization of a patient's periodontal state depends largely, if not primarily, on the patient's oral hygiene at home as well as on the go. Without daily

oral hygiene, periodontal disease will not be overcome, especially if the patient has a history of extensive periodontal disease.

Periodontal disease and tooth loss are associated with an increased risk of cancer.

A contributing cause may be low selenium in the diet: "Results showed that selenium has the strongest association with gum disease, with low levels increasing the risk by 13 fold."

Management



This section from a panoramic X-ray film depicts the teeth of the lower left quadrant, exhibiting generalized severe bone loss of 30–80%. The **red line** depicts the existing bone level, whereas the **yellow line** depicts where the gingiva was originally (1–2 mm above the bone), prior to the patient developing periodontal disease. The **pink arrow**, on the right, points to a *furcation involvement*, or the loss of enough bone to reveal the location at which the individual roots of a molar begin to branch from the single root trunk; this is a sign of advanced periodontal disease. The **blue arrow**, in the middle, shows up to 80% bone loss on tooth #21, and clinically, this tooth exhibited gross mobility. Finally, the **peach oval**, to the left, highlights the aggressive nature with which periodontal disease generally affects mandibular incisors. Because their roots are generally situated very close to each other, with minimal interproximal bone, and because of their location in the mouth, where plaque and calculus accumulation is greatest because of the pooling of saliva, mandibular anteriors suffer excessively. The **split in the red line** depicts varying densities of bone that contribute to a vague region of definitive bone height.

The cornerstone of successful periodontal treatment starts with establishing excellent oral hygiene. This includes twice daily brushing with daily flossing. Also the use of an interdental brush (called a Proxi-brush) is helpful if space between the teeth allows. For smaller spaces a product called "Soft Picks" are an excellent manual cleaning device. Persons with dexterity problems such as arthritis may find oral hygiene to be difficult and may require more frequent professional care and/or the use of a powered tooth brush. Persons with periodontitis must realize that it is a chronic inflammatory disease and a

lifelong regimen of excellent hygiene and professional maintenance care with a dentist/hygienist or periodontist is required to maintain affected teeth.

Initial therapy

Removal of microbic plaque and calculus is necessary to establish periodontal health. The first step in the treatment of periodontitis involves non-surgical cleaning below the gumline with a procedure called scaling and debridement. In the past, Root Planing was used (removal of cemental layer as well as calculus). This procedure involves use of specialized curettes to mechanically remove plaque and calculus from below the gumline, and may require multiple visits and local anesthesia to adequately complete. In addition to initial scaling and root planing, it may also be necessary to adjust the occlusion (bite) to prevent excessive force on teeth that have reduced bone support. Also it may be necessary to complete any other dental needs such as replacement of rough, plaque retentive restorations, closure of open contacts between teeth, and any other requirements diagnosed at the initial evaluation.

Reevaluation

Multiple clinical studies have shown that non-surgical scaling and root planing is usually successful if the periodontal pockets are shallower than 4–5 mm. It is necessary for the dentist or hygienist to perform a reevaluation 4–6 weeks after the initial scaling and root planing, to determine if the treatment was successful in reducing pocket depths and eliminating inflammation. Pocket depths which remain after initial therapy of greater than 5-6mm with bleeding upon probing are indicate continued active disease and will very likely show further bone loss over time. This is especially true in molar tooth sites where furcations (areas between the roots) have been exposed.

Surgery

If non-surgical therapy is found to have been unsuccessful in managing signs of disease activity, periodontal surgery may be needed to stop progressive bone loss and regenerate lost bone where possible. There are many surgical approaches used in treatment of advanced periodontitis, including open flap debridement, osseous surgery, as well as guided tissue regeneration and bone grafting. The goal of periodontal surgery is access for definitive calculus removal and surgical management of bony irregularities which have resulted from the disease process to reduce pockets as much as possible. Long-term studies have shown that in moderate to advanced periodontitis, surgically treated cases often have less further breakdown over time and when coupled with a regular post-treatment maintenance regimen are successful in nearly halting tooth loss in nearly 85% of patients.

Maintenance

Once successful periodontal treatment has been completed, with or without surgery, an ongoing regimen of "periodontal maintenance" is required. This involves regular

checkups and detailed cleanings every three months to prevent re-population of periodontitis-causing microorganism, and to closely monitor affected teeth so that early treatment can be rendered if disease recurs. Usually periodontal disease exist due to poor plaque control, therefore if the brushing techniques are not modified, a periodontal recurrence is probable.

Alternative treatments

Periodontitis has an inescapable relationship with subgingival calculus (tartar). The first step in any procedure is to eliminate calculus under the gum line, as it houses destructive anaerobic microorganisms that consume bone, gum and cementum (connective tissue) for food.

Most alternative “at-home” gum disease treatments involve injecting anti-microbial solutions, such as hydrogen peroxide, into periodontal pockets via slender applicators or oral irrigators. This process disrupts anaerobic microorganism colonies and is effective at reducing infections and inflammation when used daily. A number of potions and elixirs that are functionally equivalent to hydrogen peroxide are commercially available but at substantially higher cost. However, such treatments do not address calculus formations, and so are short-lived, as anaerobic microorganism colonies quickly regenerate in and around calculus.

In a new field of study, calculus formations are addressed on a more fundamental level. At the heart of the formation of subgingival calculus, growing plaque formations starve out the lowest members of the community, which calcify into calcium phosphate salts of the same shape and size of the original, organic bacilli. Calcium phosphate salts (unlike calcium phosphate; the primary component in teeth) are ionic and adhere to tooth surfaces via electrostatic attraction. Smaller, free-floating calcium phosphate salt particles are equally attracted to the same areas, as are additional calcified microorganism, growing calculus formations as unorganized, yet strong, “brick and mortar” matrices. The microscopic voids in calculus formations house new anaerobic microorganism, as does the top “diseased layer”.

Because the root cause of subgingival calculus development is ionic attraction, it was hypothesized that the introduction of oppositely charged particles around the formations may chelate calcium phosphate salt components away from the matrix, thus reducing the size of subgingival calculus formations. To accomplish this, a sequestering agent solution consisting partly of sodium tripolyphosphate (STPP) and sodium fluoride (charge -1) was tested on a patient with burnished and new subgingival calculus at a depth of 6 mm. The patient delivered the solution using an oral irrigator, once a day, for 60 days. The results were the successful elimination of all calculus formations studied. This test was conducted using a subgingival endoscopic camera (perioscope) by an independent periodontist.

The promise of this new, alternative treatment is to keep subgingival calculus at bay, in concert with traditional periodontal treatments. In this way, periodontitis may be

controlled by the patient, and complete restoration of dental health can be a collaborative effort between the patient and the dental professional.

Additionally, Periodontitis can be treated in a noninvasive manner by means of Periostat (subantimicrobial dose of doxycycline), an FDA-approved, orally-administered drug that has been shown to reduce bone loss. Its mechanism of action in part involves inhibition of Matrix metalloproteinases (such as collagenase), which degrade the extracellular matrix under inflammatory conditions. This ultimately can lead to reduction of alveolar bone-loss in patients with periodontal disease (as well as patients without periodontitis).

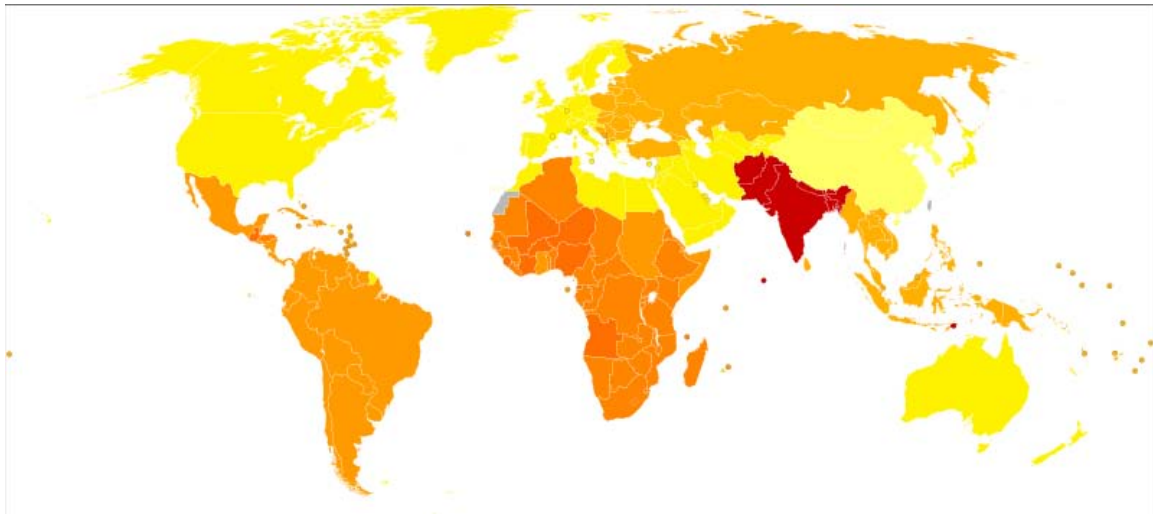
Prognosis

Dentists and dental hygienists measure periodontal disease using a device called a periodontal probe. This is a thin "measuring stick" that is gently placed into the space between the gums and the teeth, and slipped below the gum-line. If the probe can slip more than 3 millimeters below the gum-line, the patient is said to have a gingival pocket if no migration of the epithelial attachment has occurred or a periodontal pocket if apical migration has occurred. This is somewhat of a misnomer, as any depth is in essence a pocket, which in turn is defined by its depth, i.e., a 2 mm pocket or a 6 mm pocket. However, it is generally accepted that pockets are self-cleansable (at home, by the patient, with a toothbrush) if they are 3 mm or less in depth. This is important because if there is a pocket which is deeper than 3 mm around the tooth, at-home care will not be sufficient to cleanse the pocket, and professional care should be sought. When the pocket depths reach 6 and 7 mm in depth, the hand instruments and cavitrons used by the dental professionals may not reach deeply enough into the pocket to clean out the microbial plaque that cause gingival inflammation. In such a situation the bone or the gums around that tooth should be surgically altered or it will always have inflammation which will likely result in more bone loss around that tooth. An additional way to stop the inflammation would be for the patient to receive subgingival antibiotics (such as minocycline) or undergo some form of gingival surgery to access the depths of the pockets and perhaps even change the pocket depths so that they become 3 mm or less in depth and can once again be properly cleaned by the patient at home with his or her toothbrush.


If a patient has 7 mm or deeper pockets around their teeth, then they would likely risk eventual tooth loss over the years. If this periodontal condition is not identified and the patient remains unaware of the progressive nature of the disease then, years later, they may be surprised that some teeth will gradually become loose and may need to be extracted, sometimes due to a severe infection or even pain.

According to the Sri Lankan tea labourer study, in the absence of any oral hygiene activity, approximately 10% will suffer from severe periodontal disease with rapid loss of attachment (>2 mm/year). 80% will suffer from moderate loss (1–2 mm/year) and the remaining 10% will not suffer any loss.

Epidemiology



Disability-adjusted life year for periodontal disease per 100,000 inhabitants in 2004.



Periodontitis is very common, and is widely regarded as the second most common disease worldwide, after dental decay, and in the United States has a prevalence of 30–50% of the population, but only about 10% have severe forms.

Like other conditions that are intimately related to access to hygiene and basic medical monitoring and care, periodontitis tends to be more common in economically disadvantaged populations or regions. Its occurrence decreases with higher standard of living. In Israeli population, individuals of Yemenite, North-African, South Asian, or Mediterranean origin have higher prevalence of periodontal disease than individuals from European descent.

Presumably, individuals living in East Asia (e.g. Japan, South Korea and Taiwan) have the lowest incident of periodontal disease in the world.

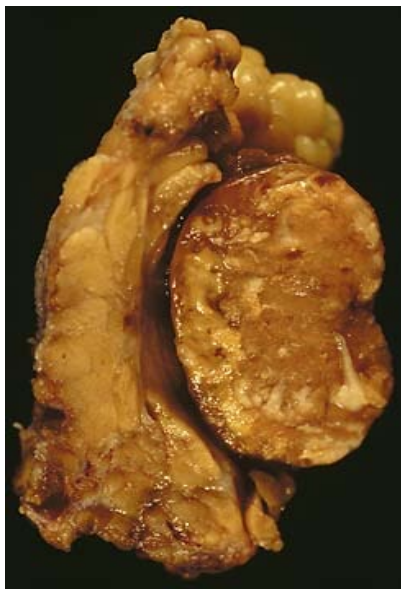
In other animals

Periodontal disease is the most common disease found in dogs and affects more than 80% of dogs aged three years or older. The prevalence of periodontal disease in dogs increases with age but decreases with increasing body weight; i.e., toy and miniature breeds are more severely affected. Systemic disease may develop because the gums are very vascular (have a good blood supply). The blood stream carries these anaerobic microorganisms, and they are filtered out by the kidneys and liver, where they may colonize and create microabscesses. The microorganisms traveling through the blood may also attach to the heart valves, causing vegetative endocarditis (infected heart valves). Additional diseases that may result from periodontitis includes chronic bronchitis and pulmonary fibrosis.

Chapter 10

Warthin's Tumor

Warthin's tumor



This Warthin's tumor presented as a parotid mass in a middle-aged male, who underwent superficial parotidectomy. The tumor, at the right of the image, is well-demarcated from the adjacent parotid tissue and tends to shell out from it.

ICD-10 D11.

ICD-9 210.2

ICD-O: 8561/0

DiseasesDB 31941

eMedicine plastic/371

MeSH D000235

Warthin's tumor or **Warthin tumour**, also known as **papillary cystadenoma lymphomatosum** or adenolymphoma, is a type of benign tumor of the salivary glands.

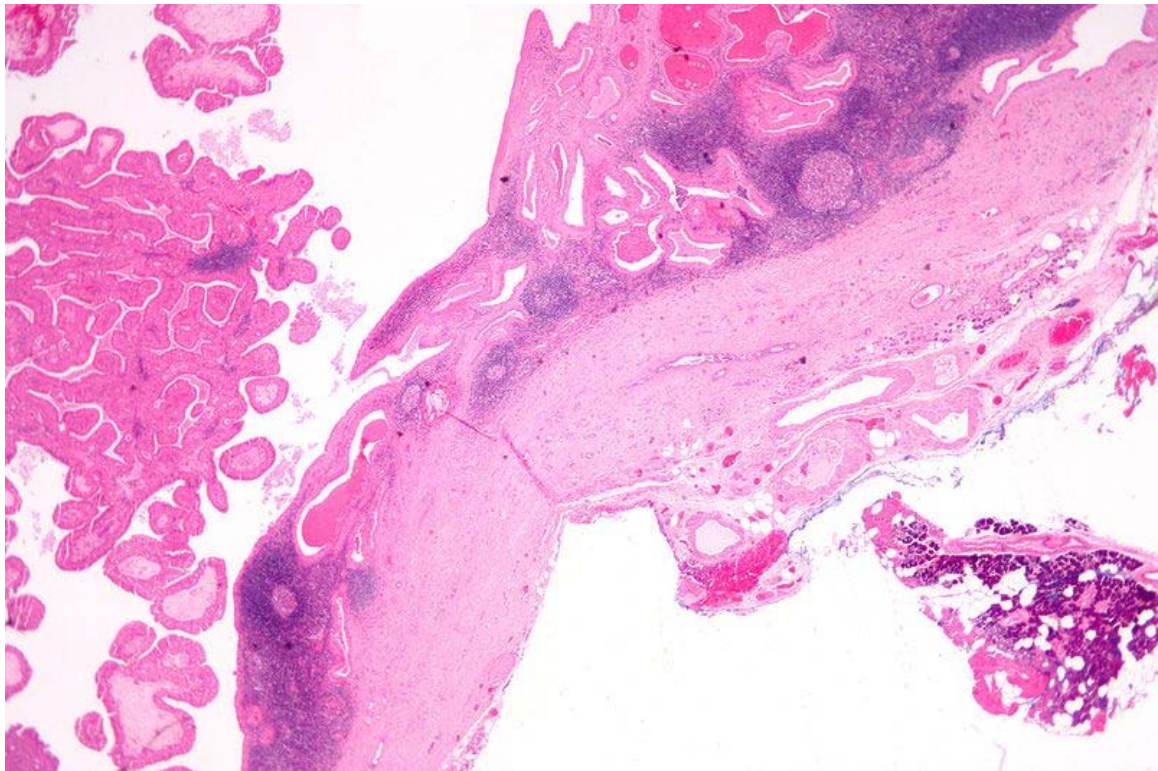
Etiology

Its etiology is unknown, but there is a strong association with cigarette smoking. Smokers are at 8 times greater risk of developing Warthin's tumor than the general population.

Locations

The gland most likely affected is the parotid gland. Though much less likely to occur than pleomorphic adenoma, Warthin's tumor is the second most common benign parotid tumor.

Characteristic



Low magnification micrograph of a **Warthin tumor** arising from the parotid gland

Warthin's tumor primarily affects older individuals (age 60–70 years). There is a slight female predilection according to recent studies, but historically it has been associated with a strong male predilection. This change is possibly due to the tumor's association with cigarette smoking and the growing use of cigarettes by women. The tumor is slow growing, painless, and usually appears in the tail of the parotid gland near the angle of the mandible. In 5–14% of cases, Warthin's tumor is bilateral, but the two masses usually are at different times. Warthin's tumor is highly unlikely to become malignant.

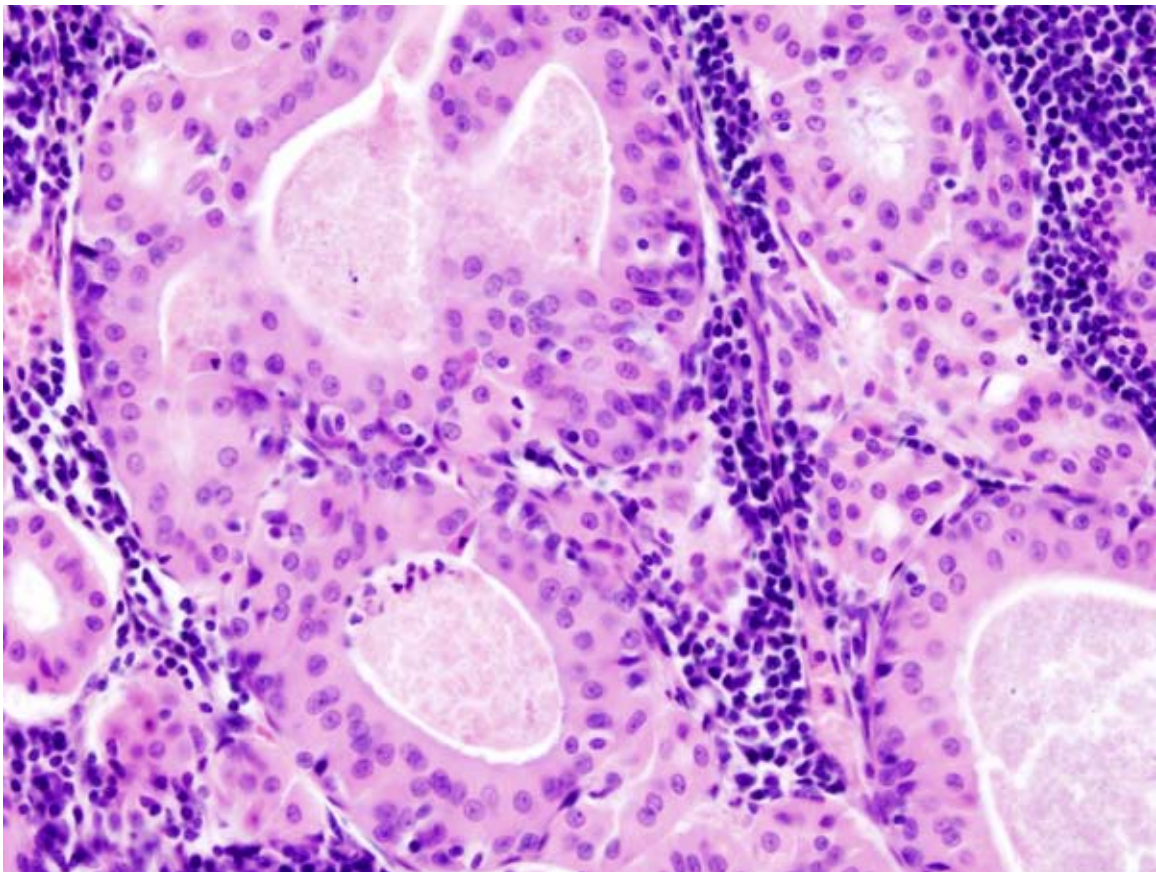
Histology

The appearance of this tumor under the microscope is unique. There are cystic spaces surrounded by two uniform rows of cells with centrally placed pyknotic nuclei. The cystic spaces have epithelium referred to as papillary infoldings that protrude into them. Additionally, the epithelium has lymphoid stroma with germinal center formation.

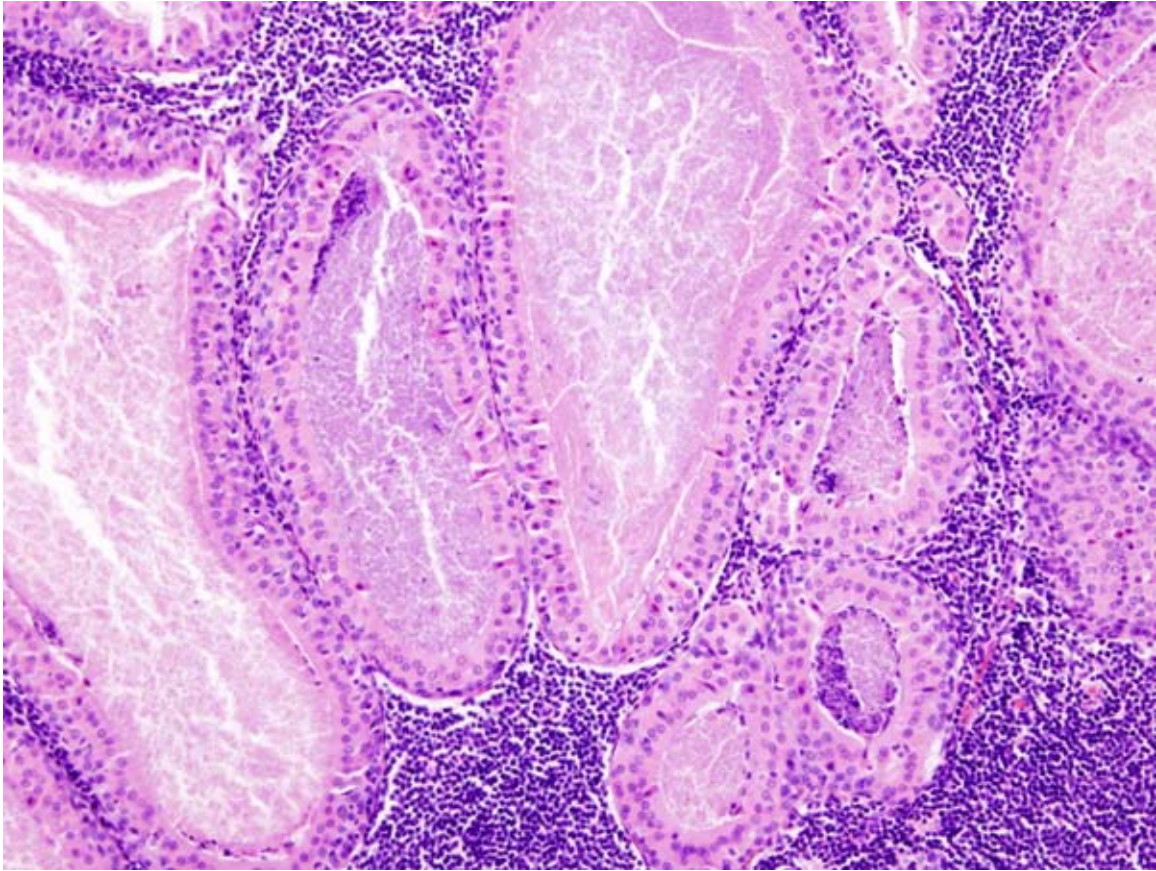
Treatment

Most of these tumors are treated with surgical removal. Recurrence is rare, occurring in 6–12% of cases.

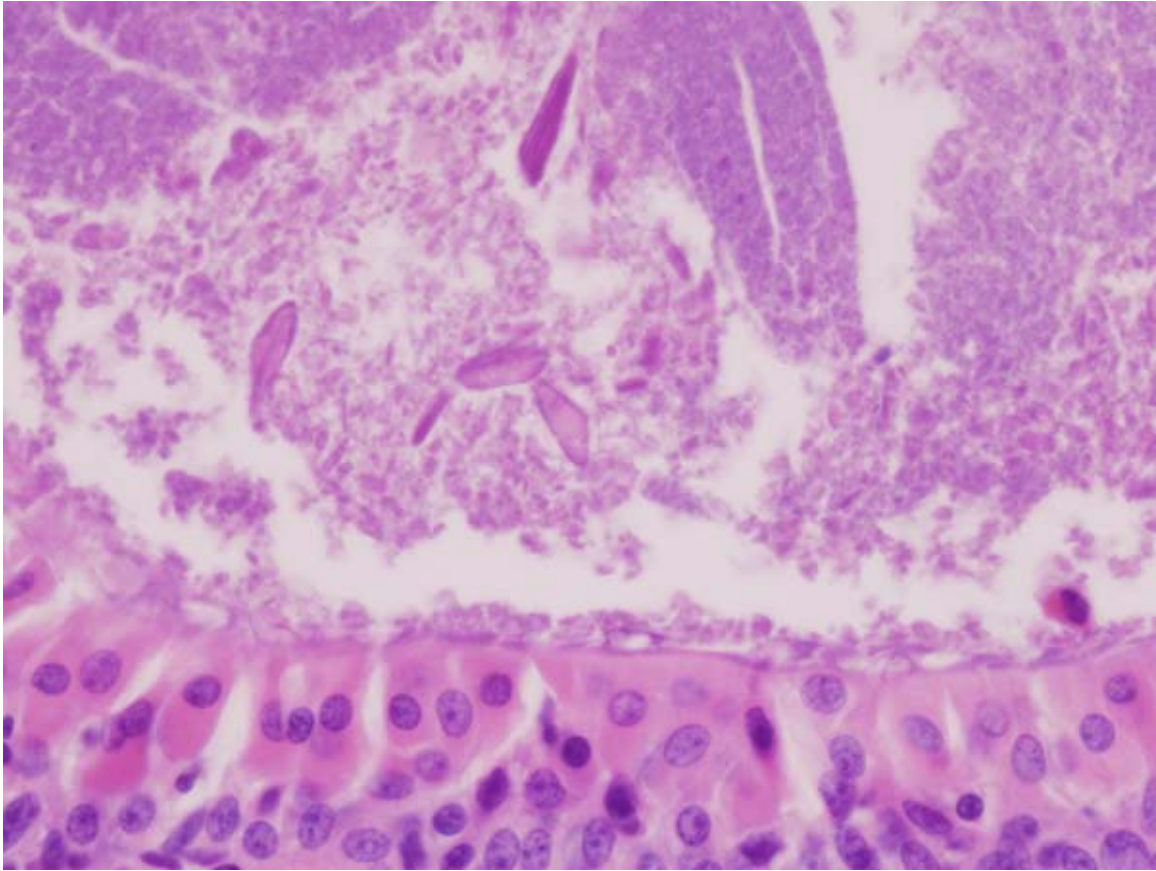
Additional images



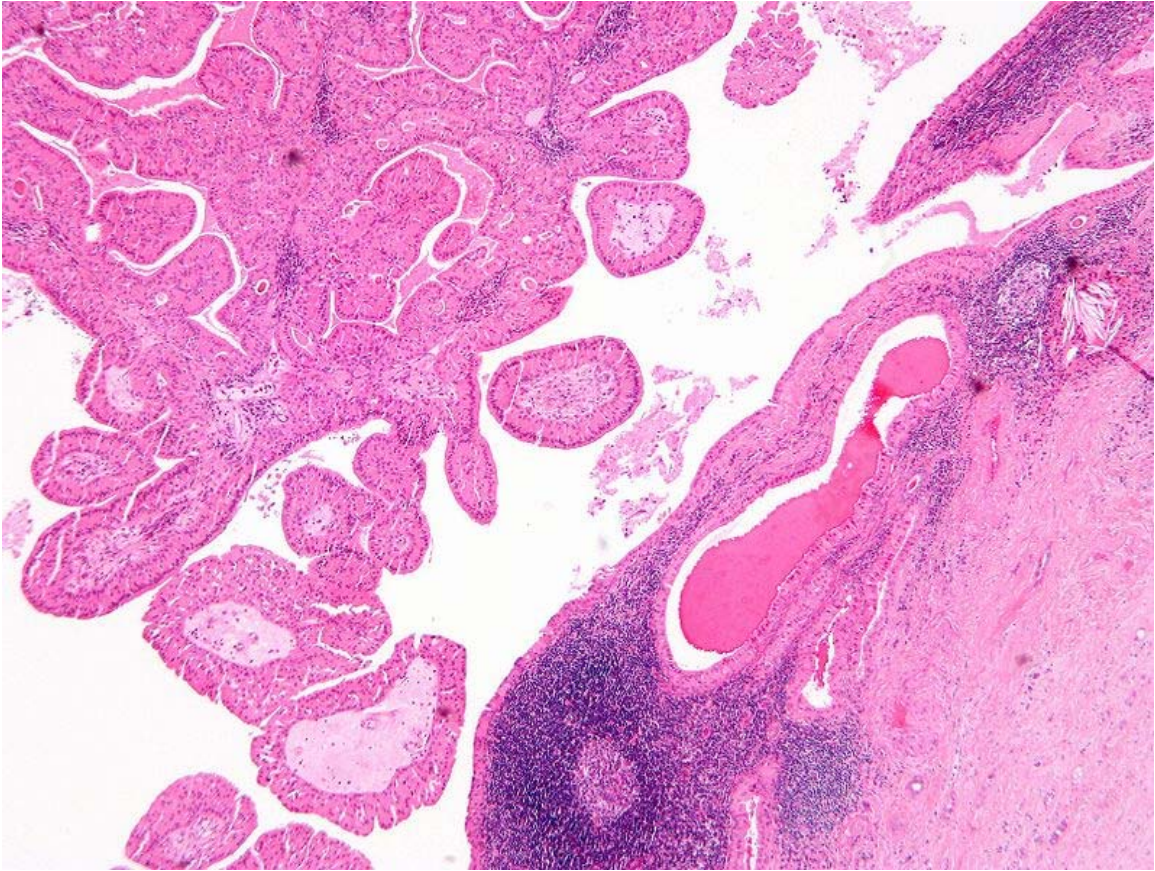
Histopathology of Warthin tumor in the parotid gland. H&E stain.



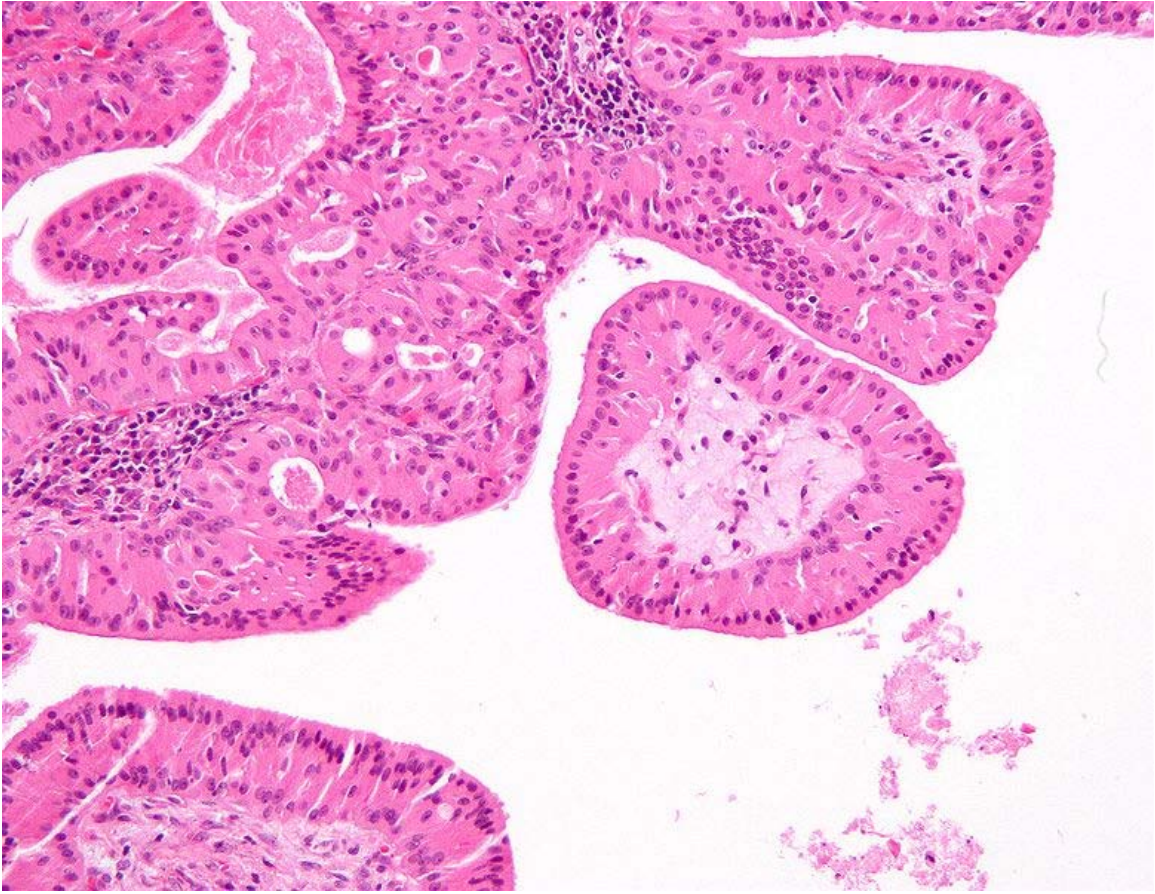
Histopathology of Warthin tumor in the parotid gland. Another view of a file H&E stain.



Histopathology of Warthin tumor in the parotid gland. Higher magnification of a file.
H&E stain.



Intermediate magnification micrograph of a **Warthin tumor**

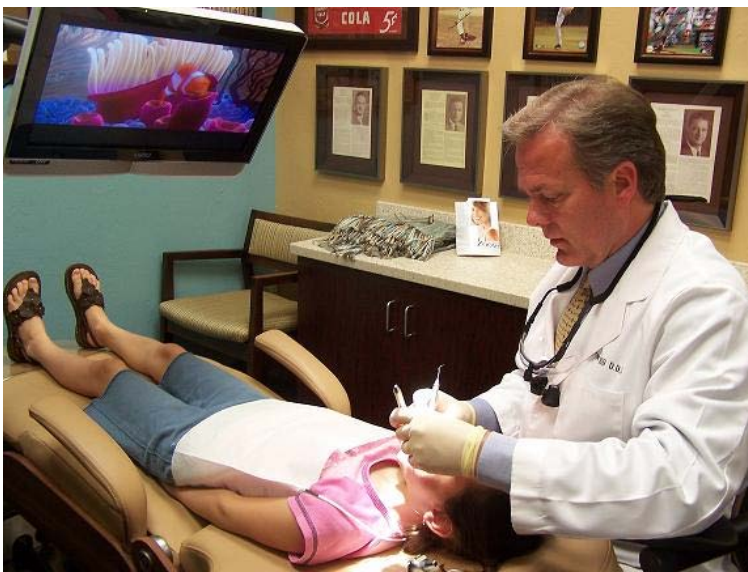

High magnification micrograph of a **Warthin tumor** showing the characteristic bilayered epithelium.

Chapter 11

Dentistry

Dentist



A dentist treating a patient.

Occupation

Activity sectors

Medicine

Description

Education required

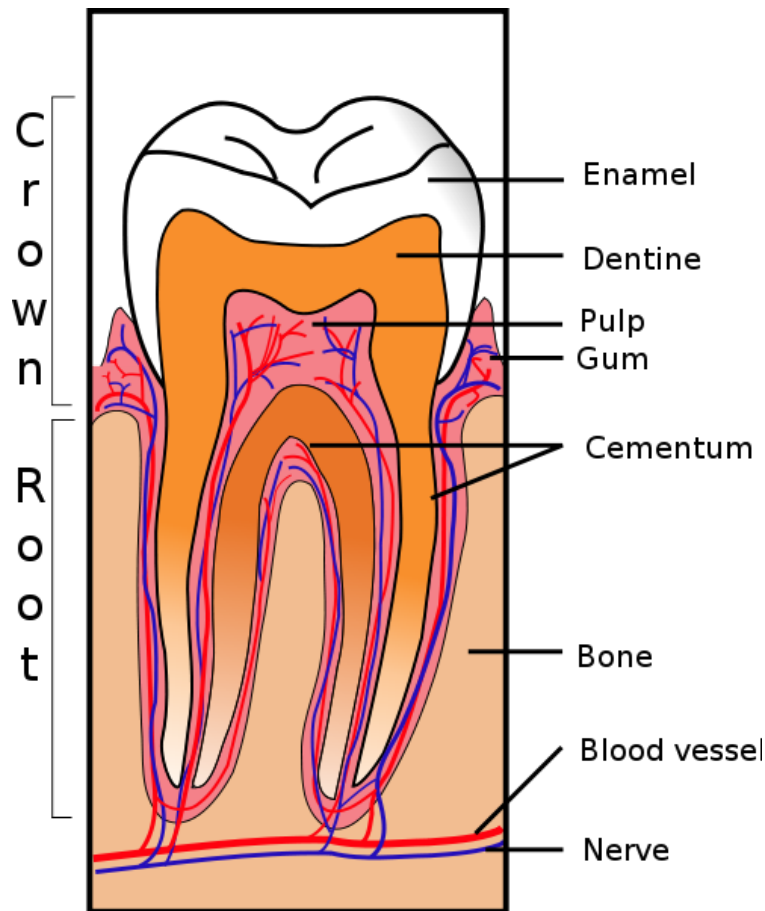
Dental degree

Fields of employment

Hospitals, Private Practices

Dentistry is the branch of medicine that is involved in the study, diagnosis, prevention, and treatment of diseases, disorders and conditions of the oral cavity, maxillofacial area and the adjacent and associated structures and their impact on the human body. Dentistry is widely considered necessary for complete overall health. Those who practice dentistry are known as dentists. The dentist's supporting team aids in providing oral health services, which includes dental assistants, dental hygienists, dental technicians, and dental therapists.

Overview



Sagittal section of a tooth

Dental surgery and treatments

Dentistry usually encompasses very important practices related to the oral cavity. Oral diseases are major public health problems due to their high incidence and prevalence across the globe with the disadvantaged affected more than other socio-economic groups.

Although modern day dental practice centres around prevention, many treatments or interventions are still needed. The majority of dental treatments are carried out to prevent or treat the two most common oral diseases which are dental caries (tooth decay) and periodontal disease (gum disease or pyorrhea). Common treatments involve the restoration of teeth as a treatment for dental caries (fillings), extraction or surgical removal of teeth which cannot be restored, scaling of teeth to treat periodontal problems and endodontic root canal treatment to treat abscessed teeth.

All dentists train for around 4 or 5 years at University and qualify as a 'dental surgeon'. By nature of their general training they can carry out the majority of dental treatments such as restorative (fillings, crowns, bridges), prosthetic (dentures), endodontic (root

canal) therapy, periodontal (gum) therapy, and exodontia (extraction of teeth), as well as performing examinations, radiographs (x-rays) and diagnosis. Dentists can also prescribe certain medications such as antibiotics, fluorides, and sedatives but they are not able to prescribe the full range that physicians can.

Dentists need to take additional qualifications or training to carry out more complex treatments such as sedation, oral and maxillofacial surgery, and implants. Whilst the majority of oral diseases are unique and self limiting, some can indicate poor general health, tumours, blood dyscrasias and abnormalities including genetic problems.

Prevention

Dentists also encourage prevention of dental caries through proper hygiene (tooth brushing and flossing), fluoride, and tooth polishing. Dental sealants are plastic materials applied to one or more teeth, for the intended purpose of preventing dental caries (cavities) or other forms of tooth decay. Recognized but less conventional preventive agents include xylitol, which is bacteriostatic, casein derivatives, and proprietary products such as Cavistat BasicMints.

Education and licensing



Early dental chair in Pioneer West Museum in Shamrock, Texas

The first dental school, Baltimore College of Dental Surgery, opened in Baltimore, Maryland, USA in 1840. Philadelphia Dental College was founded in 1863 and is the second in the United States. In 1907 Temple University accepted a bid to incorporate the school.

Studies showed that dentists graduated from different countries, or even from different dental schools in one country, may have different clinical decisions for the same clinical condition. For example, dentists graduated from Israeli dental schools may recommend more often for the removal of asymptomatic impacted third molar (wisdom teeth) than dentists graduated from Latin American or Eastern European dental schools.


In the United Kingdom of Great Britain and Ireland, the 1878 British Dentists Act and 1879 Dentists Register limited the title of "dentist" and "dental surgeon" to qualified and registered practitioners. However, others could legally describe themselves as "dental experts" or "dental consultants". The practice of dentistry in the United Kingdom became fully regulated with the 1921 Dentists Act, which required the registration of anyone practicing dentistry. The British Dental Association, formed in 1880 with Sir John Tomes as president, played a major role in prosecuting dentists practising illegally.

In Korea, Taiwan, Japan, Sweden, Germany, the United States, and Canada, a dentist is a healthcare professional qualified to practice dentistry after graduating with a degree of either Doctor of Dental Surgery (DDS) or Doctor of Dental Medicine (DMD). This is equivalent to the Bachelor of Dental Surgery/Baccalaureus Dentalis Chirurgiae (BDS, BDent, BChD, BDS_c) that is awarded in the UK and British Commonwealth countries. In most western countries, to become a qualified dentist one must usually complete at least four years of postgraduate study; within the European Union the education has to be at least five years. Dentists usually complete between five and eight years of post-secondary education before practising. Though not mandatory, many dentists choose to complete an internship or residency focusing on specific aspects of dental care after they have received their dental degree.

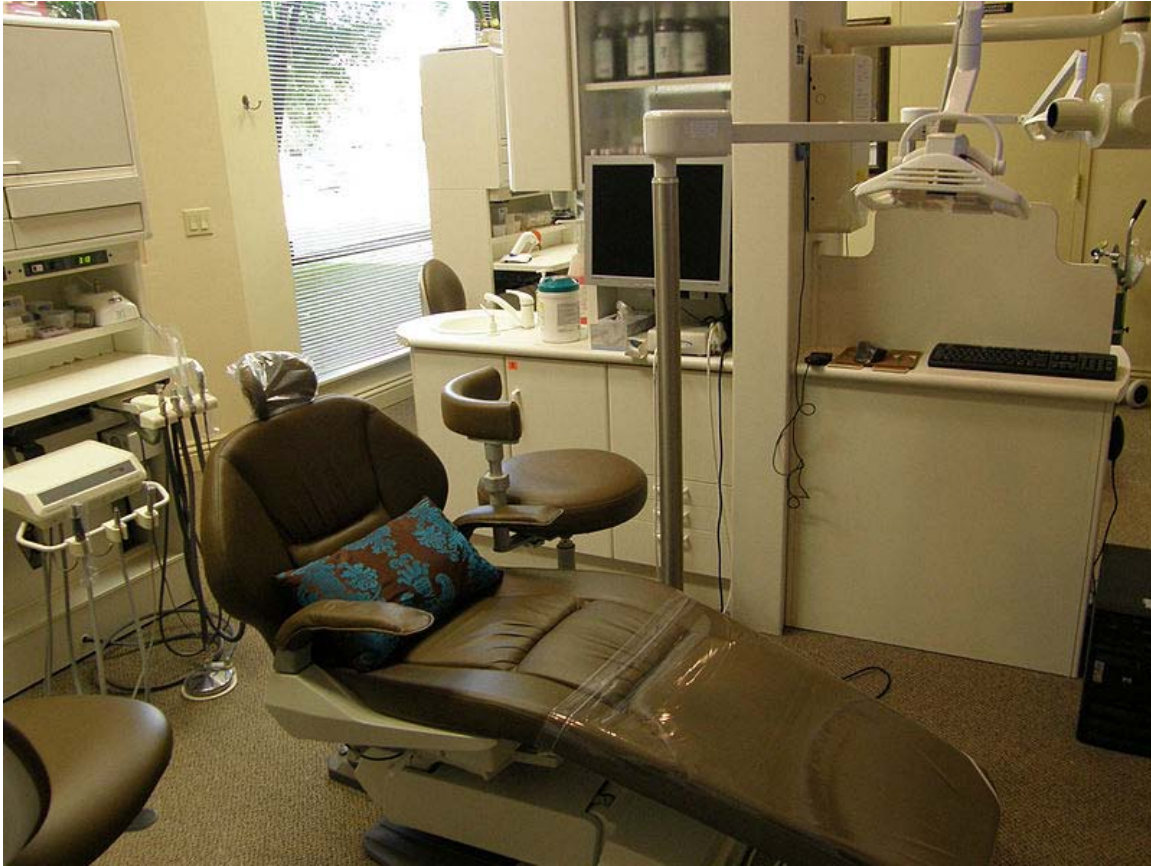Specialties

The American Dental Association recognizes nine dental specialties: Public Health Dentistry, Endodontics, Oral & Maxillofacial Pathology, Oral & Maxillofacial Radiology, Oral & Maxillofacial Surgery (Oral Surgeon), Orthodontics, Pediatric Dentistry, Periodontics, Prosthodontics, and General Dentistry.

History



Farmer at the dentist, Johann Liss, c. 1616-17



A modern Dentist's chair

The Indus Valley Civilization has yielded evidence of dentistry being practiced as far back as 7000 BC. This earliest form of dentistry involved curing tooth related disorders with bow drills operated, perhaps, by skilled bead craftsmen. The reconstruction of this ancient form of dentistry showed that the methods used were reliable and effective.

A Sumerian text from 5000 BC describes a "tooth worm" as the cause of dental caries. Evidence of this belief has also been found in ancient India, Egypt, Japan, and China. The legend of the worm is also found in the writings of Homer, and as late as the 14th century AD the surgeon Guy de Chauliac still promoted the belief that worms cause tooth decay.

The Edwin Smith Papyrus, written in the 17th century BC but which may reflect previous manuscripts from as early as 3000 BC, includes the treatment of several dental ailments. In the 18th century BC, the Code of Hammurabi referenced dental extraction twice as it related to punishment. Examination of the remains of some ancient Egyptians and Greco-Romans reveals early attempts at dental prosthetics and surgery.

Ancient Greek scholars Hippocrates and Aristotle wrote about dentistry, including the eruption pattern of teeth, treating decayed teeth and gum disease, extracting teeth with forceps, and using wires to stabilize loose teeth and fractured jaws. Some say the first use of dental appliances or bridges comes from the Etruscans from as early as 700 BC.

Further research suggested that 3000 B.C. In ancient Egypt, Hesi-Re is the first named “dentist” (greatest of the teeth). The Egyptians bind replacement teeth together with gold wire. Roman medical writer Cornelius Celsus wrote extensively of oral diseases as well as dental treatments such as narcotic-containing emollients and astringents.

Historically, dental extractions have been used to treat a variety of illnesses. During the Middle Ages and throughout the 19th century, dentistry was not a profession in itself, and often dental procedures were performed by barbers or general physicians. Barbers usually limited their practice to extracting teeth which alleviated pain and associated chronic tooth infection. Instruments used for dental extractions date back several centuries. In the 14th century, Guy de Chauliac invented the dental pelican (resembling a pelican's beak) which was used up until the late 18th century. The pelican was replaced by the dental key which, in turn, was replaced by modern forceps in the 20th century.

The first book focused solely on dentistry was the "Artzney Buchlein" in 1530, and the first dental textbook written in English was called "Operator for the Teeth" by Charles Allen in 1685. It was between 1650 and 1800 that the science of modern dentistry developed. It is said that the 17th century French physician Pierre Fauchard started dentistry science as we know it today, and he has been named "*the father of modern dentistry*". Among many of his developments were the extensive use of dental prosthesis, the introduction of dental fillings as a treatment for dental caries and the statement that sugar derivative acids such as tartaric acid are responsible for dental decay.

There has been a problem of quackery in the history of dentistry, and accusations of quackery among some dental practitioners persist today.

Priority patients

UK NHS priority patients include patients with congenital abnormalities (such as cleft palates and hypodontia), patients who have suffered orofacial trauma and those being treated for cancer in the head and neck region. These are treated in a multidisciplinary team approach with other hospital based dental specialities orthodontics and maxillofacial surgery. Other priority patients include those with infections (either third molars or necrotic teeth which can often infect the brain) or avulsed permanent teeth, as well as patients with a history of smoking or smokeless tobacco with ulcers in the oral cavity also.

Chapter 12

Crown (Dentistry)



A **porcelain-fused-to-metal crown** for tooth #29 on its stone model. It is now ready to be cemented into the patient's mouth. The prosthetic crown does not extend distally to tooth #31 (molar to the left in photo) because the span is too large, as tooth #30 is missing. This edentulous area, together with a much larger one across the arch in the area of teeth #18-21, will be restored with a removable partial denture.



The stone model die for the same PFM crown on tooth #29. Notice how much tooth structure has been removed in order to facilitate placement of a crown. The original dimensions of the tooth approach if not duplicate the contours of the restoration in the photo above. The silvery paint on the stone die of tooth #29 is a **die spacer**, placed to allow for a minute amount of space between the tooth structure and the internal surface of the crown, which will later fill with cement upon final insertion of the crown into the mouth.

A **crown** is a type of dental restoration which completely caps or encircles a tooth or dental implant. Crowns are often needed when a large cavity threatens the ongoing health of a tooth. They are typically bonded to the tooth using a dental cement. Crowns can be made from many materials, which are usually fabricated using *indirect methods*. Crowns are often used to improve the strength or appearance of teeth. While unarguably beneficial to dental health, the procedure and materials can be relatively expensive.

The most common method of crowning a tooth involves using a dental impression of a prepared tooth by a dentist to fabricate the crown outside of the mouth. The crown can then be inserted at a subsequent dental appointment. Using this *indirect method* of tooth restoration allows use of strong restorative materials requiring time consuming fabrication methods requiring intense heat, such as casting metal or firing porcelain which would not be possible to complete inside the mouth. Because of the expansion properties, the relatively similar material costs, and the aesthetic benefits, many patients choose to have their crown fabricated with gold.

As new technology and materials science has evolved, computers are increasingly becoming a part of crown and bridge fabrication, such as in CAD/CAM Dentistry.

Other reasons to restore with a crown

There are additional situations in which a crown would be the restoration of choice.

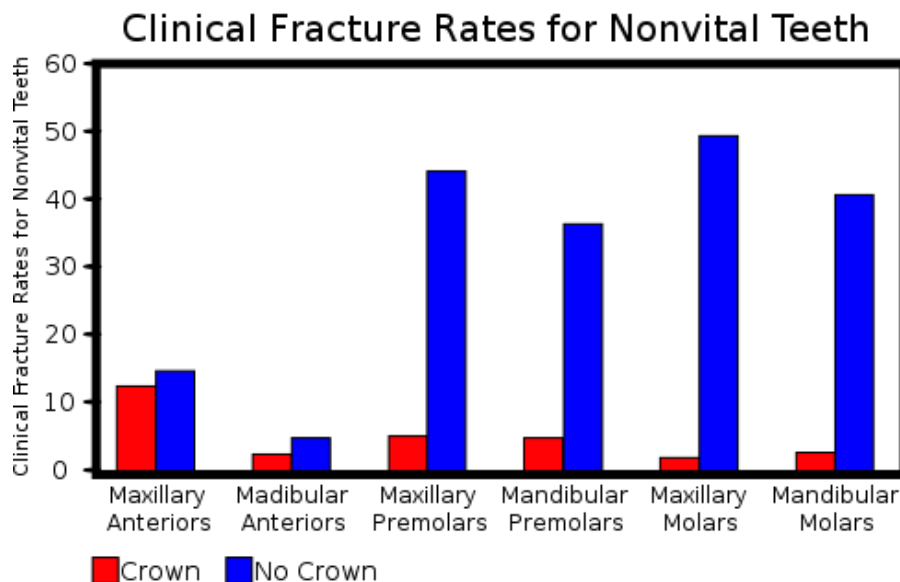
Implants

Dental implants are placed into either the maxilla or mandible as an alternative to partial or complete edentulism. Once placed and properly integrated into the bone, implants may then be fitted with a number of different prostheses:

- crowns or bridges
- precision attachments for either removable partial dentures, complete dentures or a hybrid sort of prosthetic appliance.

Endodontically treated teeth

When teeth undergo endodontic treatment, or root canal therapy, they are devitalized when the nerve and blood supply are cut off and the space which they previously filled, known as the "pulp chamber" and "root canal", are thoroughly cleansed and filled with various materials to prevent future invasion by bacteria. Although there may very well be enough tooth structure remaining after root canal therapy is provided for a particular tooth to restore the tooth with an intracoronal restoration, this is not suggested in most teeth. The vitality of a tooth is remarkable in its ability to provide the tooth with the strength and durability it needs to function in mastication. The living tooth structure is surprisingly resilient and can sustain considerable abuse without fracturing. Consequently, after root canal therapy is performed, a tooth becomes extremely brittle and is significantly weaker than its vital neighbors.



Fractures of endodontically treated teeth increase considerably in the posterior dentition when cuspal protection is not provided by a crown.

The average person can exert 150-200 lbs. of muscular force on their posterior teeth, which is approximately nine times the amount of force that can be exerted in the anterior. If the effective posterior contact area on a restoration is 0.1 mm², over 1 million PSI of stress is placed on the restoration. Therefore, posterior teeth (i.e. molars and premolars) should in almost all situations be crowned after undergoing root canal therapy to provide for proper protection against fracture (mandibular premolars, being very similar in crown morphology to canines, may in some cases be protected with intracoronal restorations). Should an endodontically treated tooth not be properly protected, there is a chance of it succumbing to breakage from normal functional forces. This fracture may well be difficult to treat, such as a "vertical root fracture". Anterior teeth (i.e. incisors and canines), which are exposed to significantly lower functional forces, may effectively be treated with intracoronal restorations following root canal therapy if there is enough tooth structure remaining after the procedure.

Surveyed crown

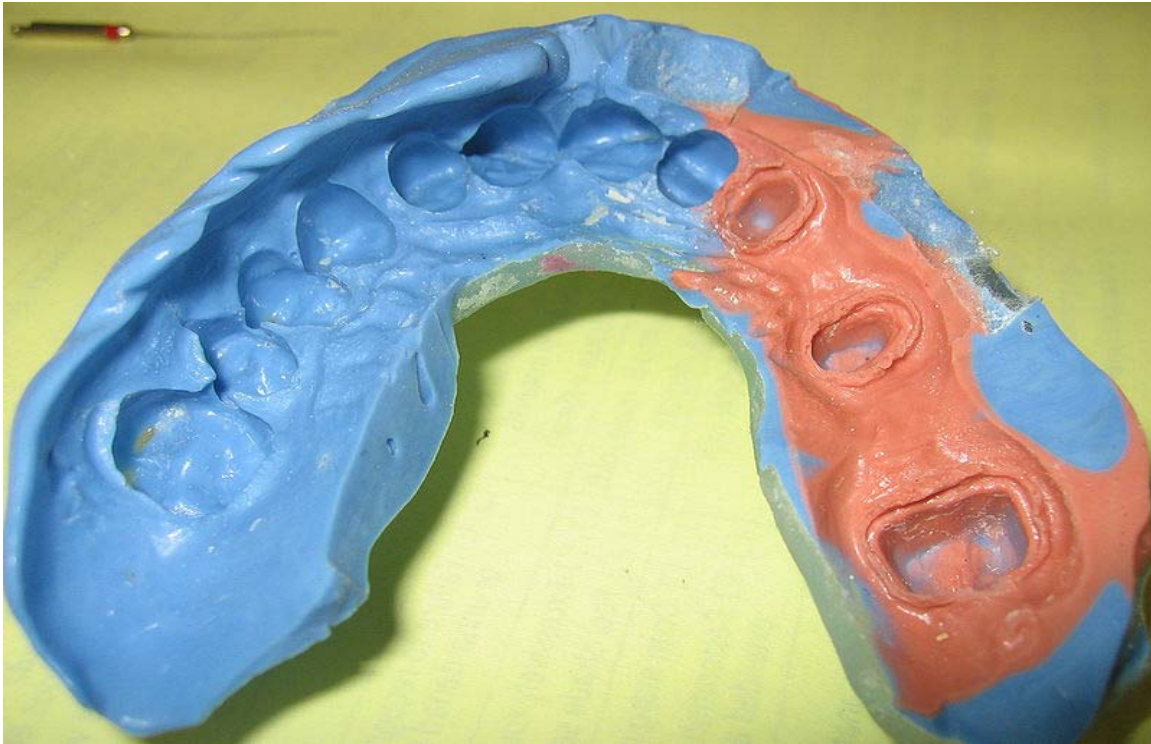Another situation in which a crown is the restoration of choice is when a tooth is intended as an abutment tooth for a removable partial denture, but is initially unfavorable for such a task. If the abutment teeth onto which the RPD is supposed to clasp do not possess the proper dimensions or features required, these aspects can be built into what is known as a **surveyed crown**.

Aesthetics

A fourth situation in which a crown would be the restoration of choice is when a patient desires to have his or her smile aesthetically improved but when **partial coverage** (i.e., a veneer/laminate) is not an option for one or more reasons. If the patient's occlusion does not permit for a mildly-retentive restoration, or if there is too much decay or a fracture within the tooth structure, a porcelain or composite veneer may not be placed with any adequate guarantee for its durability. Similarly, a "bruxer" (someone who clenches or grinds their teeth) may produce enough force to repeatedly dislodge or irreversibly abrade any veneer a dentist can plan for. In such a case, **full coverage** crowns can alter the size, shape or shade of a patient's teeth while protecting against failure of the restoration.

Makeover shows such as *Extreme Makeover* make extensive use of crowns, as the time-frame of the makeover is too short to allow up to 18 months for orthodontic treatment for problems that might otherwise be corrected more conservatively.

Tooth preparation



A full-arch vinyl polysiloxane impression of the teeth prepared for the 5-unit PFM bridge shown in the photographs below. The salmon-colored impression material used near the crown preparations is of a lower viscosity than the blue, allowing for the capture of greater detail.

Preparation of a tooth for a crown involves the irreversible removal of a significant amount of tooth structure. All restorations possess compromised structural and functional integrity when compared to healthy, natural tooth structure. Thus, if not indicated as desirable by an oral health-care professional, the crowning of a tooth would most likely be contraindicated. It should be evident, though, that dentists trained at different institutions in different eras and in different countries might very well possess different methods of treatment planning and case selection, resulting in somewhat diverse recommendations for treatment.

Traditionally more than one visit is required to complete crown and bridge work, and the additional time required for the procedure can be a disadvantage; the increased benefits of such a restoration, however, will generally offset these considerations.

Dimensions of preparation

When preparing a tooth for a traditional crown, the enamel may be totally removed and the finished preparation should, thus, exist primarily in dentin. As elaborated on below, the amount of tooth structure required to be removed will depend on the material(s) being used to restore the tooth. If the tooth is to be restored with a full gold crown, the

restoration need only be .5 mm in thickness (as gold is very strong), and therefore, a minimum of only .5 mm of space needs to be made for the crown to be placed. If porcelain is to be applied to the gold crown, an additional minimum of 1 mm of tooth structure needs to be removed to allow for a sufficient thickness of the porcelain to be applied, thus bringing the total tooth reduction to minimally 1.5 mm.

If there is not enough tooth structure to properly retain the traditional prosthetic crown, the tooth requires a build-up material. This can be accomplished with a pin-retained direct restoration, such as amalgam or a composite resin, or in more severe cases, may require a post and core. Should the tooth require a post and core, endodontic therapy would then be indicated, as the post descends into the devitalized root canal for added retention. If the tooth, because of its relative lack of exposed tooth structure, also requires crown lengthening, the total combined time, effort and cost of the various procedures, together with the decreased prognosis because of the combined inherent failure rates of each procedure, might make it more reasonable to have the tooth extracted and opt to have an implant placed.

In recent years, the technological advances afforded by CAD/CAM Dentistry offer viable alternatives to the traditional crown restoration in many cases. Where the traditional indirectly fabricated crown requires a tremendous amount of surface area to retain the normal crown, potentially resulting in the loss of healthy, natural tooth structure for this purpose, the all-porcelain CAD/CAM crown can be predictably used with significantly less surface area. As a matter of fact, the more enamel that is retained, the greater the likelihood of a successful outcome. As long as the thickness of porcelain on the top, chewing portion of the crown is 1.5mm thick or greater, the restoration can be expected to be successful. The side walls which are normally totally sacrificed in the traditional crown are generally left far more intact with the CAD/CAM option. In regards to post & core buildups, these are generally contraindicated in CAD/CAM crowns as the resin bonding materials do best bonding the etched porcelain interface to the etched enamel/dentin interfaces of the natural tooth itself. The crownlay is also an excellent alternative to the post & core buildup when restoring a root canal treated tooth.

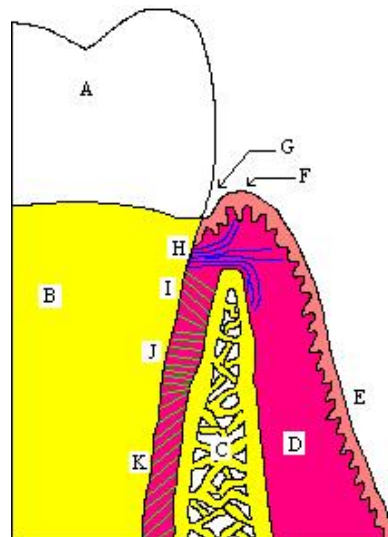
Taper

The prepared tooth also needs to possess 3 to 5 degrees of taper to allow for the restoration to be properly placed on the tooth. The taper should not exceed 20 degrees. Fundamentally, there can be no undercuts on the surface of the prepared tooth, as the restoration will not be able to be removed from the die, let alone fit on the tooth. At the same time, too much taper will severely limit the grip that the crown has on the prepared tooth, thus contributing to failure of the restoration. Generally, 6° of taper around the entire circumference of the prepared tooth, giving a combined taper of 12° at any given sagittal section through the prepared tooth, is appropriate to both allow the crown to fit yet provide enough grip.

Margin

The most coronal position of untouched tooth structure (that is, the continual line of original, undrilled tooth structure at or near the gum line) is referred to as the **margin**. This margin will be the future continual line of tooth-to-restoration contact, and should be a smooth, well-defined delineation so that the restoration, no matter how it is fabricated, can be properly adapted and not allow for any openings visible to the naked eye, however slight. An acceptable distance from tooth margin to restoration margin is anywhere from 40-100 μm . However, the R.V. Tucker method of gold inlay and onlay restoration produces tooth-to-restoration adaptation of potentially only 2 μm , confirmed by scanning electron microscopy; this is less than the diameter of a single bacterium.

Naturally, the tooth-to-restoration margin is an unsightly thing to have exposed on the visible surface of a tooth when the tooth exists in the aesthetic zone of the smile. In these areas, the dentist would like to place the margin as far apical (towards the root tip of the tooth) as possible, even below the gum line. While there is no issue, per se, with placing the margin at the gumline, problems may arise when placing the margin too subgingivally (below the gumline). First, there might be issues in terms of capturing the margin in an impression to make the stone model of the prepared tooth. Secondly, there is the seriously important issue of biologic width. Biologic width is the mandatory distance to be left between the height of the alveolar bone and the margin of the restoration, and if this distance is violated because the margin is placed too subgingivally, serious repercussions may follow. In situations where the margin cannot be placed apically enough to provide for proper retention of the prosthetic crown on the prepared tooth structure, the tooth or teeth involved should undergo a crown lengthening procedure.



The natural tooth's crown (A) meets the root (B) at the cemento-enamel junction, and it is roughly at this point that the gingival attachment begins at the base of the gingival sulcus (G). The margin of the prosthetic crown may not violate the 2 mm of biologic width from the base of this sulcus to the height of the alveolar bone (C) if complications are to be avoided.

There are a number of different types of margins that can be placed for restoration with a crown. There is the chamfer, which is popular with full gold restorations, which effectively removed the smallest amount of tooth structure. There is also a **shoulder**, which, while removing slightly more tooth structure, serves to allow for a thickness of the restoration material, necessary when applying porcelain to a **PFM coping** or when restoring with an **all-ceramic crown**. When using a shoulder preparation, the dentist is urged to add a bevel; the shoulder-bevel margin serves to effectively decrease the tooth-to-restoration distance upon final cementation of the restoration.

Ferrule effect

A very important consideration when restoring with a crown is the incorporation of the **ferrule effect**. As with the bristles of a broom, which are grasped by a ferrule when attached to the broomstick, the crown should envelop a certain height of tooth structure to properly protect the tooth from fracture after being prepared for a crown. This has been established through multiple experiments as a mandatory continuous circumferential height of 2 mm; any less provides for a significantly higher failure rate of endodontically-treated crown-restored teeth. When a tooth is not endodontically treated, the remaining tooth structure will invariably provide the 2 mm height necessary for a ferrule, but endodontically treated teeth are notoriously decayed and are often missing significant solid tooth structure. Because they are weaker after the additional removal of tooth structure that occurs during a root canal procedure, endodontically treated teeth require proper protection against vertical root fracture. Contrary to what some dentists believe, a bevel *is not* at all suitable for implementing the ferrule effect, and beveled tooth structure may not be included in the 2 mms of required tooth structure for a ferrule. Some have speculated that a shoulder preparation on an all ceramic crown that will be bonded in place may have the same effect as a ferrule.

Adequate and appropriate restoration of tooth structure

As crowns are fabricated indirectly (outside of the mouth) free of the encumbrances of saliva, blood, and tight quarters, they can be made to fit more precisely than restorative materials placed directly (inside the mouth). In regards to marginal adaptations (the circumferential seal which keeps bacteria out), anatomically correct contacts (touching adjacent teeth properly so food will not be retained), and proper morphology, the indirect fabrication of the restorations are unprecedented. Indirectly fabricated crowns may be fabricated one of two ways. In the traditional sense, the tooth in question is prepared, a mold is taken, a temporary crown is placed and then the patient leaves. The mold is then sent to a dental laboratory whereby a model is constructed from the mold, and a crown is created on the model (usually out of porcelain, ceramic, gold, or porcelain/ceramic fused to metal) to replace the missing tooth structure. The patient returns to the dental office a week or two later and then the temporary is removed and the crown is fitted and cemented in place. Alternatively, a crown may be indirectly fabricated utilizing technology and techniques relating to CAD/CAM Dentistry, whereby the tooth is prepared and computer software is used to create a virtual restoration which is milled on the spot and bonded permanently in place an hour or two later.

3/4 and 7/8 crowns

There are even restorations that fall between an onlay and a full crown when it comes to preservation of natural tooth structure. In the past, it was somewhat common to find dentists who prepared teeth for **3/4 and 7/8 crowns**. Such restorations would generally be fabricated for maxillary second premolars or first molars, which might only be slightly visible when a patient smiled. Thus, the dentist would preserve healthy natural tooth structure that existed on the mesiobuccal corner of the tooth for aesthetic purposes, the remainder of the tooth would be enclosed in restorative material. Even when porcelain-fused-to-metal and all-ceramic crowns were developed, preserving *any* amount of tooth structure adds to the overall strength of the tooth. As one can imagine, though, those dentists who took issue with the increased marginal length of the onlay restoration would *surely* take issue with the purported advantages of increased remaining tooth structure when it translated into the enormously increased marginal length of a 3/4 or 7/8 crown.

All-ceramic restorations

Inlays, onlays, porcelain veneers, crownlays and all varieties of crowns can also be fabricated out of ceramic materials, such as in CAD/CAM Dentistry or traditionally in a dental laboratory setting. CAD/CAM technology can allow for the immediate, same day delivery of these types restorations which are milled out of blocks of solid porcelain which matches the shade or color of the patients teeth. Traditionally, all-ceramic restorations have been made off site in a dental laboratory either out of feldspathic porcelains or pressed ceramics. This indirect method of fabrication involves molds and temporaries, but can yield quite beautiful end-results if communication between the laboratory and the dentist is sound. The greatest difference between these two differing modalities lies in the fact that the CAD/CAM route does not require temporization, while the laboratory-fabricated route does. Some argue that this lack of temporization can result in a decreased need for root canal therapy, as there is no temporary leakage between visits.

Restorations that are all-ceramic require wide shoulder margins and reductions of at least 1.0 - 1.5 mm across the occlusal (chewing) surfaces of the teeth. There are times where this reduction would be considered excessive, just as there are times when previous restorations or pathology require this much removal or more. Arguments against using all-ceramic restorations include a greater chance of fracture, when little to no enamel remains for proper adhesive bonding, or potentially when the patient clenches or grinds their teeth ("bruxes") excessively. Indications for using all-ceramic restorations include more aesthetic results, when metal compatibility issues exist, and when removal of less tooth structure is desired. All-ceramic restorations do not require resistance and retention form and consequently less surface area need be removed and the restoration will still stay in place by virtue of micromechanical and chemical bonding.

Ceramic materials such as lithium disilicate dental ceramics have recently been developed which provide greater strength and life-expectancy of dental restorations.

Longevity

Although no dental restoration lasts forever, the average lifespan of a crown is around 10 years. While this is considered comparatively favorable to direct restorations, they can actually last up to the life of the patient (50 years or more) with proper care. One reason why a 10 year mark is given is because a dentist can usually provide patients with this number and be confident that a crown that the dental lab makes will last at least this long. It should be noted that many dental insurance plans in North America will allow for a crown to be replaced after only five years.

The most important factor affecting the lifespan of any restorative is the continuing oral hygiene performed by the patient. With crowns, as with most things, a poorly-made object can last well past its predicted lifetime if it is properly cared for, and even a well-made item can last only a day if handled improperly. Other factors depend on the skill of the dentist and their lab technician, the material used and appropriate treatment planning and case selection.

Full gold crowns last the longest, as they are fabricated as a single piece of gold. PFMs, or porcelain-fused-to-metal crowns possess an additional dimension in which they are prone to failure, as they incorporate brittle porcelain into their structure. Although incredibly strong in compression, porcelain is terribly fragile in tension, and fracture of the porcelain increased the risk of failure, which rises as the amount of surfaces covered with porcelain is increased. A traditional PFM with occlusal porcelain (i.e. porcelain applied to the biting surface of a posterior tooth) has a 7% higher chance of failure per year than a corresponding full gold crown.

When crowns are used to restore endodontically treated teeth, they increase the life of the tooth not only by preventing fracture of the brittle devitalized tooth but also by providing a better seal against invading bacteria. Although the inert filling material within the root canal blocks against microbial invasion of the internal tooth structure, it is actually a superior coronal seal, or marginal adaptation of the restoration in or on the crown of the tooth, which prevents reinvasion of the root canal.

Advantages and disadvantages

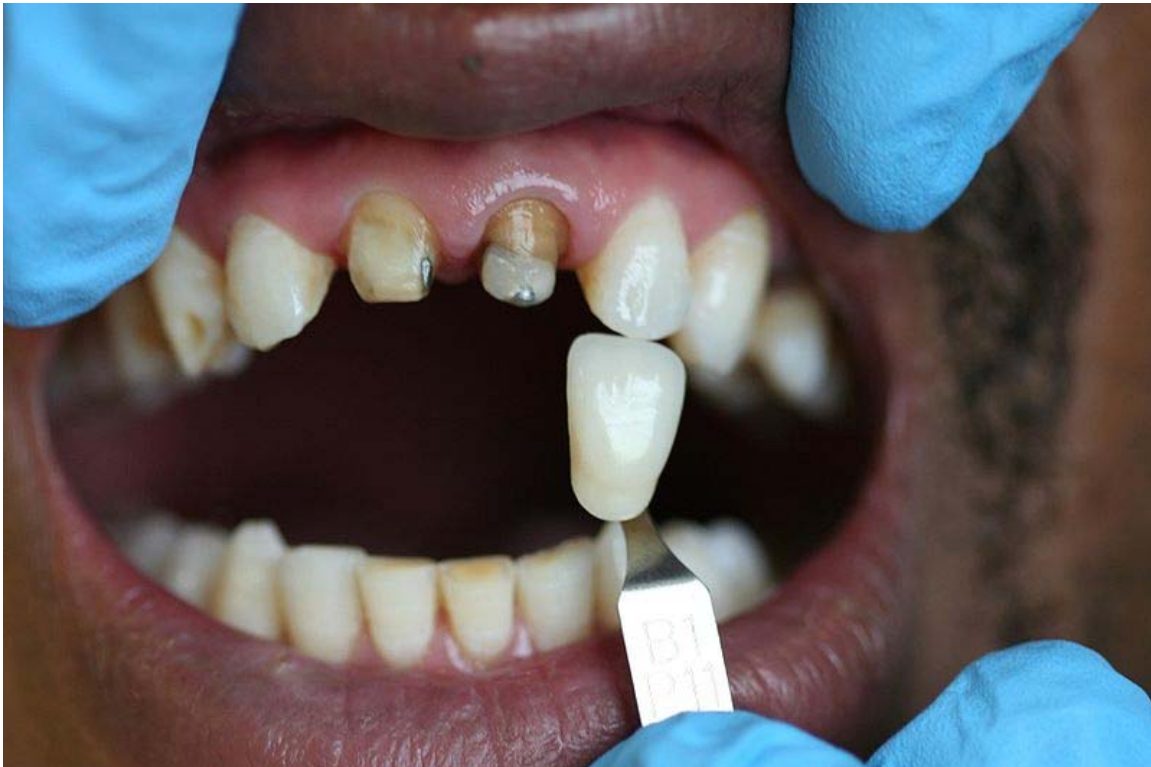The main disadvantages of restoration with a crown are extensive irreversible tooth preparation (grinding away) and higher costs than for direct restorations such as amalgam or Dental composite. The benefits, as described above, include long-term durability and evidence-based success as compared to other restorations or no treatment. The crowning of two fairly large molars to sling a bridge between them for a missing tooth is a costly and sometimes oversold procedure. The increased food and bacteria trapping of the underside of the bridge often offsets the benefits of the bridge element in maintaining the positions of the opposing teeth and the loss of the ease of use and mouth feel of two big natural teeth.

It is important to bear in mind that it is usually the damage to a tooth that dictates the need for a crown, and alternative treatments are usually less effective. However, it is also important to realise that even if risks and benefits are objectively analysed, their significance depends on the priorities of the patient. An example of this occurs when a patient would like to restore an edentulous area between healthy adjacent teeth. Before implants, there were three options:

- Fixed partial denture (bridge)
- Removable partial denture
- No treatment

Those who could afford it were usually told by their dentists that a bridge was their best choice, because it is much sturdier than removable dentures and requires less looking after. When implants became available, however, they were recommended as the best possible treatment, because the virgin teeth adjacent to the edentulous area no longer needed to be cut in order to fit the bridge. The affluent are thus told that a fixed partial denture is no longer desirable, now that implants are available. However, implants are significantly more expensive than a bridge, and the results are generally much less immediate.

Types and materials



In order to determine the shade for the future crowns, the shade of adjacent teeth are matched to preformed shade guides. Here, the shade is determined to match best with B1.

(The two maxillary central incisors have already been cut down and prepared for crowns.)

There are many different methods of crown fabrication, each using a different material. Some methods are quite similar, and utilize either very similar or identical materials.

Metal-containing restorations

Full gold crown

Full gold crowns (FGCs) consist entirely of a single piece of alloy. Although referred to as a *gold* crown, this type of crown is actually composed of many different types of elements, including but not limited to gold, platinum, palladium, silver, copper and tin. The first three elements listed are noble metals, while the last three listed are base metals. Full gold crowns are of better quality when they are high in noble content. According to the American Dental Association, full gold crown alloys can only be labeled as *high noble* when they contain at least 60% noble metal, of which at least 40% must be gold.

Full gold crowns are cast metal restorations that are made using the lost-wax technique. After the dentist prepares a tooth for a crown, he or she will take an impression of the prepared tooth, the adjacent teeth in the same arch and the opposing teeth in the opposing arch. With all of the necessary boundaries of the future cast crown defined in three dimensions within the impression material (i.e. the necessary height, width and depth of the crown is now recorded in impression material), the impression(s) are sent to a dental laboratory where they will be poured up in various types of dental stone or plaster. After the stone models are formed, they are ditched, died and articulated so that the laboratory technician can see how the two arches meet and properly access the tooth replicates to perform his tasks. The lab technician will then apply wax to the die (analog of the prepared tooth) and manipulate and craft the wax until he or she has built it up into what appears like and conforms to the specific dimensions of the tooth being restored. Prior to applying the wax, though, a die spacer is applied to the die. This is a thin coat of material that is painted onto the die to provide a space between the gold crown and the actual tooth structure to be filled with cement upon final cementation. A lubricant is also applied so that the wax pattern, as the wax-up of the crown is referred to, can be easily removed when completed.

The wax pattern is removed from the die and invested in a sort of plaster while connected to a short plastic stick, called a "sprue former", which will stick out of the investing plaster. The investment, as it is called now, is placed in a furnace, which will completely burn off the wax and plastic that formed the wax pattern/sprue complex. What is left is a hollow within the investment material, known as an "investment pattern". Because the sprue former stuck out a little bit from the investment material, there is a communication between the outside and the investment pattern. The investment pattern is then placed in a sort of simple centrifuge where pennyweights of gold are melted down and rapidly shot through the communication in the investment pattern, through the sprue that was formed by the sprue former, and into the hollow that used to be inhabited by the wax pattern of

the crown waxed-up by the technician, thus called the lost-wax technique. After properly cooling, the single piece crown-and-sprue of gold is sectioned, and the sprue can be recycled in another casting. The crown is touched-up in the location of the sprue attachment, finished and polished to a high shine, and delivered to the dentist so that he or she can try it in the mouth, make certain it has all of the proper contacts with the adjacent and opposing teeth, and cement it to the prepared tooth.

Porcelain-fused-to-metal crowns

Porcelain-fused-to-metal dental crowns (PFMs) have a metal shell on which is fused a veneer of porcelain in a high heat oven. The metal provides strong compression and tensile strength, and the porcelain gives the crown a white tooth-like appearance, suitable for front teeth restorations. These crowns are often made with a partial veneer that covers only the aspects of the crown that are visible. The remaining surfaces of the crown are bare metal. A variety of metal alloys containing precious metals and base metals can be used. The porcelain can be color matched to the adjacent teeth.

Restorations without Metal

Chairside CAD/CAM Dentistry

The CAD/CAM method of fabricating all-ceramic restorations is by electronically capturing and storing a photographic image of the prepared tooth and, using computer technology, crafting a 3D restoration design that conforms to all the necessary specifications of the proposed inlay, onlay or single-unit crown; there is no impression. After selecting the proper features and making various decisions on the computerized model, the dentist directs the computer to send the information to a local milling machine. This machine will then use its specially designed diamond burs to mill the restoration from a solid ingot of a ceramic of pre-determined shade to match the patient's tooth. After about 20 minutes, the restoration is complete, and the dentist sections it from the remainder of the unmilled ingot and tries it in the mouth. If the restoration fits well, the dentist can cement the restoration immediately. A dental CAD/CAM machine costs roughly \$100,000, with continued purchase of ceramic ingots and milling burs.

Typically, over 95% of the restorations made using Dental CAD/CAM and Vita Mark I and Mark II blocks are still clinically successful after 5 years. Further, at least 90% of restorations still function successfully after 10 years. Advantages of the Mark II blocks over ceramic blocks include: they wear down as fast as natural teeth, , their failure loads are very similar to those of natural teeth, and the wear pattern of Mark II against enamel is similar to that of enamel against enamel.

Empress

The Empress system is superficially similar to a lost-wax technique in that a hollow investment pattern is made, but the similarities stop there. A specially designed pressure-injected leucite-reinforced ceramic is then pressed into the mold by using a pressable-

porcelain-oven, as though the final all-ceramic restoration has been "cast." The Empress can be utilized for anything the lost-wax technique can be used for, in addition to veneers (which would not be made of cast metal).

In-ceram

Introduced in 1989, In-ceram, by Vita, infused the fragile new "all-ceramic crown" with glass to produce what was then thought to be a superior product.

Procera

Procera AllCeram, owned by Nobel Biocare, is a CAD/CAM based method which produces a crown by overlaying a very durable ceramic coping of either **alumina** or **zirconia**, referred to as a "core", with Vitadur Alpha porcelain. Introduced in 1991, Procera can now be used to produce crowns, bridges and veneers.

Chapter 13

Dental Restorative Materials

Dental restorative materials are specially fabricated materials, designed for use as dental restorations (fillings), which are used to restore tooth structure loss, usually resulting from but not limited to dental caries (dental cavities). There are many challenges for the physical properties of the ideal dental restorative material.

Restorative material development

The goal of research and development is to develop the ideal restorative material. The ideal restorative material would be identical to natural tooth structure, in strength adherence and appearance. The properties of an ideal filling material can be divided into four categories: physical properties, biocompatibility, aesthetics and application.

Physical properties

Requisite physical properties include low thermal conductivity and expansion, resistance to different categories of forces and wear like attrition and abrasion and resistance to chemical erosion. There must also be good bonding strength to the tooth. Everyday masticatory forces and conditions must be withstood without fatiguing.

Biocompatibility

Biocompatibility refers to how well the material coexists with the biological equilibrium of the tooth and body systems. Since fillings are in close contact with mucosa, tooth, and pulp, biocompatibility is very important. Common problems with some of the current dental materials include chemical leakage from the material, pulpal irritation and less commonly allergy. Some of the byproducts of the chemical reactions during different stages of material hardening need to be considered.

Aesthetics

Filling materials ideally would match the surrounding tooth structure in shade, translucency, and texture.

Application

Dental operators require materials that are easy to manipulate and shape, where the chemistry of any reactions that need to occur are predictable or controllable.

Direct restorative materials

The chemistry of the setting reaction for direct restorative materials is designed to be more biologically compatible. Heat and byproducts generated cannot damage the tooth or patient, since the reaction needs to take place while in contact with the tooth during restoration. This ultimately limits the strength of the materials, since harder materials need more energy to manipulate.

Amalgam

Amalgam is a metallic filling material composed from a mixture of mercury (from 43% to 54%) and powdered alloy made mostly of silver, tin, zinc and copper commonly called the amalgam alloy. Amalgam does not adhere to tooth structure without the aid of cements, or techniques which lock in the filling, using the same principles as a dovetail joint. Amalgam is still used extensively in many parts of the world because of its cost effectiveness, superior strength and longevity. However their metallic colour is not aesthetic and tooth coloured alternatives are continually emerging with increasingly comparable properties. Due to the known toxicity of the element mercury, there is some controversy about the use of amalgams. *Amalgam: The most popular amalgam was a mixture of silver, tin and mercury. According to the authors of the article "*It set very hard and lasted for many years, the major contradiction being that it oxidized in the mouth, turning teeth black. Also the mercury contained in the amalgam was thought at that time to be harmful.*" as explained in the pre-eminent dental textbook of that century, *The Principles and Practice of Dental Surgery* by Chapin A. Harris A.M., M.D., D.D.S.. More recent dental texts strongly support the use of amalgam; "In summary, dental amalgam is a highly successful material clinically and is very cost effective, but alternatives such as cast gold and esthetic restorative materials are now very competitive in terms of frequency of use. Many argue, however, that the use of amalgam must be strongly supported given its large public health benefit in the United States and many other countries."

Composite resin

Composite resin fillings (also called white fillings) are a mixture of powdered glass and plastic resin, and can be made to resemble the appearance of the natural tooth. They are strong, durable and cosmetically superior to silver or dark grey colored amalgam fillings. Composite resin fillings are usually more expensive than amalgam fillings. Bis-GMA based materials contain Bisphenol A, a known endocrine disrupter chemical, and may contribute to the development of breast cancer. PEX-based materials do not.

Most modern composite resins are light-cured photopolymers, meaning that they harden with light exposure. They can then be polished to achieve maximum aesthetic results. Composite resins experience a very small amount of shrinkage upon curing, causing the material to pull away from the walls of the cavity preparation. This makes the tooth slightly more vulnerable to microleakage and recurrent decay. There are handling techniques combined with material selection, which minimize or eliminate microleakage.

In some circumstances, less tooth structure can be removed compared to preparation for other dental materials such as amalgam and many of the indirect methods of restoration. This is because composite resins bind to enamel (and dentin too, although not as well) via a micromechanical bond. As conservation of tooth structure is a key ingredient in tooth preservation, many dentists prefer placing materials like composite instead of amalgam fillings whenever possible.

Generally, composite fillings are used to fill a carious lesion involving highly visible areas (such as the central incisors or any other teeth that can be seen when smiling) or when conservation of tooth structure is a top priority.

The bond of composite resin to tooth, is especially affected by moisture contamination and cleanliness of the prepared surface. Other materials can be selected when restoring teeth where moisture control techniques are not effective.

Glass Ionomer Cement

These fillings are a mixture of glass and an organic acid. Although they are tooth-colored, glass ionomers vary in translucency. Although glass ionomers can be used to achieve an aesthetic result, their aesthetic potential does not measure up to that provided by composite resins.

The cavity preparation of a glass ionomer filling is the same as a composite resin; it is considered a fairly conservative procedure as the bare minimum of tooth structure should be removed.

Conventional glass ionomers are chemically set via an acid-base reaction. Upon mixing of the material components, there is no light cure needed to harden the material once placed in the cavity preparation. After the initial set, glass ionomers still need time to fully set and harden.

Glass ionomers do have their advantages over composite resins:

1. They are not subject to shrinkage and microleakage, as the bonding mechanism is an acid-base reaction and not a polymerization reaction.
2. Glass ionomers contain and release fluoride, which is important to preventing carious lesions. Furthermore, as glass ionomers release their fluoride, they can be "recharged" by the use of fluoride-containing toothpaste. Hence, they can be used as a treatment

modality for patients who are at high risk for caries. Newer formulations of glass ionomers that contain light-cured resins can achieve a greater aesthetic result, but do not release fluoride as well as conventional glass ionomers.

Glass ionomers are about as expensive as composite resin. The fillings do not wear as well as composite resin fillings. Still, they are generally considered good materials to use for root caries and for sealants.

Resin modified Glass-Ionomer Cement (RMGIC)

A combination of glass-ionomer and composite resin, these fillings are a mixture of glass, an organic acid, and resin polymer that harden when light cured. (The light activates a catalyst in the cement that causes it to cure in seconds.) The cost is similar to composite resin. It holds up better than glass ionomer, but not as well as composite resin, and is not recommended for biting surfaces of adult teeth.

In general, resin modified glass-ionomer cements can achieve a better aesthetic result than conventional glass ionomers, but not as good as pure composites. It has its own setting reaction.

Compomers

Again a combination of Composite resin and glass ionomer technology, however with the focus lying towards the composite resin end of the spectrum. Has better mechanical and aesthetic properties than RMGIC but worse wear and requires a bonding system to be used. Although compomers release fluoride, they do so at such a low level that it is not deemed effective, and unlike glass ionomer and RMIC cannot act as a fluoride reservoir.

Indirect Restorative materials

Porcelain (ceramic)

Porcelain fillings are hard, but can cause wear on opposing teeth. They are brittle and are not always recommended for molar fillings.

Gold

Gold fillings have excellent durability, wear well, and do not cause excessive wear to the opposing teeth, but they do conduct heat and cold, which can be irritating. There are two categories of gold fillings, cast gold fillings (gold inlays and onlays) made with 14 or 18 kt gold, and gold foil made with pure 24 kt gold that is burnished layer by layer. For years, they have been considered the benchmark of restorative dental materials. Recent advances in dental porcelains and consumer focus on aesthetic results have caused demand for gold fillings to drop in favor of advanced composites and porcelain veneers and crowns. Gold fillings are sometimes quite expensive, although they do last a very

long time, which can mean gold restorations are less costly and painful in the long run. It is not uncommon for a gold crown to last 30 years.

Other historical fillings

Lead fillings were used in the 18th century, but became unpopular in the 19th century because of their softness. This was before lead poisoning was understood.

According to American Civil War-era dental handbooks from the mid-19th century, since the early 19th century metallic fillings had been used, made of lead, gold, tin, platinum, silver, aluminum, or amalgam. A pellet was rolled slightly larger than the cavity, condensed into place with instruments, then shaped and polished in the patient's mouth. The filling was usually left "high", with final condensation — "tamping down" — occurring while the patient chewed food. Gold foil was the most popular and preferred filling material during the Civil War. Tin and amalgam were also popular due to lower cost, but were held in lower regard.

One survey of dental practices in the mid-19th century catalogued dental fillings found in the remains of seven Confederate soldiers from the U.S. Civil War; they were made of:

- Gold foil: Preferred because of its durability and safety.
- Platinum: Was rarely used because it was too hard, inflexible and difficult to form into foil.
- Aluminum: A material which failed because of its lack of malleability but has been added to some amalgams.
- Tin and iron: Believed to have been a very popular filling material during the Civil War. Tin foil was recommended when a cheaper material than gold was requested by the patient, however tin wore down rapidly and even if it could be replaced cheaply and quickly, there was a concern, specifically from Harris, that it would oxidise in the mouth and thus cause a recurrence of caries. Due to the blackening, tin was only recommended for posterior teeth.
- Thorium: Radioactivity was unknown at that time, and the dentist probably thought he was working with tin.
- Lead and tungsten mixture, probably coming from shotgun pellets. Lead was rarely used in the 19th century, it is soft and quickly worn down by mastication, and had known harmful health effects.

Failure of dental restorations

Fillings have a finite lifespan: an average of 12.8 years for amalgam and 7.8 years for composite resins. One advantage of gold restorations is longevity, because gold can outlast other materials by three to five times longer. When describing other materials, dentists talk in terms of years of service, whereas with cast gold, dentists speak of decades of service. To achieve the greatest longevity, gold dental work must be done with sufficient skill and precision, so discerning patients should seek gold dentists with quality training, experience and expertise.

Fillings fail because of changes in the filling, tooth or the bond between them.

Amalgam fillings expand with age, possibly cracking the tooth and requiring repair and filling replacement. Composite fillings shrink with age and may pull away from the tooth allowing leakage. Quality dental gold is the most biocompatible material used in dentistry today, being non-corrosive and hypo-allergenic. Dental gold's wear rates and coefficient of thermal expansion is very similar to tooth enamel, which minimizes gaps, leakage or repair due to expansion differentials over time.

As chewing applies considerable pressure on the tooth, the filling may crack, allowing seepage and eventual decay in the tooth underneath. Gold margins do not break or chip even when thinned and polished, and can achieve microscopic gaps even smaller than the diameter of bacterium that cause tooth decay.

The tooth itself may be weakened by the filling and crack under the pressure of chewing. That will require further repairs to the tooth and replacement of the filling. On the other hand, less tooth structure is removed when preparing teeth for gold dental restoration, which leaves the tooth stronger and healthier.

Gold restorations, if done properly, could last the lifetime of a patient. As life expectancies increase, thoughtful dental material choices become even more important to reduce the number of times that fillings and other restorations must be replaced. Repeated repairs to teeth can lead to pulpal inflammation and necrosis, root canal therapy and the eventual necessity for crowns in lieu of fillings. Restoring a tooth only once, with highly durable, non-toxic, biocompatible materials like gold, can be very appealing to discerning patients, and be less costly and painful in the long run.

If fillings leak or if the original bond is inadequate, the bond may fail even if the filling and tooth are otherwise unchanged.

Evaluation and regulation of dental materials

The Nordic Institute of Dental Materials (NIOM) evaluates dental materials in the Nordic countries. This research and testing institution are accredited to perform several test procedures for dental products. In Europe, dental materials are classified as medical devices according to the Medical Devices Directive. In USA, the U.S. Food and Drug Administration is the regulatory body for dental products.

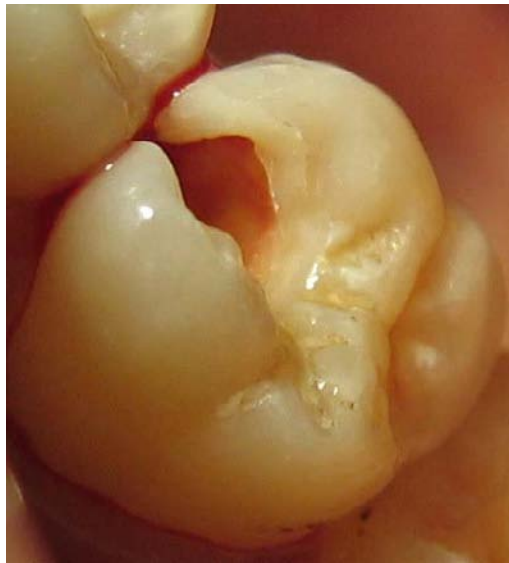Chapter 14

Dental Restoration

A **dental restoration** or **dental filling** is a dental restorative material used to restore the function, integrity and morphology of missing tooth structure. The structural loss typically results from caries or external trauma. It is also lost intentionally during tooth preparation to improve the aesthetics or the physical integrity of the intended restorative material. Dental restoration also refers to the replacement of missing tooth structure that is supported by dental implants.

Dental restorations can be divided into two broad types: *direct restorations* and *indirect restorations*. All dental restorations can be further classified by their location and size. A root canal filling is a restorative technique used to fill the space where the dental pulp normally resides.

Tooth preparation



Tooth #3, the upper right first molar, with the beginning of an MO preparation. Looking into the preparation, the white, outer enamel appears intact, while the yellow, underlying dentin appears recessed. This is because the dentin was decayed and was thus removed. This portion of the enamel is now unsupported, and should be removed to prevent future fracture.

Restoring a tooth to good form and function requires two steps, (1) preparing the tooth for placement of restorative material or materials, and (2) placement of restorative material or materials.

The process of preparation usually involves cutting the tooth with special dental burrs, to make space for the planned restorative materials, and to remove any dental decay or portions of the tooth that are structurally unsound. If permanent restoration can not be carried out immediately after tooth preparation, temporary restoration may be performed.

The prepared tooth, ready for placement of restorative materials, is generally called a **tooth preparation**. Materials used may be gold, amalgam, dental composites, resin-reinforced glass ionomers, porcelain or any number of other materials.

Preparations may be intracoronal or extracoronal.

- **Intracoronal preparations** are those preparations which serve to hold restorative material within the confines of the structure of the crown of a tooth. Examples include all classes of cavity preparations for composite or amalgam, as well as those for gold and porcelain inlays. Intracoronal preparations are also made as female recipients to receive the male components of Removable partial dentures.
- **Extracoronal preparations** are those preparations which serve as a core or base upon which or around which restorative material will be placed to bring the tooth back into a functional or aesthetic structure. Examples include crowns and onlays, as well as veneers.

In preparing a tooth for a restoration, a number of considerations will come into play to determine the type and extent of the preparation. The most important factor to consider is decay. For the most part, the extent of the decay will define the extent of the preparation, and in turn, the subsequent method and appropriate materials for restoration.

Another consideration is unsupported tooth structure. In the photo at right, unsupported enamel can be seen where the underlying dentin was removed because of infiltrative decay. When preparing the tooth to receive a restoration, unsupported enamel is removed to allow for a more predictable restoration. While enamel is the hardest substance in the human body, it is particularly brittle, and unsupported enamel fractures easily.

Direct restorations

This technique involves placing a soft or malleable filling into the prepared tooth and building up the tooth before the material sets hard. The advantage of direct restorations is that they usually set quickly and can be placed in a single procedure. Since the material is required to set while in contact with the tooth, limited energy can be passed to the tooth from the setting process without damaging it. Where strength is required, especially as the fillings become larger, indirect restorations may be the best choice.

Indirect restorations

This technique of fabricating the restoration outside of the mouth using the dental impressions of the prepared tooth. Common indirect restorations include inlays and onlays, crowns, bridges, and veneers. Usually a dental technician fabricates the indirect restoration from records the dentist has provided of the prepared tooth. The finished restoration is usually bonded permanently with a dental cement. It is often done in two separate visits to the dentist. Common indirect restorations are done using gold or ceramics.

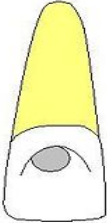
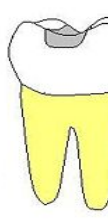

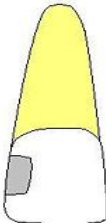
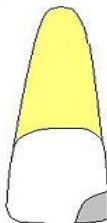
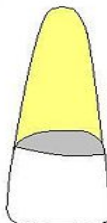


While the indirect restoration is being prepared, a provisory/temporary restoration is sometimes used to cover the prepared part of the tooth, which can help maintain the surrounding dental tissues.

Removable dental prostheses (mainly dentures) are considered by some to be a form of indirect dental restoration, as they are made to replace missing teeth. There are numerous types of precision attachments (also known as combined restorations) to aid removable prosthetic attachment to teeth, including magnets, clips, hooks and implants which could be seen as a form of dental restoration.

The CEREC method is a chairside CAD/CAM restorative procedure. An optical impression of the prepared tooth is taken using a camera. Next, the specific software takes the digital picture and converts it into a 3D virtual model on the computer screen. A ceramic block that matches the tooth shade is placed in the milling machine. An all-ceramic, tooth-colored restoration is finished and ready to bond in place.

Another fabrication method is to import STL and native dental CAD files into CAD/CAM software products that guide the user through the manufacturing process. The software can select the tools, machining sequences and cutting conditions optimized for particular types of materials, such as titanium and zirconium, and for particular prostheses, such as copings and bridges. In some cases, the intricate nature of some implants requires the use of 5-axis machining methods to reach every part of the job.

Restoration classifications

G.V. Black							
L	B/L	B/L	F	F	F/L	B/L	B/L
							
Class I	Class II		Class III	Class IV	Class V		Class VI

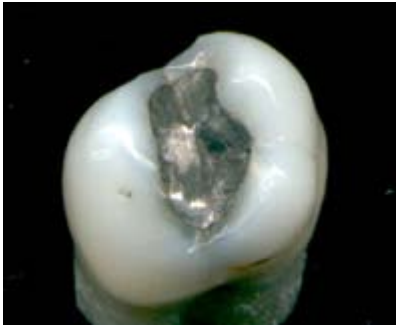GV Black Classification of Restorations

Greene Vardiman Black classified the fillings depending on their size and location.

- Class I Caries affecting pit and fissure, on occlusal, buccal, and lingual surfaces of posterior teeth, and Lingual of anterior teeth.
- Class II Caries affecting proximal surfaces of molars and premolars.
- Class III Caries affecting proximal surfaces of centrals, laterals, and cuspids.
- Class IV Caries affecting proximal including incisal edges of anterior teeth.
- Class V Caries affecting gingival 1/3 of facial or lingual surfaces of anterior or posterior teeth.
- Class VI Caries affecting cusp tips of molars, premolars, and cuspids.

Materials used in dental restorations

Metals and metallic alloys



Amalgam filling

These metals are mostly used for making crowns, bridges and dentures. Pure titanium could be successfully incorporated into bone. It is biocompatible and stable.

Precious metallic alloys

- gold (high purity: 99.7%)
- gold alloys (with high gold content)
- gold-platina alloy
- silver-palladium alloy
- titanium

Base metallic alloys

- cobalt-chromium alloy
- nickel-chrome alloy

Amalgam

- Silver amalgam

Amalgam is widely used for direct fillings, mainly for posterior teeth, and completed in single appointment. Cast gold is used for indirect restorations. Amalgam leaches tiny amounts of mercury and while some concerns have been raised, there is currently no evidence that any of this mercury remains in the body nor that dangerous levels are ever reached .

Direct Gold

- Gold

Although rarely used, due to expense and specialized training requirements, gold foil can be used for direct dental restorations.

Tooth colored

Dental composites are also called white fillings, used in direct fillings. Crowns and inlays can be made in the laboratory from dental composites. These materials are similar to those used in direct fillings and are tooth coloured. Their strength and durability is not as high as porcelain or metal restorations and they are more prone to wear and discolouration.

Composite resin

Dental composites, also called white fillings, are a group of restorative materials used in dentistry. As with other composite materials, a dental composite typically consists of a resin-based matrix, such as a bisphenol A-glycidyl methacrylate (BISMA) resin like urethane dimethacrylate (UDMA), and an inorganic filler such as silicon dioxide silica. Compositions vary widely, with proprietary mixes of resins forming the matrix, as well as engineered filler glasses and glass ceramics. The filler gives the composite wear resistance and translucency. A coupling agent such as silane is used to enhance the bond between these two components. An initiator package begins the polymerization reaction of the resins when external energy (light/heat, etc.) is applied. A catalyst package can control its speed. This is not recommended for molars.

After tooth preparation, a thin glue or bonding material layer is applied. Composites are then filled layer by layer and photo-polymerising each using light. At the end the surface will be shaped and polished.

Glass ionomer cement

A glass ionomer cement (GIC) is one of a class of materials commonly used in dentistry as filling materials and luting cements. These materials are based on the reaction of silicate glass powder and polyalkeonic acid. These tooth-coloured materials were introduced in 1972 for use as restorative materials for anterior teeth (particularly for eroded areas, Class III and V cavities).

As they bond chemically to dental hard tissues and release fluoride for a relatively long period, modern-day applications of GICs have expanded. The desirable properties of glass ionomer cements make them useful materials in the restoration of carious lesions in low-stress areas such as smooth-surface and small anterior proximal cavities in primary teeth. Results from clinical studies also support the use of conventional glass ionomer restorations in primary molars. They need not be put in layer by layer, like in composite fillings.

Porcelain (ceramics)

Full-porcelain (ceramic) dental materials include porcelain, ceramic or glasslike fillings and crowns (a.k.a jacket crown, as a metal-free option). They are used as in-lays, on-lays, crowns, and aesthetic veneers. A veneer is a very thin shell of porcelain that can replace or cover part of the enamel of the tooth. Full-porcelain (ceramic) restorations are particularly desirable because their color and translucency mimic natural tooth enamel.

Another type is known as *porcelain-fused-to-metal*, which is used to provide strength to a crown or bridge. These restorations are very strong, durable and resistant to wear, because the combination of porcelain and metal creates a stronger restoration than porcelain used alone.

One of the advantages of computerized dentistry (CAD/CAM technologies) is that it enabled the application of *zirconium-oxide* (ZrO_2). The introduction of this material in restorative and prosthetic dentistry is most likely the decisive step toward the use of full ceramics without limitation. With the exception of zirconium-oxide, existing ceramics systems lack reliable potential for the various indications for bridges without size limitations. Zirconium-oxide with its high strength and comparatively higher fracture toughness seems to buck this trend. With a three-point bending strength exceeding 900 megapascals, zirconium-oxide can be used in virtually every full ceramic prosthetic solution, including bridges, implant supra structures and root dowel pins.

Previous attempts to extend its application to dentistry were thwarted by the fact that this material could not be processed using traditional methods used in dentistry. The arrival of computerized dentistry enables the economically prudent use of zirconium-oxide in such elements as base structures such as copings and bridges and implant supra structures. Special requirements apply to dental materials implanted for longer than a period of thirty days. Several technical requirements include high strength, corrosion resistance and defect-free producibility at a reasonable price.

Ever more stringent requirements are being placed on the aesthetics of teeth. *Metals* and porcelain are currently the materials of choice for crowns and bridges. The demand for full ceramic solutions, however, continues to grow. Consequently, industry and science are increasingly compelled to develop full ceramic systems. In introducing full ceramic restorations, such as base structures made of sintered ceramics, computerized dentistry plays a key role.

Comparison

- Composites and Amalgam are used mainly for direct restoration. Composites can be made of color matching the tooth, and surface can be polished after filling.
- Amalgam fillings expand with age, possibly cracking the tooth and requiring repair and filling replacement. But chance of leakage of filling is less.
- Composite fillings shrink with age and may pull away from the tooth allowing leakage. If leakage is not noticed early recurrent decay may occur.
- Fillings have a finite lifespan: an average of 12.8 years for amalgam and 7.8 years for composite resins. Fillings fail because of changes in the filling, tooth or the bond between them. Secondary caries formation can also affect the structural integrity the original filling. Fillings are recommended for small to medium sized restorations.
- Porcelain and Gold are used for indirect restorations like crowns and partial coverage crowns (onlays). Some types of porcelains are hard, but can cause wear on opposing teeth. They are brittle and are not always recommended for molar restorations. A new material called lithium disilicate (ips.emax) is indicated for use on molars for crowns and onlays now because it is fracture resistant compared to other porcelains used for dental restorations.

Experimental

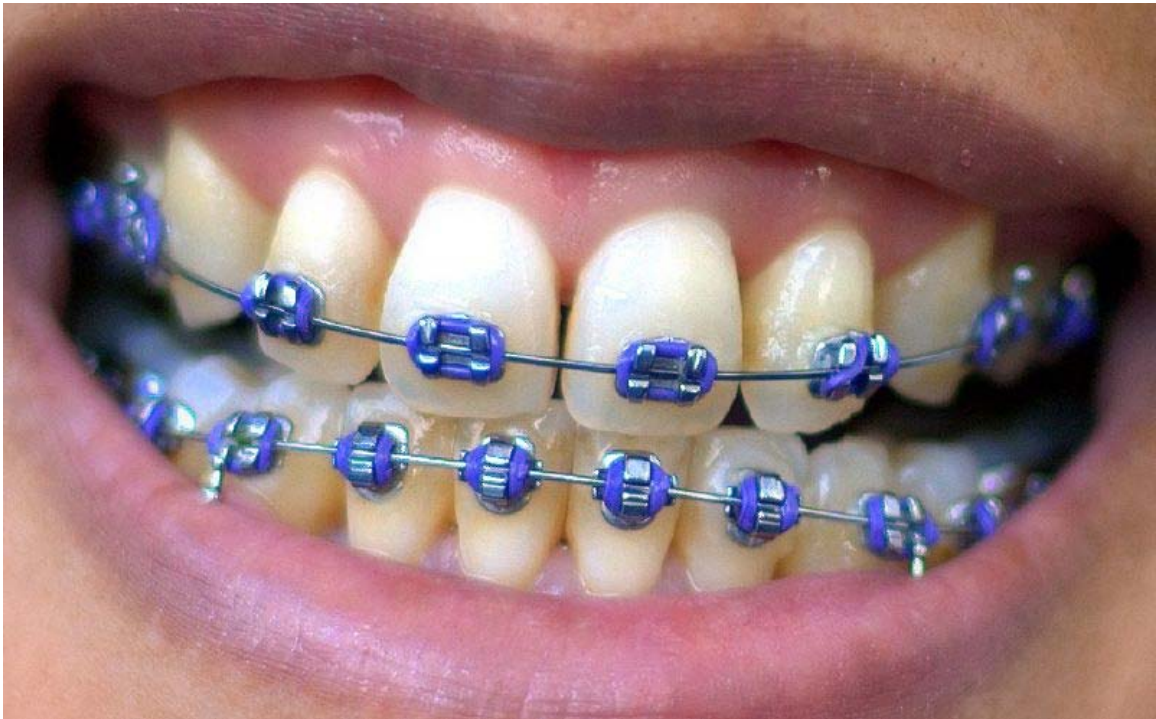
In 2010, researchers reported that they were able to stimulate mineralization of an enamel-like layer of fluorapatite *in vivo*.

Restoration of dental implants

Dental implants, are anchors placed in bone, usually made from titanium or titanium alloy. They can support dental restorations which replace missing teeth. Some restorative applications include supporting crowns, bridges, or dental prostheses.

Chapter 15

Dental Braces



Dental braces

Dental braces (also known as **orthodontic braces**, or simply **braces**) are devices used in the orthodontic industry that help align and straighten teeth and help to position them with regard to a person's bite, while also working to improve dental health. They are often used to correct under bites, as well as, malocclusions , overbites, cross bites, open bites, deep bites, crooked teeth, and various other flaws of the teeth and jaw. Braces can be either cosmetic or structural. Dental braces or orthodontic braces are often used in conjunction with other orthodontic appliances to help widen the palate or jaws and to otherwise assist in shaping the teeth and jaws. While they are mainly used on children and teenagers, adults are also big contributors to this type of market including people seen on television, such as actors, Tom Cruise, Katherine Heigl, and R&B singer Fantasia.

History

Ancient Times

Braces date all the way back to ancient times according to many scholars and historians, and existed around the time 500-300BC. Many experts say that around 400-500BC, Hippocrates and Aristotle contemplated about ways to straightened teeth and to fix various dental conditions. Archaeologists have come to discover numerous mummified ancient individuals with the appearance of metal bands wrapped around their teeth. It has been perceived that catgut, which is a type of cord that is made from the natural fibers of an animal's intestines, did the work that is done by today's orthodontic wire used to close gaps in the teeth and mouth. Meanwhile in Greece during the so-called Golden Age, the Etruscans, seen as the early Romans, were burying their dead with dental appliances in place that were used to maintain space and prevent collapse of the teeth during after life. Although there is no date documented, this process was most likely before the start of our era. An unknown researcher found a Roman tomb with a number of teeth bound with gold wire documented as a ligature wire, which is a small elastic wire that is used to affix the arch wire to the bracket. In the early years of our era, a philosopher and physician, Aurelius Cornelius Celsus, first recorded the treatment of teeth by finger pressure. Unfortunately, due to lack of evidence, the poor preservation of bodies, and primitive technology, not much research was done on dental braces until around the 17th century, although dentistry as a profession was making great advancements.

18th century

There are many orthodontic scholars who could be considered as the "Father of Orthodontics" who lived in the 17th, 18th, and even early 19th centuries. Dentists were continuously thinking of ways to correct bad bites. In 1728, French dentist Pierre Fauchard, who took orthodontics out of the Dark Ages, published an entire book called the "The Surgeon Dentist" on methods of straightening teeth. Fauchard, in his practice, used a device called a "Bandeau," which is a horseshoe-shaped piece of precious metal that helped expand the arch. Years later in 1757, another French dentist, Etienne Bourdet, who was also dentist to the King of France, followed Fauchard's book with "The Dentist's Art," which also dedicated a chapter to tooth alignment and application. He perfected the "Bandeau" and was the first dentist on record to recommend extraction of the premolar teeth to alleviate crowding and to improve jaw growth.

19th century

Although teeth straightening and pulling was used to improve alignment of remaining teeth and had been practiced since early times, orthodontics, as a science of its own, did not really exist until the mid-19th century. Some important dentists helped to advance dental braces with specific instruments and tools that allowed braces to be improved. In 1819, Delabarre introduced the wire crib, which marked the birth of contemporary orthodontics and gum elastics were first employed by Maynard in 1843. Tucker was the first to cut rubber bands from rubber tubing in 1850, but this was nothing compared to

advances in orthodontics in the 20th Century. Norman W. Kingsley who was a dentist, writer, artist, and sculptor in 1858 wrote the first article on orthodontics and in 1880, his book, "Treatise on Oral Deformities", was published. Also a dentist named J. N. Farrar is credited for writing two volumes entitled, "A Treatise on the Irregularities of the Teeth and Their Corrections". Farrar was very good at designing brace appliances and he was the first to suggest the use of mild force at timed intervals to move teeth.

20th century

In the early 20th century America, Edward H. Angle devised the first simple classification system for malocclusions, such as Class I, Class II, and so on. His classification system is still used today as a way for dentists to describe how crooked teeth are (what way teeth are pointing) and how teeth fit together. Angle contributed greatly to the design of orthodontic and dental appliances, making many simplifications. He founded the first school and college of orthodontics, organized the American Society of Orthodontia in 1901 which became the American Association of Orthodontists (AAO) in the 1930s, and founded the first orthodontic journal in 1907. Other innovations in orthodontics in the late 19th and early 20th centuries included the first textbook on orthodontics for children, published by J.J. Guilford in 1889, and the use of rubber elastics, pioneered by Calvin S. Case, along with H. A. Baker.

How braces work

The application of braces moves the teeth as a result of force and pressure on the teeth. There are four basic elements that are needed in order to help move the teeth. In the case of traditional metal or wire braces, one uses brackets, bonding material, arch wire, and ligature elastic, also called an "O-ring" to help align the teeth. The teeth move when the arch wire puts pressure on the brackets and teeth. Sometimes springs or rubber bands are used to put more force in a specific direction. Braces have constant pressure, which over time, move teeth into their proper positions. Occasionally adults may need to wear headgear to keep certain teeth from moving. When braces put pressure on your teeth, the periodontal membrane stretches on one side and is compressed on the other. This movement needs to be done slowly otherwise the patient risks losing his or her teeth. This is why braces are commonly worn for approximately two and a half years and adjustments are only made every three or four weeks. This process loosens the tooth and then new bone grows in to support the tooth in its new position which is technically called bone remodeling. Bone remodeling is a biomechanical process responsible for making bones stronger in response to sustained load-bearing activity and weaker in the absence of carrying a load. Bones are made of cells called osteoclasts and osteoblasts. Two different kinds of bone resorption are possible which are called direct resorption, starting from the lining cells of the alveolar bone, and indirect or retrograde resorption, which takes place when the periodontal ligament has become subjected to an excessive amount and duration of compressive stress. Another important factor associated with tooth movement is bone deposition. Bone deposition occurs in the distracted periodontal ligament and without bone deposition, the tooth will loosen and voids will occur distal to the direction of tooth movement. A tooth will usually move about a millimeter per month.

during orthodontic movement, but there is high individual variability. Orthodontic mechanics can vary in efficiency, which partly explains the wide range of response to orthodontic treatment.

Types of braces

Modern orthodontists can offer many types and varieties of braces:

- *Traditional braces* are stainless steel, sometimes in combination with nickel titanium, and are the most widely used. These include conventional braces, which require ties to hold the archwire in place, and newer self-tying (or self-ligating) brackets. Self-ligating brackets may reduce friction between the wire and the slot of the bracket, which in turn might be of therapeutic benefit.
- "*Clear*" braces serve as a cosmetic alternative to traditional metal braces by blending in more with the natural color of the teeth or having a less conspicuous or hidden appearance. Typically, these brackets are made of ceramic or plastic materials and function in a similar manner to traditional metal brackets. Clear elastic ties and white metal ties are available to be used with these clear braces to help keep the appliances less conspicuous. Clear braces have a higher component of friction and tend to be more brittle than metal braces. This can make removing the appliances at the end of treatment more difficult and time consuming.
- *Gold-plated stainless steel* braces are often employed for patients allergic to nickel (a basic and important component of stainless steel), but may also be chosen because some people simply prefer the look of gold over the traditional silver-colored braces.
- *Lingual braces* (Incognito Braces) are custom made fixed braces bonded to the back of the teeth making them invisible to other people. In lingual braces the brackets are cemented onto the backside of the teeth making them invisible while in standard braces the brackets are cemented onto the front side of the teeth. Hence, lingual braces are a cosmetic alternative to those who do not wish to have the unaesthetic metal look but wish to improve their smile.
- *Titanium braces* resemble stainless steel braces but are lighter and just as strong. People with allergies to the nickel in steel often choose titanium braces, but they are more expensive than stainless steel braces.

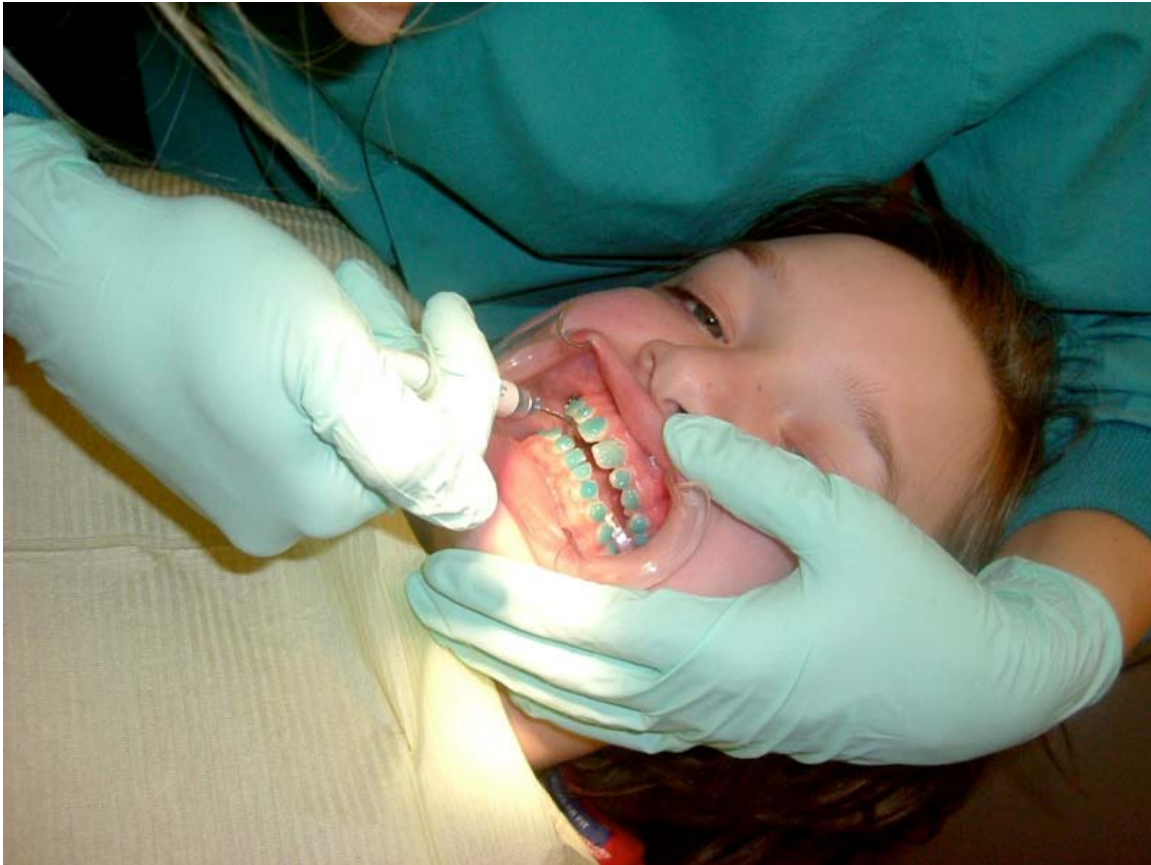Traditional braces are mostly used in treating children, as well as, adults. They consist of a small bracket that is glued to the front of each tooth and the molars are adjusted with a band that encircles the tooth. An advantage is one can eat and drink while wearing the brace but a disadvantage is that one must give up certain foods and eating habits while wearing them, such as, chewing gum and potato chips. Another disadvantage is they have to be periodically tightened by your orthodontist causing increased amounts of discomfort.

- *Progressive, clear removable aligners* (examples of which are Invisalign , Originator, ClearCorrect) may be used to gradually move teeth into their final positions. Aligners are generally not used for complex orthodontic cases, such as

when extractions, jaw surgery, or palate expansion are necessary. These braces are the most recent type of braces. Many orthodontists do not use these braces because they feel they do not produce the best corrective results compared to traditional braces, but opinions differ. These are good choices for people who have slight orthodontic problems, but can also be used in severe cases. The main attraction of these braces is they are virtually invisible making them hardly noticeable on the teeth. They work to gradually move the teeth into their right position just like traditional braces, but without the constant help of wires that need tightening. They do require an improvement in the amount of oral hygiene because they have to be removed to eat and one must brush and floss after every meal.

- For less difficult cases spring aligners are also an option that can cost much less than braces or Invisalign (one example is NightShiftOrtho) and still align primarily the front six top and bottom teeth.
- *Smart brackets* are the latest concept under investigation. The smart bracket contains a microchip that measures the forces that act on the bracket and subsequently, the tooth interface. The aim of these braces is to reduce the duration of orthodontic therapy and the related expenses and discomfort to the individual.
- *A-braces* are another new concept in dental appliances. In the shape of a capital letter A, A-braces are applied, adjusted, removed and completely controlled by the user. At the ends of the A's arms are angled knobbed bits that the user bites down over. The width between the bits is adjusted by turning the crossbar, housed across the arms. A user never has to experience pain because the pressure is so easy to control. A-braces may serve as self-adjustable retainers and palate expanders.

Procedure



A patient's teeth are prepared for application of braces

Orthodontic services may be provided by any licensed dentist trained in orthodontics. In North America most orthodontic treatment is done by orthodontists, dentists in diagnosis and treatment of *malocclusions*—malalignments of the teeth, jaws, or both. A dentist must complete 2–3 years of additional post-doctoral training to earn a specialty certificate in orthodontics. There are many general practitioners who also provide orthodontic services.

The first step is to determine whether braces are suitable for the patient. The doctor consults with the patient and inspects the teeth visually. If braces are appropriate, a records appointment is set up where X-rays, molds, and impressions are made. These records are analyzed to determine the problems and proper course of action. Typical treatment times vary from six months to two and a half years depending on the complexity and types of problems. Orthognathic surgery may be required in extreme cases. About 2 weeks before the braces are applied brackets are required to spread apart back teeth in order confirm enough space for the bands.

Teeth to be braced will have an adhesive applied to help the cement bond to the surface of the tooth. In most cases the teeth will be banded and then brackets will be added. A bracket will be applied with dental cement, and then cured with light until hardened. This

process usually takes a few seconds per tooth. If required, orthodontic spacers may be inserted between the molars to make room for molar bands to be placed at a later date. Molar bands are required to ensure brackets will stick. Bands are also utilized when dental fillings or other dental work make securing a bracket to a tooth infeasible.

An archwire will be threaded between the brackets and affixed with elastic or metal ligatures. Elastics are available in a wide variety of colors. Archwires are bent, shaped, and tightened frequently to achieve the desired results. Brackets with hooks can be placed, or hooks can be created and affixed to the archwire to affix the elastic to. The placement and configuration of the elastics will depend on the course of treatment and the individual patient. Elastics are made in different diameters, colors, sizes, and strengths.

Modern orthodontics makes frequent use of nickel-titanium archwires and temperature-sensitive materials. When cold, the archwire is limp and flexible, easily threaded between brackets of any configuration. Once heated to body temperature, the archwire will stiffen and seek to retain its shape, creating constant light force on the teeth.

When applying another type of dental brace, such as Invisalign, the process is quite different but there are similarities like the initial steps of molding the teeth before application. With Invisalign, impressions of the patient's teeth are sent for evaluation. After viewing and determining the best course of action for the patient, their series of trays are created. The patient's dentist or orthodontist receives the trays which fit to the patient's mouth almost like a protective mouthpiece.

There are some forms of braces in which the brackets are placed in a special form which are customized to the patient's mouth. This reduces the application time for the traditional type of braces. The form contains the metal brackets which are placed in the patient's mouth like a mouth guard, drastically reducing the application time.



Dental braces, with a transparent power chain, removed after completion of treatment

In many cases there is insufficient space in the mouth for all the teeth to fit properly. There are two main procedures to make room in these cases. One is extraction: teeth are removed to create more space. The second is expansion: the palate or arch is made larger by using a palatal expander. Expanders can be used with both children and adults. Since the bones of adults are already fused, expanding the palate is not possible without surgery to unfuse them. An expander can be used on an adult without surgery, but to expand the dental arch, and not the palate.

Each month or two, the braces must be adjusted. This helps shift the teeth into the correct position. When they get adjusted the orthodontist takes off the colored rubber bands keeping the wire in place. The wire is then taken out, and may be replaced or modified. When the wire has been placed back into the mouth, the patient may choose a color for the new rubber bands, which are then fixed to the metal brackets. The adjusting process may cause some discomfort, which is normal.

Post-treatment

In order to avoid the teeth moving back to their original position, retainers may be worn once the treatment with braces is complete.

Patients may need post-orthodontic surgery, such as a fibrotomy or alternatively a gum lift, to prepare their teeth for retainer use and improve the gumline contours after the braces come off.

Retainers

In order to prevent the teeth moving back to their original position, retainers may be worn once the treatment with braces is complete for the patient depending on their specific needs. If the patient does not wear the braces appropriately for the right amount of time, the teeth will move towards their previous position. For regular traditional braces Hawley retainers are used. They are made of metal hooks that surround the teeth and are enclosed by an acrylic plate shaped to fit the patient's palate. For invisalign braces an Essix retainer is used. They are similar to the regular invisalign braces and is a clear plastic tray that is form fitted to the teeth that stays in place. There is also a bonded retainer where a wire is permanently bonded to the lingual side of the teeth, usually the lower teeth only. Doctors will refuse to remove this retainer; it requires a special orthodontic appointment to have it removed.

Pre-Finisher

The Pre Finisher is molded to the patient's teeth by use of extreme pressure to the appliance by the person's jaw. The product is then worn a certain amount of time with the user applying force to the appliance in their mouth for 10 to 15 seconds at a time. The goal of the process is to increase the exercise time in applying the force to the appliance. If a person's teeth are not ready for a proper retainer the orthodontist may prescribe the use of a pre formed finishing appliance such as the Pre Finisher. This appliance fixes gaps between the teeth, small spaces between the upper and lower jaw, and other minor smaller problems that could lead to.

Complications and risks

Face shape. in the shape of your face, jaw and cheekbones may occur. It is important to discuss this with your orthodontist before you decide to get braces, as these changes are not always positive.

Plaque forms easily when food is retained in and around braces. It is important to maintain proper oral hygiene by brushing and flossing thoroughly when wearing braces to prevent tooth decay, decalcification, or unpleasant color changes to the teeth.

There is a small chance of allergic reaction to the elastics or to the metal used in braces. In even rarer cases, latex allergy may result in anaphylaxis. Latex-free elastics and alternative metals can be used instead. It is important for those who believe that they are allergic to their braces to notify the orthodontist immediately.

Mouth sores may be triggered by irritation from components of the braces. Many products can increase comfort, including oral rinses, dental wax or dental silicone, and products to help heal sores.

Braces can also be damaged if proper care is not taken. It is important to wear a mouth guard to prevent breakage and/or mouth injury when playing sports. Certain sticky or hard foods such as taffy, raw carrots, hard pretzels, and toffee should be avoided because they can damage braces. Frequent damage to braces can prolong treatment. Some orthodontists recommend sugar-free chewing gum in the belief that it may expedite treatment and relieve soreness; other orthodontists object to gum chewing because it is sticky and may therefore damage the braces.

In the course of treatment orthodontic brackets may pop off due to the forces involved, or due to cement weakening over time. The orthodontist should be contacted immediately for advice if this occurs. In most cases the bracket is replaced.

When teeth move, the end of the arch wire may become displaced, causing it to poke the back of the patient's cheek. Dental wax can be applied to cushion the protruding wire. The orthodontist must be called immediately to have it clipped, or a painful mouth ulcer may form. If the wire is causing severe pain, it may be necessary to carefully bend the edge of the wire in with a spoon or other piece of equipment (e.g. tweezers) until the wire can be clipped by an orthodontist.

Patients with periodontal disease usually must obtain periodontal treatment before getting braces. A deep cleaning is performed, and further treatment may be required before beginning orthodontic treatment. Bone loss due to periodontal disease may lead to tooth loss during treatment.

In some cases, teeth may be loose for a prolonged period of time. One may be able to wiggle one's teeth for a year or two after treatment or longer.

The dental displacement obtained with the orthodontic appliance determines in most cases some degree of root resorption. Only in a few cases is this side effect large enough to be considered real clinical damage to the tooth. In rare cases, the teeth may fall out or have to be extracted due to root resorption.

Pain and discomfort are common after adjustment and may cause difficulty eating for a time, often a couple days. During this period, eating soft foods can help avoid additional pressure on teeth.

Removal of the cemented brackets can also be painful. The cement must be chipped and scraped off which can cause severe pain in patients with sensitive teeth. Often molar bands have been installed for an extended period of time and they may be embedded in the gums at the time of removal.

The metallic look may not be desirable to some people, although transparent varieties are available. According to a survey published in the American Journal of Orthodontics and Dentofacial Orthopedics, dental braces with no visible metal were considered the most attractive. Braces that combine clear ceramic brackets with thin metal or clear wires were a less desirable option, and braces with metal brackets and metal wires were rated as the least aesthetic combination.

Treatment time and cost

Typical treatment time is from six months to six years, depending on the severity of the case, location, age, etc., although research has shown that the average duration is 1 year and 4 months. Treatment can be accelerated using novel planning, unorthodox treatment goals and positioning techniques.

The typical cost of braces ranges widely in various regions. The cost depends on whether both arches are being treated and the length of treatment. Typical orthodontic treatment comprises metal braces on both arches for 12 to 24 months. The 2007 orthodontic practice study done by the Journal of Clinical Orthodontics showed the United States national average cost of braces for comprehensive orthodontic treatment to be \$2,000 for children and \$5,354 for adults. Some cases in the United Kingdom cost £3,500, although they can much of the time be provided free on the NHS, providing the patient is under 18, a student up to 19, a pregnant woman, a nursing mother or living on a low income.

In some European countries (e.g. Norway, Finland, Sweden, Slovenia, Slovakia, Germany, Croatia or Denmark) orthodontic treatment is available without charge to patients under 18 (or for treatment to start at 16, such as Republic of Ireland and the UK) as benefits for orthodontic treatment are provided under government-run health care systems. However, in the UK, the National Health Service will not pay for braces if the teeth do not have a protrusion of over 5mm; if there is not a protrusion, it is classed as cosmetic. In some countries (e.g. Ireland), adults can also get treatment at a discounted rate, or claim tax relief after paying a full cost with a private practitioner.

In India this treatment can cost anywhere between INR 10000 to INR 80000. The cost also depends on the type of braces, the type of city the patient is in and on the orthodontist's skill and experience.

Chapter 16

Dental Drill



A high-speed dental handpiece

A **dental drill** (or **dentist's drill**) is a small, high-speed drill used in dentistry to remove decayed tooth material prior to the insertion of a dental filling. Dental drills are used in the treatment of dental caries. The term "dental drill" is considered the more colloquial form of the term "**dental handpiece**," although it can also be construed as to include the power source for one or more handpieces, a "**dental engine**." "Handpiece" and "engine" are more generic and euphemistic terms for generic dental tools.

Modern dental drills can rotate at up to 400,000 rpm, and generally use hard metal alloy bits known as burs. Dental burs come in a great variety of shapes designed for specific applications. They are often made of steel with a tungsten carbide coating, or of tungsten carbide entirely. The bur may also have a diamond coating.

Dental drills, which have a distinctive, shrill sound, are often a prominent factor in many people's fear of dentistry.

History



Foot-powered dental drill

The Indus Valley Civilization has yielded evidence of dentistry being practiced as far back as 7000 BC. This earliest form of dentistry involved curing tooth related disorders with bow drills operated, perhaps, by skilled bead craftsmen. The reconstruction of this ancient form of dentistry showed that the methods used were reliable and effective. Cavities of 3.5 mm depth with concentric groovings indicate use of a drill tool. The age of the teeth has been estimated at 9000 years. In later times, mechanical hand drills were used. Like most hand drills, they were quite slow, with speeds of up to 15 rpm. In 1864, British dentist George Fellows Harrington invented a clockwork dental drill named *Erado*. The device was much faster than earlier drills, but also very noisy. In 1868,

American dentist George F. Green came up with a pneumatic dental drill powered with pedal-operated bellows. James B. Morrison devised a pedal-powered burr drill in 1871.

The first electric dental drill was patented in 1875 by Green, a development that revolutionized dentistry. By 1914, electric dental drills could reach speeds of up to 3000 rpm. A second wave of rapid development occurred in the 1950s and 60s, including the development of the air turbine drill.

The modern incarnation of the dental drill is the air turbine handpiece, developed by John Patrick Walsh (later knighted) and members of the staff of the Dominion Physical Laboratory (DPL) Wellington, New Zealand. The first official application for a provisional patent for the handpiece was granted in October 1949. This handpiece was driven by compressed air. The final model is held by the Commonwealth Inventions development Board in Canada. The New Zealand patent number is No/104611. The patent was granted in November to John Patrick Walsh who conceived the idea of the contra angle air-turbine handpiece after he had used a small commercial-type air grinder as a straight handpiece. Dr. John Borden developed it in America and it was first commercially manufactured and distributed by the DENTSPLY Company as the Borden Airotor in 1957.

Current iterations can operate at up to 800,000 rpm, however, most common is a 400,000 rpm "high speed" handpiece for precision work complemented with a "low speed" handpiece operating at a speed that is dictated by a micromotor which creates the momentum (max up to 40,000 rpm) for applications requiring higher torque than a high-speed handpiece can deliver.

Dental bur



A collection of various burs used in dentistry

A **dental bur** is a type of burr (cutter) used in a handpiece. The burs are usually made of tungsten carbide or diamond. The three parts to a bur are the head, the neck, and the shank.

The head of the bur contains the blades which remove material. These blades may be positioned at different angles in order to change the property of the bur. More obtuse angles will produce a negative rake angle which increases the strength and longevity of the bur. More acute angles will produce a positive rake angle which has a sharper blade, but which dulls more quickly.

There are various shapes of burs that include round, inverted cone, straight fissure, tapered fissure, and pear-shaped burs. Additional cuts across the blades of burs were added to increase cutting efficiency, but their benefit has been minimized with the advent of high-speed handpieces. These extra cuts are called crosscuts.

Due to the wide array of different burs, numbering systems to categorize burs are used and include a US numbering system and a numbering system used by the International Organisation for Standardisation (ISO).

Alternatives

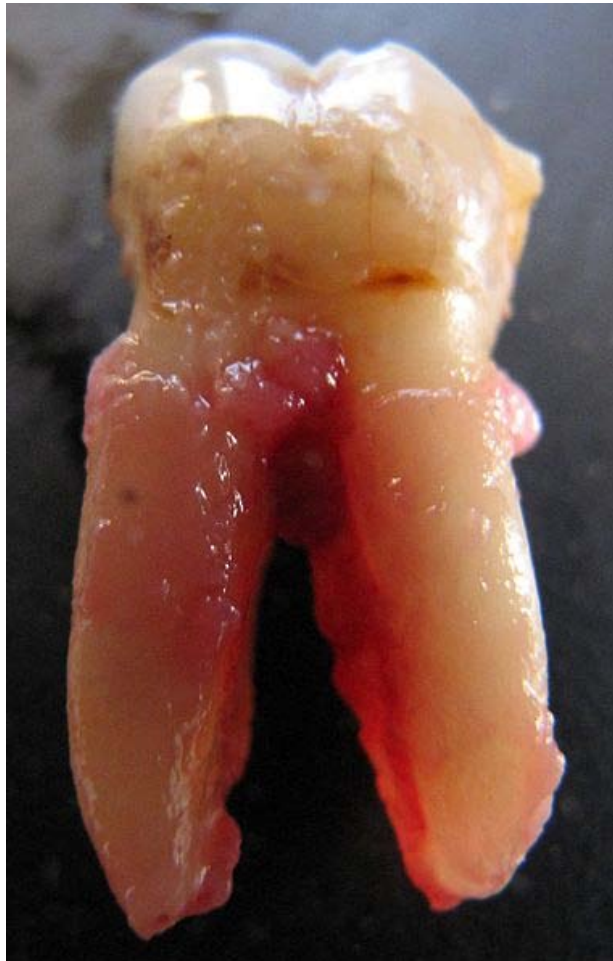Starting in the 1990s, a number of alternatives to conventional rotary dental drills have been developed. These include laser ablation systems and air abrasion devices (essentially miniature sand blasters).

Other uses

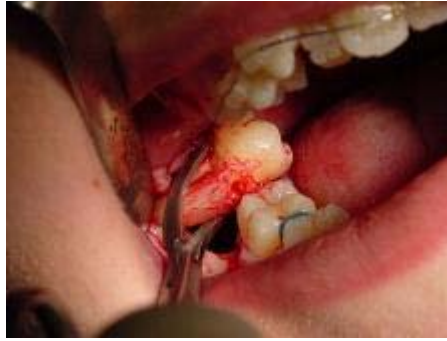Dental drills and burs are commonly used by jewellers and hobbyists for high-precision drilling work.

Chapter 17

Dental Extraction



Extracted tooth (abscess)



Surgical extraction of an impacted molar. NIDCR.

A **dental extraction** (also referred to as **exodontia**) is the removal of a tooth from the mouth. Extractions are performed for a wide variety of reasons, including tooth decay that has destroyed enough tooth structure to prevent restoration. Extractions of impacted or problematic wisdom teeth are routinely performed, as are extractions of some permanent teeth to make space for orthodontic treatment.

History

Historically, dental extractions have been used to treat a variety of illnesses, as well as a method of torture to obtain forced confessions. Before the discovery of antibiotics, chronic tooth infections were often linked to a variety of health problems, and therefore removal of a diseased tooth was a common treatment for various medical conditions. Instruments used for dental extractions date back several centuries. In the 14th century, Guy de Chauliac invented the dental pelican, which was used through the late 18th century. The pelican was replaced by the dental key which, in turn, was replaced by modern forceps in the 20th century. As dental extractions can vary tremendously in difficulty, depending on the patient and the tooth, a wide variety of instruments exist to address specific situations.

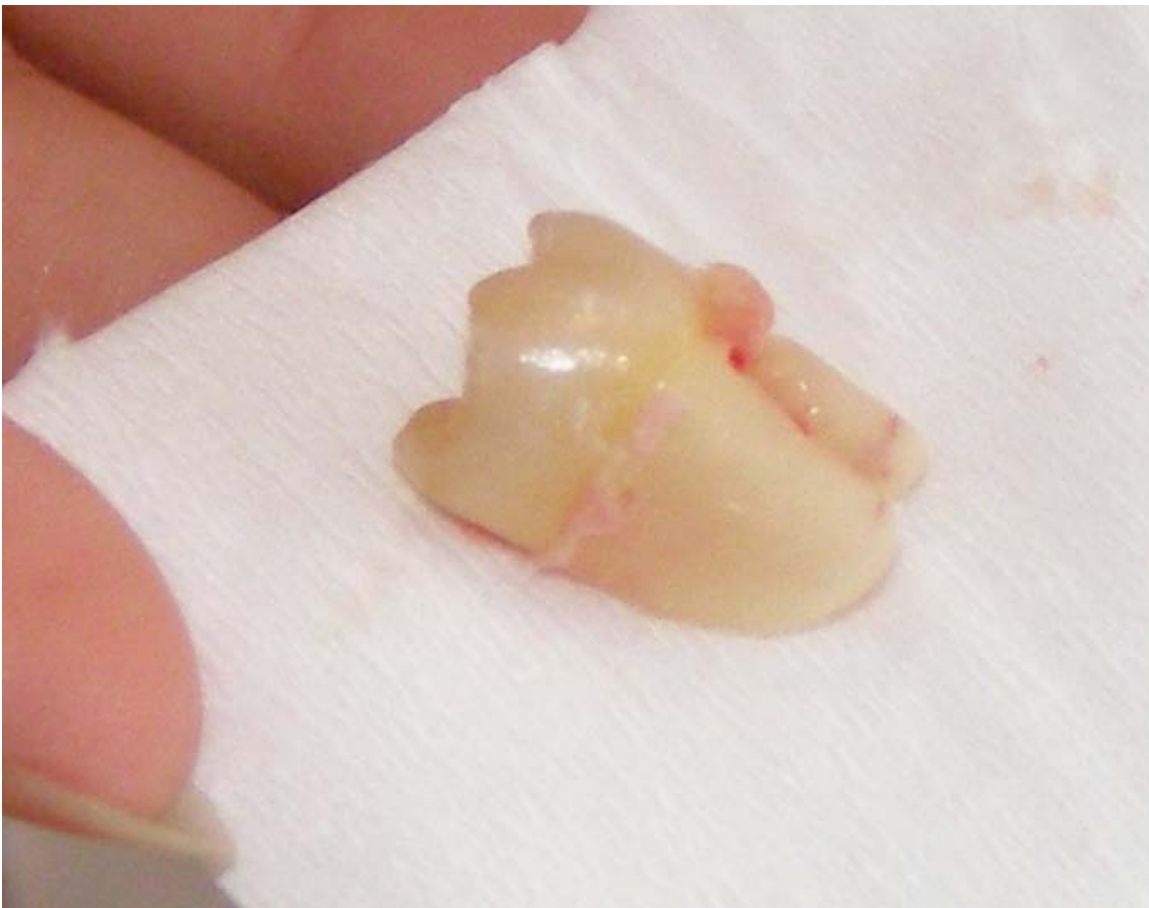Reasons for tooth extraction

The most common reason for extraction is tooth damage due to breakage or decay. There are additional reasons for tooth extraction:

- Severe tooth decay or infection. Despite the reduction in worldwide prevalence of dental caries, still it is the most common reason for extraction of (non-third molar) teeth with up to two thirds of extractions.
- Extra teeth which are blocking other teeth from coming in.
- Severe gum disease which may affect the supporting tissues and bone structures of teeth.
- In preparation for orthodontic treatment (braces)
- Teeth in the fracture line
- Fractured teeth

- Insufficient space for wisdom teeth (impacted third molars). Although many dentists remove asymptomatic impacted third molars, American as well as British Health Authorities recommended against this routine procedure, unless there are evidences for disease in the impacted tooth or the near environment. The American Public Health Association, for example, adopted a policy, *Opposition to Prophylactic Removal of Third Molars (Wisdom Teeth)* because of the large number of injuries resulting from unnecessary extractions.
- Receiving radiation to the head and neck may require extraction of teeth in the field of radiation.
- Deliberate, medically unnecessary, extraction as a particularly dreadful form of physical torture.

Types of extraction



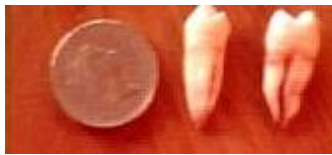An extracted 3rd molar that was horizontally impacted

Extractions are often categorized as "simple" or "surgical".

Simple extractions are performed on teeth that are visible in the mouth, usually under local anaesthetic, and require only the use of instruments to elevate and/or grasp the visible portion of the tooth. Typically the tooth is lifted using an elevator, and using

dental forceps, rocked back and forth until the Periodontal ligament has been sufficiently broken and the supporting alveolar bone has been adequately widened to make the tooth loose enough to remove. Typically, when teeth are removed with forceps, slow, steady pressure is applied with controlled force.

Surgical extractions involve the removal of teeth that cannot be easily accessed, either because they have broken under the gum line or because they have not erupted fully. Surgical extractions almost always require an incision. In a surgical extraction the doctor may elevate the soft tissues covering the tooth and bone and may also remove some of the overlying and/or surrounding jawbone tissue with a drill or osteotome. Frequently, the tooth may be split into multiple pieces to facilitate its removal. Surgical extractions are usually performed under a general anaesthetic.

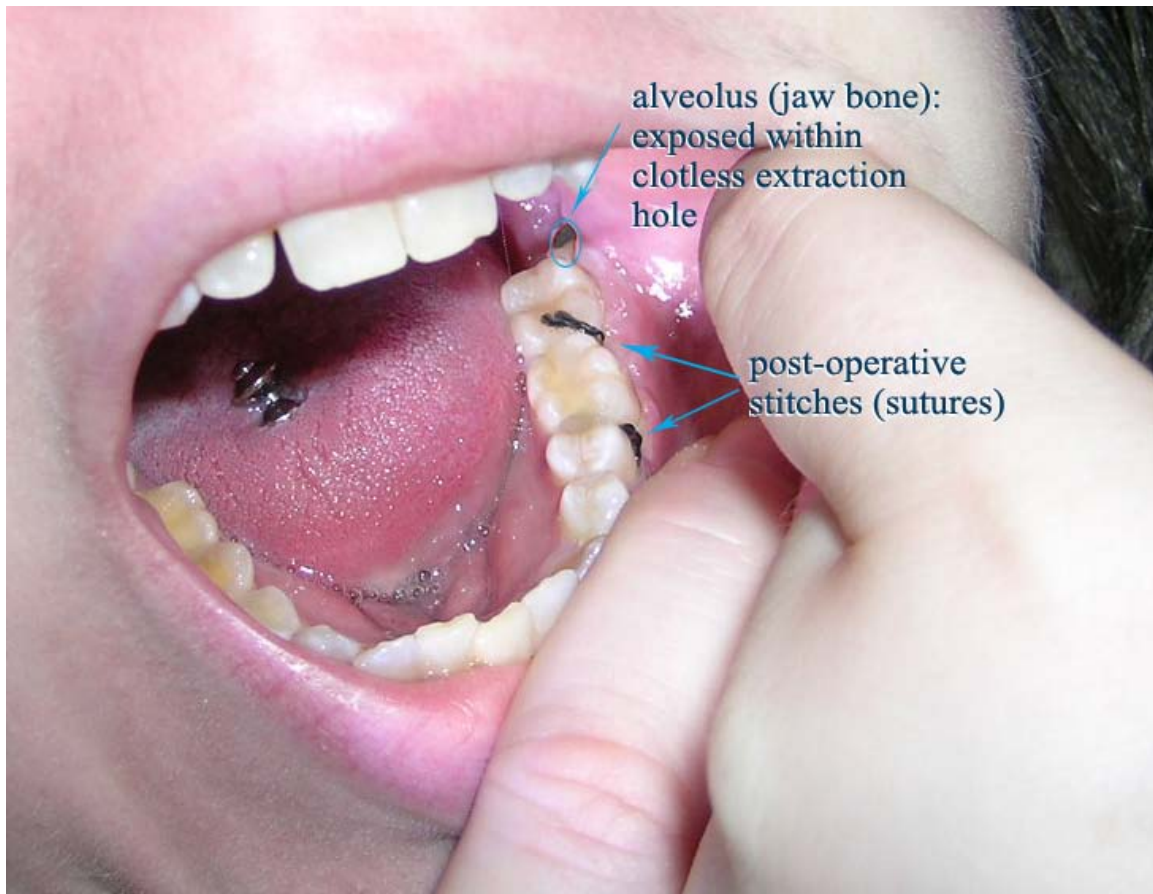


2 extracted teeth from a 14 year old male, compared against a £1 coin, which has a diameter of 22.50 millimetres (0.89 inches).

Post-extraction healing

Following extraction of a tooth, a blood clot forms in the socket, usually within an hour. Bleeding is common in this first hour, but its likelihood decreases quickly as time passes, and is unusual after 24 hours. The raw open wound overlying the dental socket takes about 1 week to heal. Thereafter, the socket will gradually fill in with soft gum tissue over a period of about one to two months. Final closure of the socket with bony remodeling can take six months or more.

Complications



Example of alveolar osteitis (dry socket) following lower third molar (wisdom tooth) extraction; six days post-surgery.



Example of post-operative swelling following third molar (wisdom teeth) extractions

1. Infection: although rare, it does occur. The dentist may opt to prescribe antibiotics pre- and/or post-operatively if they determine the patient to be at risk.
2. Prolonged bleeding: The dentist has a variety of means at their disposal to address bleeding; however, it is important to note that small amounts of blood mixed in the saliva after extractions are normal, even up to 72 hours after extraction. Usually, however, bleeding will almost completely stop within eight hours of the surgery, with only minuscule amounts of blood mixed with saliva coming from the wound. A gauze compress will significantly reduce bleeding over a period of a few hours.
3. Swelling: Often dictated by the amount of surgery performed to extract a tooth (e.g. surgical insult to the tissues both hard and soft surrounding a tooth). Generally, when a surgical flap must be elevated (i.e. and the periosteum covering the bone is thus injured), minor to moderate swelling will occur. A poorly-cut soft tissue flap, for instance, where the periosteum is torn off rather than cleanly elevated off the underlying bone, will often increase such swelling. Similarly, when bone must be removed using a drill, more swelling is likely to occur.
4. Sinus exposure and oral-antral communication: This can occur when extracting upper molars (and in some patients, upper premolars). The maxillary sinus sits right above the roots of maxillary molars and premolars. There is a bony floor of the sinus dividing the tooth socket from the sinus itself. This bone can range from thick to thin from tooth to tooth from patient to patient. In some cases it is absent and the root is in fact in the sinus. At other times, this bone may be removed with the tooth, or may be perforated during surgical extractions. The doctor typically

mentions this risk to patients, based on evaluation of radiographs showing the relationship of the tooth to the sinus. It is important to note that the sinus cavity is lined with a membrane called the Sniderian membrane, which may or may not be perforated. If this membrane is exposed after an extraction, but remains intact, a "sinus exposed" has occurred. If the membrane is perforated, however, it is a "sinus communication". These two conditions are treated differently. In the event of a sinus communication, the dentist may decide to let it heal on its own or may need to surgically obtain primary closure—depending on the size of the exposure as well as the likelihood of the patient to heal. In both cases, a resorbable material called "gelfoam" is typically placed in the extraction site to promote clotting and serve as a framework for granulation tissue to accumulate. Patients are typically provided with prescriptions for antibiotics that cover sinus bacterial flora, decongestants, as well as careful instructions to follow during the healing period.

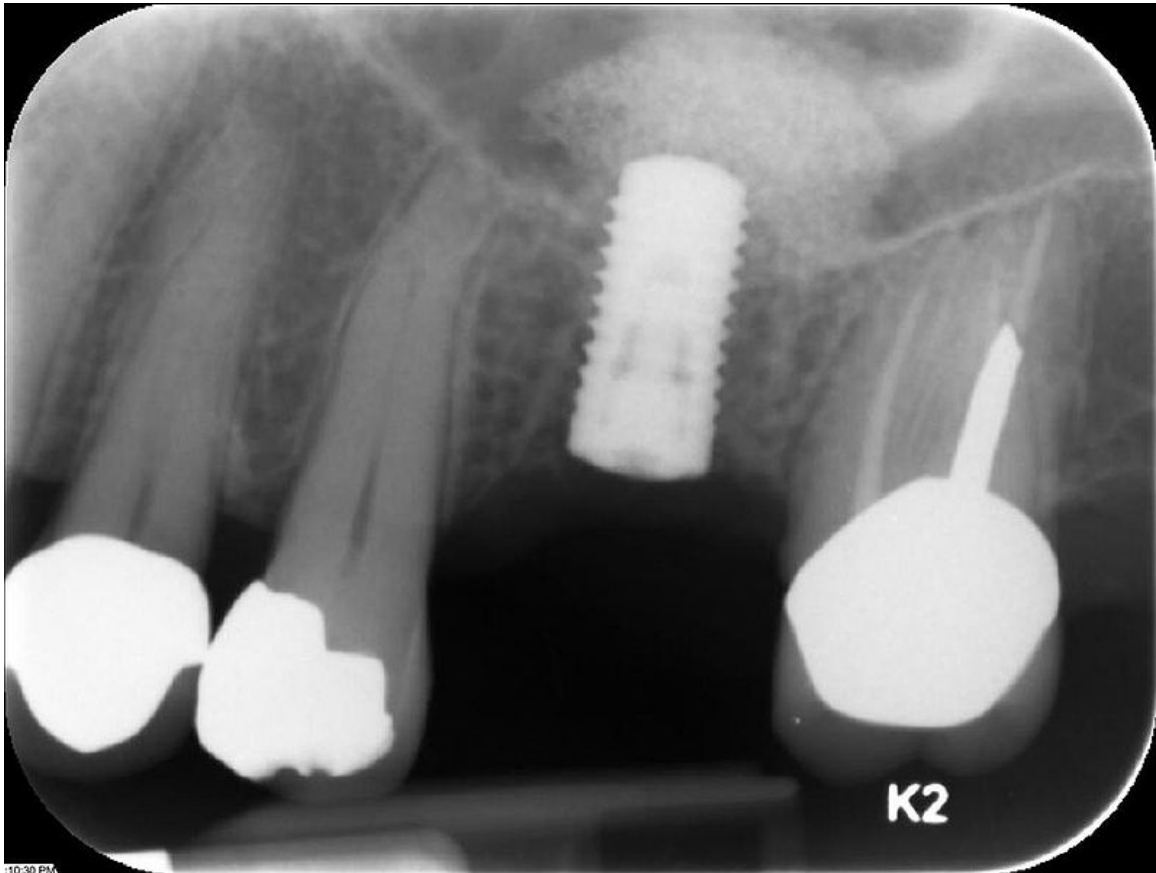
5. Nerve injury: This is primarily an issue with extraction of third molars, but can occur with the extraction of any tooth should the nerve be close to the surgical site. Two nerves are typically of concern, and are found in duplicate (one left and one right): 1. the inferior alveolar nerve, which enters the mandible at the mandibular foramen and exits the mandible at the sides of the chin from the mental foramen. This nerve supplies sensation to the lower teeth on the right or left half of the dental arch, as well as sense of touch to the right or left half of the chin and lower lip. 2. The lingual nerve (one right and one left), which branches off the mandibular branches of the trigeminal nerve and courses just inside the jaw bone, entering the tongue and supplying sense of touch and taste to the right and left half of the anterior 2/3 of the tongue as well as the lingual gingiva (i.e. the gums on the inside surface of the dental arch). Such injuries can occur while lifting teeth (typically the inferior alveolar), but are most commonly caused by inadvertent damage with a surgical drill. Such injuries are rare and are usually temporary, but depending on the type of injury (i.e. Seddon classification: neuropraxia, axonotmesis, & neurotmesis), can be prolonged or even permanent.
6. Displacement of tooth or part of tooth into the maxillary sinus (upper teeth only). In such cases, almost always the tooth or tooth fragment must be retrieved. In some cases, the sinus cavity can be irrigated with saline (antral lavage) and the tooth fragment may be brought back to the site of the opening through which it entered the sinus, and may be retrievable. At other times, a window must be made into the sinus in the Canine fossa--a procedure referred to as "Caldwell luc".
7. Dry socket (Alveolar osteitis) is a painful phenomenon that most commonly occurs a few days following the removal of mandibular (lower) wisdom teeth. It is commonly believed that it occurs because the blood clot within the healing tooth extraction site is disrupted. More likely, alveolar osteitis is a phenomenon of painful inflammation within the empty tooth socket because of the relatively poor blood supply to this area of the mandible (which explains why dry socket is usually not experienced in other parts of the jaws). Inflamed alveolar bone, unprotected and exposed to the oral environment after tooth extraction, can become packed with food and debris. A dry socket typically causes a sharp and sudden increase in pain commencing 2–5 days following the extraction of a mandibular molar, most commonly the third molar. This is often extremely

unpleasant for the patient; the only symptom of dry socket is pain, which often radiates up and down the head and neck. A dry socket is not an infection, and is not directly associated with swelling because it occurs entirely within bone — it is a phenomenon of inflammation within the bony lining of an empty tooth socket. Because dry socket is not an infection, the use of antibiotics has no effect on its rate of occurrence. The risk factor for alveolar osteitis can dramatically increase with smoking after an extraction.

8. Bone fragments Particularly when extraction of molars is involved, it is not uncommon for the bones which formerly supported the tooth to shift and in some cases to erupt through the gums, presenting protruding sharp edges which can irritate the tongue and cause discomfort. This is distinguished from a similar phenomena where broken fragments of bone or tooth left over from the extraction can also protrude through the gums. In the latter case, the fragments will usually work their way out on their own. In the former case, the protrusions can either be snapped off by the dentist, or eventually the exposed bone will erode away on its own.

Chapter 18

Dental Implant



A Straumann-brand root-form endosseous dental implant placed in the site of the maxillary left permanent first molar with bone graft used to elevate the sinus floor

A **dental implant** is a titanium "root" used in dentistry to support restorations that resemble a tooth or group of teeth to replace missing teeth.

Virtually all dental implants placed today are **root-form endosseous implants**, i.e., they appear similar to an actual tooth root (and thus possess a "root-form") and are placed *within* the bone (*end-* being the Greek prefix for "in" and *osseous* referring to "bone"). The bone of the jaw accepts and osseointegrates with the titanium post. The

osseointegration is the component of this implant procedure that makes it resemble the look and feel of a natural tooth.

Prior to the advent of root-form endosseous implants, most implants were either **blade endosseous implants**, in that the shape of the metal piece placed within the bone resembled a flat blade, or **subperiosteal implants**, in which a framework was constructed to lie upon and was attached with screws to the exposed bone of the jaws.

Dental implants can be used to support a number of dental prostheses, including crowns, implant-supported bridges or dentures. They can also be used as anchorage for orthodontic tooth movement. The use of dental implants permits unidirectional tooth movement without reciprocal action.

History

The Mayan civilization has been shown to have used the earliest known examples of endosseous implants (implants embedded into bone), dating back over 1,350 years before Per-Ingvar Brånemark started working with titanium. While excavating Mayan burial sites in Honduras in 1931, archaeologists found a fragment of mandible of Mayan origin, dating from about 600 AD. This mandible, which is considered to be that of a woman in her twenties, had three tooth-shaped pieces of shell placed into the sockets of three missing lower incisor teeth. For forty years the archaeological world considered that these shells were placed after death in a manner also observed in the ancient Egyptians. However, in 1970 a Brazilian dental academic, Professor Amadeo Bobbio studied the mandibular specimen and took a series of radiographs. He noted compact bone formation around two of the implants which led him to conclude that the implants were placed during life.

In the 1950s research was being conducted at Cambridge University in England to study blood flow in vivo. These workers devised a method of constructing a chamber of titanium which was then embedded into the soft tissue of the ears of rabbits. In 1952 the Swedish orthopaedic surgeon, P I Brånemark, was interested in studying bone healing and regeneration, and adopted the Cambridge designed 'rabbit ear chamber' for use in the rabbit femur. Following several months of study he attempted to retrieve these expensive chambers from the rabbits and found that he was unable to remove them. Per Brånemark observed that bone had grown into such close proximity with the titanium that it effectively adhered to the metal. Brånemark carried out many further studies into this phenomenon, using both animal and human subjects, which all confirmed this unique property of titanium.

Meanwhile an Italian medical doctor called Stefano Melchiade Tramonte, understood that titanium could be used for dental restorations and after designing a titanium screw to support his own dental prosthesis, started to use it on many patients in his clinic in 1959. The good results of his clinical studies on humans were published in 1966.

Although Brånemark had originally considered that the first work should centre on knee and hip surgery, he finally decided that the mouth was more accessible for continued clinical observations and the high rate of edentulism in the general population offered more subjects for widespread study. He termed the clinically observed adherence of bone with titanium as 'osseointegration'. In 1965 Brånemark, who was by then the Professor of Anatomy at Gothenburg University in Sweden, placed his first titanium dental implant into a human volunteer, a Swede named Gösta Larsson.

Contemporaneous independent research in the United States by Stevens and Alexander led to a 1969 US patent filing for titanium dental implants.

Over the next fourteen years Brånemark published many studies on the use of titanium in dental implantology until in 1978 he entered into a commercial partnership with the Swedish defense company, Bofors AB for the development and marketing of his dental implants. With Bofors (later to become Nobel Industries) as the parent company, Nobelpharma AB (later to be renamed Nobel Biocare) was founded in 1981 to focus on dental implantology. To the present day over 7 million Brånemark System implants have now been placed and hundreds of other companies produce dental implants. The majority of dental implants currently available are shaped like small screws, with either tapered or parallel sides. They can be placed at the same time as a tooth is removed by engaging with the bone of the socket wall and sometimes also with the bone beyond the tip of the socket. Current evidence suggests that implants placed straight into an extraction socket have comparable success rates to those placed into healed bone. The success rate and radiographic results of immediate restorations of dental implants placed in fresh extraction sockets (the temporary crowns placed at the same time) have been shown to be comparable to those obtained with delayed loading (the crowns placed weeks or months later) in carefully selected cases

Some current research in dental implantology is focusing on the use of ceramic materials such as zirconia (ZrO_2) in the manufacture of dental implants. Zirconia is the dioxide of zirconium, a metal close to titanium in the periodic table and with similar biocompatibility properties. Although generally the same shape as titanium implants, zirconia, which has been used successfully for orthopaedic surgery for a number of years, has the advantage of being more cosmetically aesthetic owing to its bright tooth-like colour. However, long-term clinical data is necessary before one-piece ZrO_2 implants can be recommended for daily practice.

Composition

A typical implant consists of a titanium screw (resembling a tooth root) with a roughened or smooth surface. The majority of dental implants are made out of commercially pure titanium, which is available in 4 grades depending upon the amount of carbon and iron contained. More recently grade 5 titanium has increased in use. Grade 5 titanium, Titanium 6AL-4V, (signifying the Titanium alloy containing 6% Aluminium and 4% Vanadium alloy) is believed to offer similar osseointegration levels as commercially pure titanium. Ti-6Al-4V alloy offers better tensile strength and fracture resistance. Today

most implants are still made out of commercially pure titanium (grades 1 to 4) but some implant systems (Endopore and NanoTite) are fabricated out of the Ti-6Al-4V alloy. Implant surfaces may be modified by plasma spraying, anodizing, etching or sandblasting to increase the surface area and the integration potential of the implant.

Training

There is no specialty recognized by the ADA for dental implants. Implant surgery may be performed as an outpatient under general anesthesia, oral conscious sedation, nitrous oxide sedation, intravenous sedation or under local anesthesia by trained and certified clinicians including general dentists, oral surgeons, periodontists, and prosthodontists.

The legal training requirements for dentists who carry out implant treatment differ from country to country. In the UK implant dentistry is considered by the General Dental Council to be a postgraduate sphere of dentistry. In other words it is not sufficiently covered during the teaching of the university dental degree course and dentists wishing to practice in dental implantology legally need to undergo additional formal postgraduate training. The General Dental Council has published strict guidelines on the training required for a dentist to be able to place dental implants in general dental practice. UK dentists need to complete a competency assessed postgraduate extended learning program before providing implant dentistry to patients.

The degree to which both graduate and post-graduate dentists receive training in the surgical placement of implants varies from country to country, but it seems likely that lack of formal training will lead to higher complication rates.

Surgical procedure

Surgical planning

Prior to commencement of surgery, careful and detailed planning is required to identify vital structures such as the inferior alveolar nerve or the sinus, as well as the shape and dimensions of the bone to properly orient the implants for the most predictable outcome. Two-dimensional radiographs, such as orthopantomographs or periapicals are often taken prior to the surgery. Sometimes, a CT scan will also be obtained. Specialized 3D CAD/CAM computer programs may be used to plan the case.

Whether CT-guided or manual, a 'stent' may sometimes be used to facilitate the placement of implants. A surgical stent is an acrylic wafer that fits over either the teeth, the bone surface or the mucosa (when all the teeth are missing) with pre-drilled holes to show the position and angle of the implants to be placed. The surgical stent may be produced using stereolithography following computerized planning of a case from the CT scan. CT guided surgery may double the cost compared to more commonly accepted approaches.

Basic procedure

In its most basic form the placement of an osseointegrated implant requires a preparation into the bone using either hand osteotomes or precision drills with highly regulated speed to prevent burning or pressure necrosis of the bone. After a variable amount of time to allow the bone to grow on to the surface of the implant (osseointegration), a crown or crowns can be placed on the implant. The amount of time required to place an implant will vary depending on the experience of the practitioner, the quality and quantity of the bone and the difficulty of the individual situation.

Detail procedure

At edentulous (without teeth) jaw sites, a pilot hole is bored into the recipient bone, taking care to avoid the vital structures (in particular the inferior alveolar nerve or IAN and the mental foramen within the mandible). Drilling into jawbone usually occurs in several separate steps. The pilot hole is expanded by using progressively wider drills (typically between three and seven successive drilling steps, depending on implant width and length). Care is taken not to damage the osteoblast or bone cells by overheating. A cooling saline or water spray keeps the temperature of the bone to below 47 degrees Celsius (approximately 117 degrees Fahrenheit). The implant screw can be self-tapping, and is screwed into place at a precise torque so as not to overload the surrounding bone (overloaded bone can die, a condition called osteonecrosis, which may lead to failure of the implant to fully integrate or bond with the jawbone). Typically in most implant systems, the osteotomy or drilled hole is about 1mm deeper than the implant being placed, due to the shape of the drill tip. Surgeons must take the added length into consideration when drilling in the vicinity of vital structures.

Surgical incisions

Traditionally, an incision is made over the crest of the site where the implant is to be placed. This is referred to as a 'flap'. Some systems allow for 'flapless' surgery where a piece of mucosa is punched-out from over the implant site. Proponents of 'flapless' surgery believe that it decreases recovery time while its detractors believe it increases complication rates because the edge of bone cannot be visualized. Because of these visualization problems flapless surgery is often carried out using a surgical guide constructed following computerized 3D planning of a pre-operative CT scan.

Healing time

The amount of time required for an implant to become osseointegrated is a hotly debated topic. Consequently the amount of time that practitioners allow the implant to heal before placing a restoration on it varies widely. In general, practitioners allow 2–6 months for healing but preliminary studies show that early loading of implant may not increase early or long term complications. If the implant is loaded too soon, it is possible that the implant may move which results in failure. The subsequent time to heal, possibly graft

and eventually place a new implant may take up to eighteen months. For this reason many are reluctant to push the envelope for healing.

One-stage, two-stage surgery

When an implant is placed either a 'healing abutment', which comes through the mucosa, is placed or a 'cover screw' which is flush with the surface of the dental implant is placed. When a cover screw is placed the mucosa covers the implant while it integrates then a second surgery is completed to place the healing abutment.

Two-stage surgery is sometimes chosen when a concurrent bone graft is placed or surgery on the mucosa may be required for esthetic reasons. Some implants are one piece so that no healing abutment is required.

In carefully selected cases, patients can be implanted and restored in a single surgery, in a procedure labeled "Immediate Loading". In such cases a provisional prosthetic tooth or crown is shaped to avoid the force of the bite transferring to the implant while it integrates with the bone.

Surgical timing

There are different approaches to place dental implants after tooth extraction. The approaches are:

1. Immediate post-extraction implant placement.
2. Delayed immediate post-extraction implant placement (2 weeks to 3 months after extraction).
3. Late implantation (3 months or more after tooth extraction).

According to the timing of loading of dental implants, the procedure of loading could be classified into:

1. Immediate loading procedure.
2. Early loading (1 week to 12 weeks).
3. Delayed loading (over 3 months)

Immediate placement

An increasingly common strategy to preserve bone and reduce treatment times includes the placement of a dental implant into a recent extraction site. In addition, immediate loading is becoming more common as success rates for this procedure are now acceptable. This can cut months off the treatment time and in some cases a prosthetic tooth can be attached to the implants at the same time as the surgery to place the dental implants.

Most data suggests that when placed into single rooted tooth sites with healthy bone and mucosa around them, the success rates are comparable to that of delayed procedures with no additional complications.

Use of CT scanning

When computed tomography, also called cone beam computed tomography or CBCT (3D X-ray imaging) is used preoperatively to accurately pinpoint vital structures including the inferior alveolar canal, the mental foramen, and the maxillary sinus, the chances of complications might be reduced as is chairtime and number of visits. Cone beam CT scanning, when compared to traditional medical CT scanning, utilizes less than 2% of the radiation, provides more accuracy in the area of interest, and is safer for the patient. CBCT allows the surgeon to create a surgical guide, which allows the surgeon to accurately angle the implant into the ideal space.

Complementary procedures

Sinus lifting is a common surgical intervention. A dentist or specialist with proper training such as an oral surgeon, periodontist, general dentist, or prosthodontist, thickens the inadequate part of atrophic maxilla towards the sinus with the help of bone transplantation or bone expletive substance. This results in more volume for a better quality bone site for the implantation. Prudent clinicians who wish to avoid placement of implants into the sinus cavity pre-plan sinus lift surgery using the CBCT X-ray, as in the case of posterior mandibular implants discussed earlier.

Bone grafting will be necessary in cases where there is a lack of adequate maxillary or mandibular bone in terms of front to back (lip to tongue) depth or thickness; top to bottom height; and left to right width. Sufficient bone is needed in three dimensions to securely integrate with the root-like implant. Improved bone height—which is very difficult to achieve—is particularly important to assure ample anchorage of the implant's root-like shape because it has to support the mechanical stress of chewing, just like a natural tooth.

Typically, implantologists try to place implants at least as deeply into bone as the crown or tooth will be above the bone. This is called a 1:1 crown to root ratio. This ratio establishes the target for bone grafting in most cases. If 1:1 or more cannot be achieved, the patient is usually advised that only a short implant can be placed and to not expect a long period of usability.

A wide range of grafting materials and substances may be used during the process of bone grafting / bone replacement. They include the patient's own bone (autograft), which may be harvested from the hip (iliac crest) or from spare jawbone; processed bone from cadavers (allograft); bovine bone or coral (xenograft); or artificially produced bone-like substances (calcium sulfate with names like Regeneform; and hydroxyapatite or HA, which is the primary form of calcium found in bone). The HA is effective as a substrate for osteoblasts to grow on. Some implants are coated with HA for this reason, although

the bone forming properties of many of these substances is a hotly debated topic in bone research groups. Alternatively the bone intended to support the implant can be split and widened with the implant placed between the two halves like a sandwich. This is referred to as a 'ridge split' procedure.

Bone graft surgery has its own standard of care. In a typical procedure, the clinician creates a large flap of the gingiva or gum to fully expose the jawbone at the graft site, performs one or several types of block and onlay grafts in and on existing bone, then installs a membrane designed to repel unwanted infection-causing microbiota found in the oral cavity. Then the mucosa is carefully sutured over the site. Together with a course of systemic antibiotics and topical antibacterial mouth rinses, the graft site is allowed to heal (several months).

The clinician typically takes a new radiograph to confirm graft success in width and height, and assumes that positive signs in these two dimensions safely predict success in the third dimension; depth. Where more precision is needed, usually when mandibular implants are being planned, a 3D or cone beam radiograph may be called for at this point to enable accurate measurement of bone and location of nerves and vital structures for proper treatment planning. The same radiographic data set can be employed for the preparation of computer-designed placement guides.

Correctly performed, a bone graft produces live vascular bone which is very much like natural jawbone and is therefore suitable as a foundation for implants.

Considerations



Chrome-cobalt disc with bridges and crowns for dental implants manufactured using WorkNC Dental CAD/CAM

For dental implant procedure to work, there must be enough bone in the jaw, and the bone has to be strong enough to hold and support the implant. If there is not enough bone, more may need to be added with a bone graft procedure discussed earlier. Sometimes, this procedure is called bone augmentation. In addition, natural teeth and supporting tissues near where the implant will be placed must be in good health.

In all cases careful consideration must be given to the final functional aspects of the restoration, such as assessing the forces which will be placed on the implant. Implant loading from chewing and parafunction (abnormal grinding or clenching habits) can exceed the biomechanic tolerance of the implant bone interface and/or the titanium material itself, causing failure. This can be failure of the implant itself (fracture) or bone loss, a "melting" or resorption of the surrounding bone.

The dentist must first determine what type of prosthesis will be fabricated. Only then can the specific implant requirements including number, length, diameter, and thread pattern be determined. In other words, the case must be reverse engineered by the restoring dentist prior to the surgery. If bone volume or density is inadequate, a bone graft procedure must be considered first. The restoring dentist may consult with the oral surgeon, periodontist, endodontist, or another trained general dentist to co-treat the patient. Usually, physical models or impressions of the patient's jawbones and teeth are made by the restorative dentist at the implant surgeons request, and are used as physical aids to treatment planning. If not supplied, the implant surgeon makes his own or relies upon advanced computer-assisted tomography or a cone beam CT scan to achieve the proper treatment plan.

Computer simulation software based on CT scan data allows virtual implant surgical placement based on a barium impregnated prototype of the final prosthesis. This predicts vital anatomy, bone quality, implant characteristics, the need for bone grafting, and maximizing the implant bone surface area for the treatment case creating a high level of predictability. Computer CAD/CAM milled or stereolithography based drill guides can be developed for the implant surgeon to facilitate proper implant placement based on the final prosthesis' occlusion and aesthetics.

Treatment planning software can also be used to demonstrate "try-ins" to the patient on a computer screen. When options have been fully discussed between patient and surgeon, the same software can be used to produce precision drill guides. Specialized software applications such as 'SimPlant' (simulated implant) or 'NobelGuide' use the digital data from a patient's CBCT to build a treatment plan. A data set is then produced and sent to a lab for production of a precision in-mouth drilling guide.

Success rates

Dental implant success is related to operator skill, quality and quantity of the bone available at the site, and the patient's oral hygiene. The consensus is that implants carry a success rate of around 95%

One of the most important factors that determine implant success is the achievement and maintenance of implant stability. The stability is presented as an ISQ (Implant Stability Quotient) value. Other contributing factors to the success of dental implant placement, as with most surgical procedures, include the patient's overall general health and compliance with post-surgical care.

Failure

Failure of a dental implant is often related to failure to osseointegrate correctly. A dental implant is considered to be a failure if it is lost, mobile or shows peri-implant (around the implant) bone loss of greater than 1.0 mm in the first year and greater than 0.2mm a year after.

Dental implants are not susceptible to dental caries but they can develop a condition called peri-implantitis. This is an inflammatory condition of the mucosa and/or bone around the implant which may result in bone loss and eventual loss of the implant. The condition is usually, but not always, associated with a chronic infection. Peri-implantitis is more likely to occur in heavy smokers, patients with diabetes, patients with poor oral hygiene and cases where the mucosa around the implant is thin.

Currently there is no universal agreement on the best treatment for peri-implantitis. The condition and its causes is still poorly understood.

Risk of failure is increased in smokers. For this reason implants are frequently placed only after a patient has stopped smoking as the treatment is very expensive. More rarely, an implant may fail because of poor positioning at the time of surgery, or may be overloaded initially causing failure to integrate. If smoking and positioning problems exist prior to implant surgery, clinicians often advise patients that a bridge or partial denture rather than an implant may be a better solution.

Failure may also occur independently of the causes outlined above. Implants like any other object suffers from wear and tear. If the implants in question are replacing commonly used teeth, then these may suffer from wear and tear and after years may crack and break up, although this is a very rare occurrence. The only way to minimize the risk of this happening is to visit your dentist for regular reviews.

In the majority of cases where an implant fails to integrate with the bone and is rejected by the body the cause is unknown. This may occur in around 5% of cases. To this day we still do not know why bone will integrate with titanium dental implants and why it does not reject the material as a 'foreign body'. Many theories have been postulated over the last five decades. A recent theory argues that rather than being an active biological tissue response, the integration of bone with an implant is the lack of a negative tissue response. In other word for unknown reasons the usual response of the body to reject foreign objects implanted into it does not function correctly with titanium implants. It has further been postulated that an implant rejection occurs in patients whose bone tissues actually

react as they naturally should with the 'foreign body' and reject the implant in the same manner that would occur with most other implanted materials.

Contraindications

There are few absolute contraindications to implant dentistry. However, there are some systemic, behavioral and anatomic considerations that should be assessed.

Particularly for mandibular (lower jaw) implants, in the vicinity of the mental foramen (MF), there must be sufficient alveolar bone above the mandibular canal also called the inferior alveolar canal or IAC (which acts as the conduit for the neurovascular bundle carrying the inferior alveolar nerve or IAN).

Failure to precisely locate the IAN and MF invites surgical insult by the drills and the implant itself. Such insult may cause irreparable damage to the nerve, often felt as a paresthesia (numbness) or dysesthesia (painful numbness) of the gum, lip and chin. This condition may persist for life and may be accompanied by unconscious drooling.

Uncontrolled type II diabetes is a significant relative contraindication as healing following any type of surgical procedure is delayed due to poor peripheral blood circulation. Anatomic considerations include the volume and height of bone available. Often an ancillary procedure known as a block graft or sinus augmentation are needed to provide enough bone for successful implant placement.

There is new information about intravenous and oral bisphosphonates (taken for certain forms of breast cancer and osteoporosis, respectively) which may put patients at a higher risk of developing a delayed healing syndrome called osteonecrosis. Implants are contraindicated for some patients who take intravenous bisphosphonates.

The many millions of patients who take an oral bisphosphonate (such as Actonel, Fosamax and Boniva) may sometimes be advised to stop the administration prior to implant surgery, then resume several months later. However, current evidence suggests that this protocol may not be necessary. As of January, 2008, an oral bisphosphonate study reported in the February 2008 *Journal of Oral and Maxillofacial Surgery*, reviewing 115 cases that included 468 implants, concluded "There is no evidence of bisphosphonate-associated osteonecrosis of the jaw in any of the patients evaluated in the clinic and those contacted by phone or e-mail reported no symptoms."

The American Dental Association had addressed bisphosphonates in an article entitled "Bisphosphonate medications and your oral health," In an Overview, the ADA stated "The risk of developing BON [bisphosphonate-associated osteonecrosis of the jaw] in patients on oral bisphosphonate therapy appears to be very low...". The ADA Council on Scientific Affairs also employed a panel of experts who issued recommendations [for clinicians] for treatment of patients on oral bisphosphonates, published in June, 2006. The overview may be read online at ada.org but it has now been superseded by a huge study—encompassing over 700,000 cases—entitled "Bisphosphonate Use and the Risk of

Adverse Jaw Outcomes." Like the 2008 JOMS study, the ADA study exonerates oral bisphosphonates as a contraindication to dental implants.

Bruxism (tooth clenching or grinding) is another consideration which may reduce the prognosis for treatment. The forces generated during bruxism are particularly detrimental to implants while bone is healing; micromovements in the implant positioning are associated with increased rates of implant failure. Bruxism continues to pose a threat to implants throughout the life of the recipient. Natural teeth contain a periodontal ligament allowing each tooth to move and absorb shock in response to vertical and horizontal forces. Once replaced by dental implants, this ligament is lost and teeth are immovably anchored directly into the jaw bone. This problem can be minimized by wearing a custom made mouthguard (such an NTI appliance) at night.

Postoperatively, after implants have been placed, there are physical contraindications that prompt rapid action by the implantology team. Excessive or severe pain lasting more than three days is a warning sign, as is excessive bleeding. Constant numbness of the gingiva (gum), lip and chin—usually noticed after surgical anesthesia wears off—is another warning sign. In the latter case, which may be accompanied by severe constant pain, the standard of care calls for diagnosis to determine if the surgical procedure insulted the IAN. A 3D cone beam X-ray provides the necessary data, but even before this step a prudent implantologist may back out or completely remove an implant in an effort to restore nerve function because delay is usually ineffective. Depending upon the evidence visible with a 3D X-ray, patients may be referred to a specialist in nerve repair. In all cases, speed in diagnosis and treatment are necessary.

Market

In the United States and the United Kingdom, there is no exclusive specialty in 'implantology'.

Any practitioner who carries out implant treatment, whether in the surgical insertion or the final provision of the prosthesis, must be adequately trained. Legal training requirements differ between countries.

In 2008, in the UK the General Dental Council (GDC) laid down strict training requirements for dentists involved in dental implantology. Any dentist in the UK who wishes to train in the field of dental implantology must take part in an extended learning program which covers a detailed theory syllabus, as approved by the GDC, in addition to formal supervised surgical training and mentoring. Dentists must not take part in implant dentistry in the UK until they have been approved by the training provider as having passed a formal competency assessment. Failure to comply with the GDC regulations may result in a dentist being removed from the Dental Register and hence losing the right to practice dentistry in the UK.